

Recurrent Marijuana Induced Myocarditis: A Case Report

Sabina Kumar^{1,*}, John Carvalho¹, Chukwuemeka Umeh¹, Pranav Barve¹
Jose Penaherrera¹, Ratan Tiwari¹, Shivang Shah^{2,3}

¹Department of Internal Medicine, Hemet Global Medical Center, Hemet, California, USA

²Division of Cardiology, Loma Linda University School of Medicine, Loma Linda, California, USA

³Division of Cardiology, University of California Riverside School of Medicine, Riverside, California, USA

*Corresponding author: Sabina.Kumar@kpc.health

Received May 17, 2021; Revised June 21, 2021; Accepted July 01, 2021

Abstract Thirty-Three states in the US have passed laws to legalize marijuana usage, increasing its prevalence by 50% within the last year. Though society generally regards cannabis as safe, the exponential increase in users can evince dangerous side effects in patients presenting to physicians, such as the case presented below. A 37-year-old female presented to the ED with chest pain and an initial troponin of 24 that peaked at 29. The coronary arteries were found to be angiographically normal. She was discharged without any definitive diagnosis. Now 38, she again presented with complaints of crushing, substernal chest pain radiating down her left arm, unrelieved by nitro. Since the onset of pain, she progressively developed shortness of breath, nausea, diaphoresis, and anxiety, stating that she felt like she “was going to die.” Her presentation and impending sense of doom were ominous harbingers for a myocardial infarction; concerns that were validated with an initial troponin of 11.4. EKG showed normal sinus rhythm with nonspecific ST changes. CT Angiogram showed no evidence of pulmonary thrombo-embolism or dissection. Significant CAD leading to this extent of troponin elevation was not suspected as the patient had a normal angiogram a year prior. Stress-Induced Cardiomyopathy was unlikely based on the unremarkable echocardiogram findings. Coronary-Thrombus was considered, however, the hypercoagulable workup was negative along with lack of coronary thrombus on prior angiogram. Under these circumstances, the only explanation for the extent of troponin elevation was myocarditis. Viral infections are the most common cause of myocarditis, however the patient denied any associated symptoms. After ruling out viral etiologies, we subsequently evaluated and eliminated rheumatological disorders and medication-induced myocarditis. The patient’s history revealed that she led a healthy lifestyle, but had struggled with chronic back pain, which led to her cannabis use. By the time of her admission, she smoked up to 1.5 grams of cannabis a day, and stated that chest pain began immediately following smoking cannabis. Her previous episodes also correlated with her cannabis usage. Given the strong correlation of the patient’s symptoms with cannabis use, we theorized her cardiac stress was resultant from it, and recommended that she discontinue its use. To date there have been four reported cases of cannabis-induced myocarditis, making this a fifth case. Of note, the contaminants of marijuana may be variable and include substances like aluminum from soil or pesticides in grass that could traverse the marijuana plant. Inhaling such components has been correlated with an upregulation of cannabinoid receptors in platelets, vascular smooth muscle, and endothelium. CB1R activation has been observed to induce oxidative stress, inflammation, and fibrosis of the cardiomyocyte. With increased cannabis use, it is imperative that we document adverse events to definitively connect its use to cardiac damage.

Keywords: *marijuana, myocarditis, cardiomyopathy*

Cite This Article: Sabina Kumar, John Carvalho, Chukwuemeka Umeh, Jose Penaherrera, Ratan Tiwari, and Shivang Shah, “Recurrent Marijuana Induced Myocarditis: A Case Report.” *American Journal of Medical Case Reports*, vol. 9, no. 10 (2021): 519-521. doi: 10.12691/ajmcr-9-10-11.

1. Introduction

Marijuana is the most used recreational drug in the United States (US), and the number of users has increased over the years [1,2]. According to the National Survey on Drug Use and Health 2019, the percentage of people aged 12 or older who used marijuana in the past year increased from 11.0 percent (or 25.8 million people) in 2002 to 17.5

percent (or 48.2 million people) in 2019 [2]. Despite studies that have shown that marijuana may be helpful in treating neuropathic pain [1,3], marijuana use has been associated with deleterious consequences, including adverse effects on the brain, lungs, and heart [1]. Cases of marijuana associated cardiac arrhythmias, myocardial infarction, coronary dissection, and myopericarditis have been previously reported [4,5,6,7]. We report here a rare case of recurrent marijuana induced myocarditis in a young female patient.

2. Case Report

A 37-year-old female originally presented to the emergency department with crushing substernal chest pain which resolved after receiving nitroglycerin in the field. The vital signs and physical examination on presentation were grossly unremarkable. The labs were also unremarkable apart from an initial troponin of 24, which then peaked at 29. Her urine drug screen was positive for cannabinoids. The electrocardiogram (EKG) showed normal sinus rhythm with nonspecific ST changes. An echocardiogram showed grossly normal left ventricular systolic function with no definite wall motion abnormality and an ejection fraction of 55 to 60 percent. The coronary arteries were found to be angiographically normal (Figure 1). She was discharged without any definitive diagnosis. Now, at the age of 38, she again presented with complaints of crushing, substernal chest pain radiating down her left arm, this time unrelieved by nitro. Since the onset of her pain, she progressively developed shortness of breath, nausea, diaphoresis, and anxiety, stating that she felt like she “was going to die.” Her presentation and impending sense of doom were ominous harbingers for a myocardial infarction; concerns that were validated with an initial troponin of 11.4. EKG showed normal sinus rhythm with

nonspecific ST changes. CT angiogram showed no evidence of pulmonary thrombo-embolism or dissection. Significant coronary artery disease leading to this extent of troponin elevation was not suspected, as the patient had a normal angiogram a year prior. Stress-Induced Cardiomyopathy was unlikely based on the unremarkable echocardiogram findings. Coronary-thrombus was considered, however, the hypercoagulable workup was negative along with lack of coronary thrombus on prior angiogram. Under these circumstances, the only explanation for the extent of troponin elevation was myocarditis. Viral infections are the most common cause of myocarditis, however the patient denied any associated symptoms. After ruling out viral etiologies, we subsequently evaluated and eliminated rheumatological disorders and medication-induced myocarditis. The patient’s history revealed that she led a healthy lifestyle, but had struggled with chronic back pain, which led to her cannabis use. By the time of her admission, she smoked up to 1.5 grams of cannabis a day, and stated that chest pain began immediately following smoking cannabis. Her previous episodes also correlated with her cannabis usage. Given the strong correlation of the patient’s symptoms with cannabis use, we theorized her cardiac stress was resultant from it, and recommended that she discontinue its use.

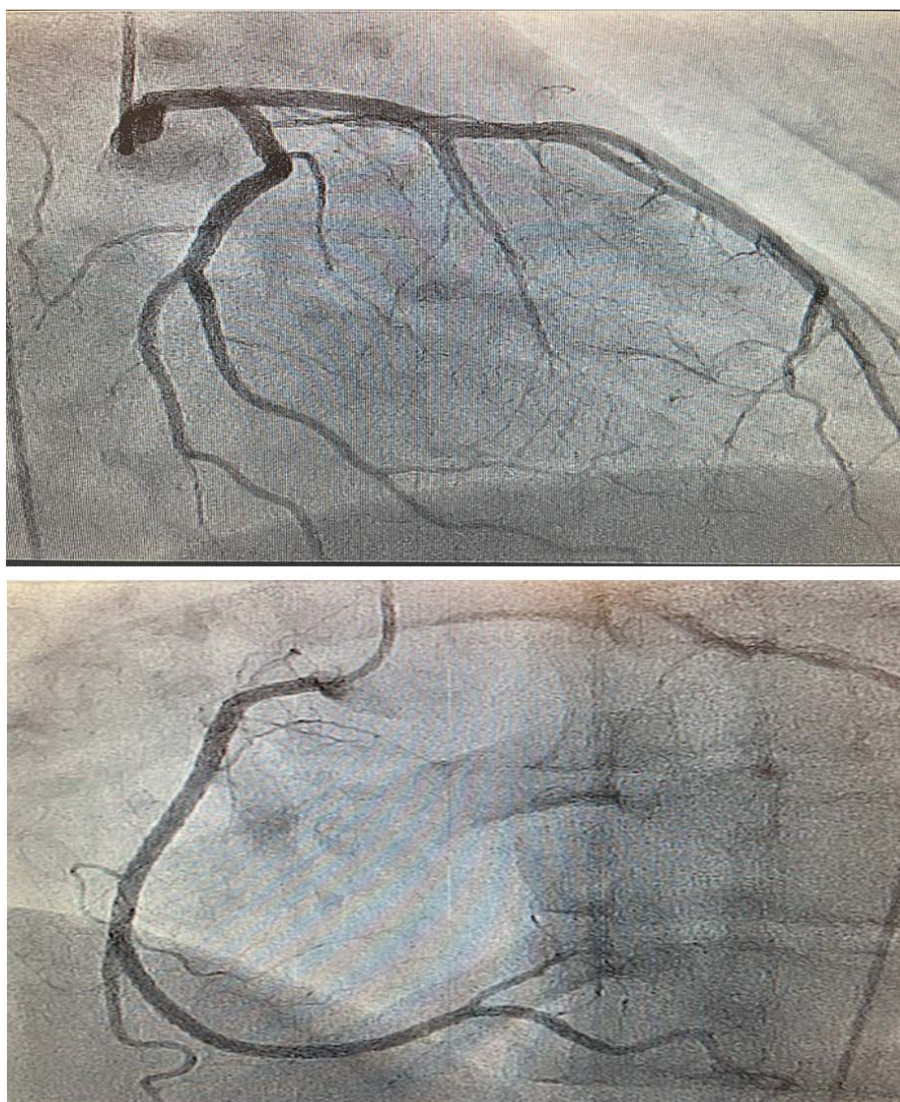


Figure 1. Coronary angiogram showing normal coronary arteries

3. Discussion

Myocarditis is an uncommon disease that presents with a wide range of symptoms and is an underdiagnosed cause of acute heart failure, sudden death, and chronic dilated cardiomyopathy [8,9]. Patients with myocarditis may present with chest pain, dyspnea, palpitations, fatigue, or syncope. Chest pain in acute myocarditis may mimic acute coronary syndrome, often with globally preserved left ventricular function, and patients may present with electrocardiographic changes, including ST-segment elevation [8,9]. Although viral infection is the most common cause of myocarditis, other infectious pathogens including bacteria, fungi, and protozoans, as well as toxins, drug reactions, autoimmune diseases, and sarcoidosis cause myocarditis [8,9].

Myocarditis is definitely diagnosed by histology irrespective of clinical presentation [9]. However, probable myocarditis can be diagnosed in a patient presenting with one of four clinical features consistent with acute myocarditis (acute heart failure, chest pain, presyncope or syncope, or myopericarditis), in addition to a recent trigger for myocarditis, and one of the following: (1) an unexplained rise in troponin; (2) electrocardiographic changes suggestive of acute myocardial injury; or (3) abnormal cardiac function on echocardiogram or cardiac MRI [9]. For our patient, her recurrent acute chest pain and unexplained rise in troponin were associated with a recent use of marijuana.

Marijuana induced myocarditis is rare and the exact mechanism through which marijuana causes myocarditis is unclear [10,11]. One possible explanation is that contaminants in street marijuana such as fungi, bacteria, heavy metals, and pesticides, are responsible [10,11]. Further research is needed to explain the cause of marijuana induced myocarditis; however, this is challenging in view of the rarity of the condition. Treatment for marijuana induced myocarditis includes stopping the use of marijuana and treating any associated complication from the disease such as heart failure.

In conclusion, we report a rare case of recurrent marijuana induced myocarditis. The fact that our patient

was only diagnosed at her second presentation in the hospital with chest pain underscores the importance of physicians and cardiologists being aware of this rare and probably underdiagnosed cause of myocarditis.

References

- [1] CDC. Marijuana: How Can It Affect Your Health? 2018. Available from: <https://www.cdc.gov/marijuana/health-effects.html>.
- [2] Substance Abuse and Mental Health Services Administration. (2020). Key substance use and mental health indicators in the United States: Results from the 2019 National Survey on Drug Use and Health (HHS Publication No. PEP20-07-01-001, NSDUH Series H-55). Rockville, MD: Center for Behavioral Health Statistics and Quality, Substance Abuse and Mental Health Services Administration. Retrieved from <https://www.samhsa.gov/data>.
- [3] National Academies of Sciences E, and Medicine. (2017). The health effects of cannabis and cannabinoids: Current state of evidence and recommendations for researchexternal icon. Washington, D.C.
- [4] Kariyanna PT, Wengrofsky P, Jayarangaiah A, Haseeb S, Salciccioli L, Hegde S, Marmur JD, Soliman Y, Al-Bayati S, McFarlane SI. Marijuana and cardiac arrhythmias: A scoping study. *International journal of clinical research & trials*. 2019; 4(1).
- [5] Kariyanna PT, Chandrakumar HP, Feit A, McFarlane IM. Marijuana-induced coronary vasospasm and myocardial infarction: a case report and review of literature. *American journal of medical case reports*. 2020; 8(7): 216.
- [6] Kariyanna PT, Chandrakumar HP, Chowdhury YS, Jayarangaiah A, Das S, Jayarangaiah A, Salifu MO, McFarlane IM. Marijuana and Coronary Dissection: A Case Report and Review of Literature. *American journal of medical case reports*. 2021; 9(3): 172.
- [7] Rodríguez-Castro CE, Alkhateeb H, Elfar A, Saifuddin F, Abbas A, Siddiqui T. Recurrent myopericarditis as a complication of marijuana use. *The American journal of case reports*. 2014; 15: 60.
- [8] Blauwet LA, Cooper LT. Myocarditis. *Progress in cardiovascular diseases*. 2010 Jan 1; 52(4): 274-88.
- [9] Sagar S, Liu PP, Cooper Jr LT. Myocarditis. *The Lancet*. 2012 Feb 25; 379(9817): 738-47.
- [10] Tournebize J, Gibaja V, Puskarczyk E, Popovic B, Kahn JP. Myocarditis and cannabis: An unusual association. *Toxicologie Analytique et Clinique*. 2016 Sep 1; 28(3): 236.
- [11] Kariyanna PT, Jayarangaiah A, Singh N, Song T, Soroka S, Amarnani A, Ray J, McFarlane SI. Marijuana induced myocarditis: a new entity of toxic myocarditis. *American journal of medical case reports*. 2018; 6(9): 169.

