

Benign Fibrous Histiocytoma in a Child -A Case Report

Diaconescu Smaranda^{1,2}, Moisa Stefana^{1,2,*}, Mihaila Doina³, Plamadeala Petru³,
Ciubara Anamaria¹, Miron Ingrid^{1,2}

¹“Gr. T. Popa” University of Medicine and Pharmacy, Iasi, Romania

²Pediatrics, “St. Mary” Children’s Emergency Hospital, Iasi, Romania

³Pathology Department, “St. Mary” Children’s Emergency Hospital, Iasi, Romania

*Corresponding author: stephaniemed@yahoo.com

Abstract Benign fibrous histiocytoma is a tumor mostly dealt with in ambulatory settings due to its often paucisymptomatic presentation and to the fact that clinicians may not always recognize its potential for metastasis and recurrence. We present the case of a 4 years old male child operated for a tumor with very atypical localization (adjacent to the sixth cervical vertebra), mobile on the underlying and overlying structures, with no other abnormalities of the clinical examination. No biochemical anomalies were present, except for a mild iron deficiency. No predisposing factors (trauma, insect bites or vaccines) were noted during anamnesis. Postoperative evolution was favorable, with no recurrences over a 3 year follow-up period.

Keywords: *histiocytoma, benign, fibrous, children*

Cite This Article: Diaconescu Smaranda, Moisa Stefana, Mihaila Doina, Plamadeala Petru, Ciubara Anamaria, and Miron Ingrid, “Benign Fibrous Histiocytoma in a Child -A Case Report.” *American Journal of Medical Case Reports*, vol. 4, no. 1 (2016): 19-21. doi: 10.12691/ajmcr-4-1-6.

1. Introduction

Benign fibrous histiocytoma is a mesenchymal tumor that usually has a benign behavior and rarely leads to metastasis. The tumor is usually asymptomatic or may cause localized pain and swallowing. Most cases have a favorable prognosis, but certain types have a tendency for recurrence or metastasis in the lungs, lymph nodes, soft tissues or liver [1,2].

The tumor is rare and commonly affects adults between the ages of 20 and 50 years old. The differential diagnose should be performed with non-ossifying fibroma, dermatofibrosarcoma protuberans, leiomyosarcoma, melanocytic or vascular tumors, angiomatoid malignant fibrous histiocytoma, Spitz nevus, xanthoma or atrophic fibrous histiocytoma [3,4].

2. Material and Methods

Data was collected from clinical records, operative protocol and pathology reports of the patient. Parents signed an informed consent that allows the usage of patient’s data for research and teaching purposes. The references were selected after performing a literature review conducted in Medline using the keywords “benign fibrous histiocytoma” combined with “children”.

3. Case Report

A 4 year old male child was admitted to the Pediatric Surgery Unit of “St. Mary” Children’s Emergency Hospital

for preoperative investigation and tumor excision. He had been previously diagnosed with a tumor adjacent to the sixth cervical vertebral that had not previously been operated on.

Physical examination: 4 years old male patient with a normal weight and height for his age, in no apparent distress, with no fever (temperature 98,3 degrees), with normally colored skin and mucosa; extremities were warm, with no cyanosis or clubbing; normal auscultation of the lungs, and normal respiratory rate- 12/min; no pathological heart sounds or murmurs, blood pressure 99/68 mm Hg with no orthostatic changes; the abdomen was soft and non-tender, the liver, spleen and kidneys had normal size. Urine and stool were normal. No neurologic focal deficit was present, cranial nerves were normal, no balance deficits were noticed. The tumor was mobile, not fixed to the underlying vertebra, covered by normal skin. Laboratory data only showed mild iron deficiency (7 $\mu\text{mol/L}$, with a normal value of 13-31 $\mu\text{mol/L}$).

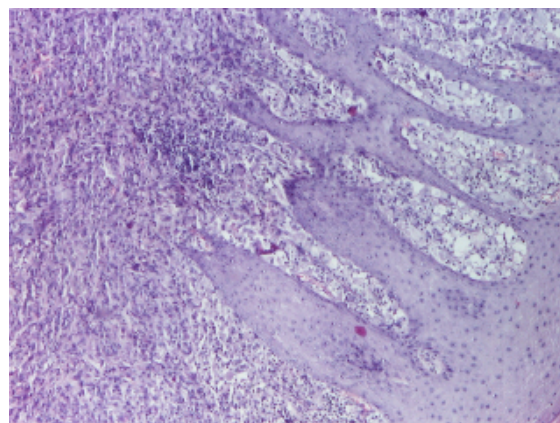


Figure 1. Excision piece, hematoxylin-eosin x 40

Tumor excision was performed. The tumor was well circumscribed and easy to remove, with no significant damage of the underlying structures.

The biopsy piece was sent to the pathology department for precise diagnose. Tissue was colored using hematoxylin-eosin and examined using a classic microscope.

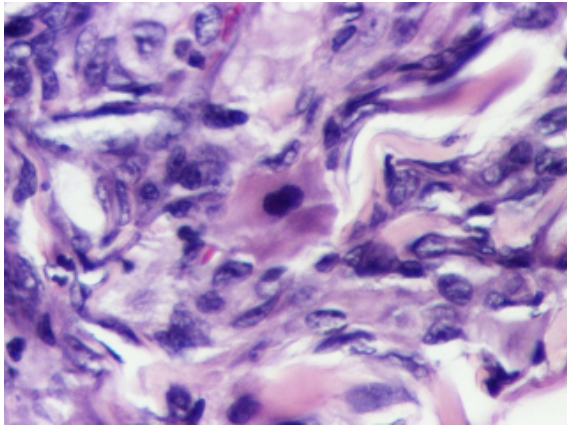


Figure 2. Excision piece, hematoxylin-eosin x 400

Examination showed fibrous tissue with storiform pattern, giant multinucleated cells, foam cells, no cytological atypia, rare hemosiderin deposits and occasional mitotic figures, thus establishing the diagnose of benign fibrous histiocytoma.

Postoperative course was favorable, the patient was dismissed 2 days after the intervention. At one month, six months, one year and 3 years follow-up he was asymptomatic, with no tumor relapse and with a normal aspect of the postoperative scar tissue.

4. Discussion

The tumor has many names, including dermatofibroma, dermal fibrous histiocytoma, sclerosing hemangioma, histiocytoma cutis, sometimes leading to misunderstanding.

Anatomopathological variants include: aneurysmal, atypical, juvenile xanthogranuloma, angiomatoid, cellular, epithelioid, osteoclastic, lipidized, monster cell, myxoid and palisading tumors.

Regarding tumor genetics, few data exists. Clonal chromosomal abnormalities have been reported in 38% of cases. Data is also scarce regarding disease etiology, but it has been observed that it is sometimes associated with insect bites, vaccines or trauma. [5] Differentiation line is unclear and multiple tumors may be associated with immunosuppression.

Benign fibrous histiocytoma has several pathologic aspects; apart from the one our patient presented, other cases may present with hemorrhage areas, numerous lipid-filled cells and, if that is the case, we are faced with a fibroxantoma. [6]

Generally, the tumor is well defined, but has no capsule. The stroma is composed of collagen and seldom has a myxoid component. Spindle cells have scant cytoplasm and the nuclei are elongated. The tumor may also comprise foamy histiocytes, multinucleated giant cells, chronic inflammatory cells and branching vessels. Cells are surrounded by collagen bundles.

The immunohistochemical profile is highly variable. The tumor may test positive for vimentin, CD 34, tenascin, calponin, actin, desmin, myosin. Histological differential diagnose should be made with atypical fibroxantoma (the storiform pattern is less defined, the pleomorphism is marked), with dermatofibrosarcoma protuberans (tests positive for CD 34), Kaposi sarcoma (immunosuppression context, lacks fibrohistiocytic cells), leiomyoma (benign muscular tumor with characteristic morphology).

Tumors, despite their benign character, may have an aggressive growth pattern. Recurrence rate is between 5 and 25%. Aneurysmal and atypical variants are more likely to metastasize. The suspicion of metastatic potential is mainly clinical. In case the patient presents with these variants, array-based comparative genomic hybridization should be performed, that might show abnormalities of chromosome 7, 8q and Xq. Recurrence rate depends on the lipid content, greater lipid component leads to a smaller recurrence rate. The tumor rarely leads to metastases and rarely regresses by itself. [7]

If recurrences do appear, adjuvant treatment consists of cryotherapy, that reduces subsequent recurrences to 3-5%. Some cases may require en bloc resection. [8, 9]

Orbital localization of benign histiocytoma leads to more severe symptoms, such as proptosis, dry eye or blurry vision, as one study showed. [10] Orbital histiocytoma is benign in 60% of cases. In this case, the tumor most often appears in patients who have previously received orbital irradiation for retinoblastoma. Differential diagnose of orbital histiocytoma should include schwannoma, cavernous hemangioma, rhabdomyosarcoma or hemangiopericytoma. [11] The tumor rarely extends into the skull.

Orbital tumor should be excised entirely, since incomplete excision may lead to recurrence. Chemotherapy or radiotherapy have so far been limited in this type of tumor, but the ten-year survival of patients with benign, locally aggressive, and malignant fibrous histiocytoma was 100 per cent, 92 per cent, and 23 per cent, respectively. [10] Furthermore, surgery is not without its risks, such as infection, blindness, incomplete excision, retrobulbar hemorrhage. The same study [10] shows a rate of recurrence was 31 per cent for the benign tumors, 57 per cent for the locally aggressive tumors, and 64 per cent for the malignant tumors.

Regarding tumor location, presentation may also vary. Another study [12] states that 58% of lesions appear on the extremities, 22% on the head and neck, 11% on the trunk and 9% in the deep soft tissue of the retroperitoneum, mediastinum, or pelvis (9%). The same authors describe the presence of giant multinucleate cells in 59% of cases; other common findings included a hemangiopericytoma-like vascular pattern (42%) and stromal hyalinization (39%). Other distinctive histologic features identified in other studies were a fascicular growth pattern, predominance of eosinophilic spindle cells with tapering nuclei and a moderate mitotic rate (mean three per 10 high-power fields). [4] None of those aspects were met in our patient.

Another study [1] that followed 16 patients for 13 years showed that the time to the first recurrence ranged from 6 weeks to 13 years and that 6 patients died from this disease over the observation period. In the same study, metastases appeared from 0 to 180 months from the time of the first diagnose.

Another particular clinical presentation that has been previously published [13] is that of a benign fibrous histiocytoma accompanied by type 2 sialidosis presenting with gingival hyperplasia and gingival tumor, but authors identify no pathogenic links between the two diseases.

In our patient, the tumor was removed in an early stage of evolution, as soon as it was discovered on clinical examination. Once distance metastases appear, prognosis may not be as favorable; unfavorable prognosis also characterizes the malignant variant of the disease, since tumor sensitivity to chemotherapy and radiotherapy is poor and rescue following initially failed treatment is difficult. Authors believe that clinical trials should also address this pathology, in order to better characterize its postoperative evolution and particularities.

5. Conclusion

Although it may be asymptomatic, especially if only subcutaneous tissue is involved, benign fibrous histiocytoma has potential for fast evolution, metastasis and re-appearance and should be excised in all cases. If evolution is unfavorable, cryotherapy should be applied in order to reduce recurrence. Case particularity consists in the young age of this patient, given the fact that this type of tumor usually affects patients over 20 years of age.

References

- [1] Doyle LA, Fletcher CD. Metastasizing "benign" cutaneous fibrous histiocytoma: a clinicopathologic analysis of 16 cases. *Am J Surg Pathol* 2013;37(4):484-495.
- [2] Niemi KM. The benign fibrohistiocytic tumours of the skin. *Acta dermato-venereologica. Suppl.* 1970; 50 (63): 1-66.
- [3] Calonje E, Fletcher CM. Cutaneous fibrohistiocytic tumours: an update. *Adv Anat Pathol.* 1994; 1: 2-15.
- [4] Calonje E, Mentzel T, Fletcher CD. Cellular benign fibrous histiocytoma. Clinicopathologic analysis of 74 cases of a distinctive variant of cutaneous fibrous histiocytoma with frequent recurrence. *The American journal of surgical pathology.* 1994; 18 (7): 668-676.
- [5] Calonje E, Fletcher CD. Aneurysmal benign fibrous histiocytoma: clinicopathologic analysis of 40 cases of a tumour frequently misdiagnosed as a vascular neoplasm. *Histopathology.* 1995; 26 (4): 323-331.
- [6] Vanni R, Marras S, Faa G, Licheri S, Daniele GM, Fletcher CD. Cellular fibrous histiocytoma of the skin: evidence of a clonal process with different karyotype from dermatofibrosarcoma. *Genes, chromosomes & cancer.* 1997; 18 (4): 314-317.
- [7] Chen TC, Kuo T, Chan HL. Dermatofibroma is a clonal proliferative disease. *Journal of cutaneous pathology.* 2000; 27 (1) : 36-39.
- [8] Calonje E. Is cutaneous benign fibrous histiocytoma (dermatofibroma) a reactive inflammatory process or a neoplasm? *Histopathology.* 2000; 37 (3): 278-280.
- [9] Vanni R, Fletcher CD, Sciort R, Dal Cin P, De Wever I, Mandahl N, Mertens F, Mitelman F, Rosai J, Rydholm A, Tallini G, Van Den Berghe H, W. Cytogenetic evidence of clonality in cutaneous benign fibrous histiocytomas: a report of the CHAMP study group. *Histopathology.* 2000; 37 (3): 212-217.
- [10] Font RL, Hidayat AA. Fibrous histiocytoma of the orbit. A clinicopathologic study of 150 cases. *Hum Pathol.* 1982 Mar;13(3):199-209.
- [11] Warner EJ, Burkat CN, Gentry LR. Orbital fibrous histiocytoma mimicking cavernous hemangioma on dynamic contrast-enhanced MRA imaging. *Ophthal Plast Reconstr Surg.* 2013 Jan-Feb;29(1):e3-5.
- [12] Gleason BC, Fletcher CD. Deep "benign" fibrous histiocytoma: clinicopathologic analysis of 69 cases of a rare tumor indicating occasional metastatic potential. *Am J Surg Pathol.* 2008; 32(3): 354-62.
- [13] Hidaka M, Yamashita A, Sakamoto K, Mukaisho K, Hattori T, Yamamoto G. Benign fibrous histiocytoma occurred in the alveolar mucosa accompanying with hialidosis type 2 in Japanese infant. *Oral Oncology Extra* 2005; 10(41): 253-258.