

# Case Report: A Case of a Cryptorchidism and Polyorchidism in Down Syndrome Child

Mohamed Khaled Shamasneh\*, Anas Ghousheh, Ibrahim Taha

Urology Department, Specialty Hospital, Amman, Jordan

\*Corresponding author: [mohammedalshamasneh@gmail.com](mailto:mohammedalshamasneh@gmail.com)

Received February 19, 2021; Revised March 26, 2021; Accepted April 06, 2021

**Abstract** Polyorchidism is an uncommon pediatric urological condition, having it in a down syndrome patient with bilateral cryptorchidism is tremendously rare. In this case report, a five-year old child with down syndrome was examined and admitted for further evaluation of bilateral undescended testicles. At the time of surgery, a third testicle was excised and sent to pathology department to exclude any type of cancer. The pathologist ruled out malignancy and confirmed the presence of atrophied testicular tissue. This is a rare case of undescended atrophied third testicle in a down syndrome child.

**Keywords:** polyorchidism, urogenital anomalies, down syndrome, bilateral cryptorchidism

**Cite This Article:** Mohamed Khaled Shamasneh, Anas Ghousheh, and Ibrahim Taha, "Case Report: A Case of a Cryptorchidism and Polyorchidism in Down Syndrome Child." *American Journal of Medical Case Reports*, vol. 9, no. 7 (2021): 358-359. doi: 10.12691/ajmcr-9-7-4.

## 1. Introduction

Undescended testicles in one of the commonest urogenital pathologies in children. The testicles are normally descend into the scrotum by the 8<sup>th</sup> month of pregnancy, if the descending was interrupted and the testis were not found in the scrotum we call it cryptorchidism "undescended testicles" [1]. On the other hand, polyorchidism is an extremely rare congenital condition which means having more than two testicles supported by histological report [2]. The most common type from polyorchidism from the literature is triorchidism which means having three testicles. Most of cases are incidental finding during surgery. Polyorchidism can be in one side or both sides with differences in completion of duplication [3]. This is a report of a rare case of polyorchidism along with bilateral undescended testicles in down syndrome patient. The two main testicles were fixed into the scrotum and the third testicle was excised and sent to pathology department. The pathology department confirmed the assumed diagnosis. Diagnosis and management are discussed thoroughly.

## 2. Case Report

a five-year old child with down syndrome presented at clinic because of emptiness of his scrotum. Upon physical examination, the scrotum was empty and both testicles were palpable in inguinal region on both sides. In addition, left inguinal hernia was present during the examination. A diagnosis of bilateral cryptorchidism with inguinal hernia was made. Admission was done for further evaluation. His paternal and maternal history were irrelevant, but there

was consanguinity. Moreover, He has two brother and four sisters whom are all healthy and well. Bilateral orchidopexy along with inguinal repair was planned. Pre-operatively, the anesthesia department cleared him for surgery. Intraoperatively, right side exploration showed single testicle followed by routine orchidopexy. Moreover, left inguinal side exploration showed two testicles with two spermatic cords conjoined by soft tissue [Figure 1]. Further dissection revealed vasa deferentia [Figure 2]. One of the testicles were fixed routinely and the other one was atrophied so; excision was performed and it was sent to pathology department to confirm. The pathologist reported that the specimen is an atrophied testicle, no residual testicular tissue was replaced by fibrous tissue. Head of epididymis was seen with chronic active inflammation. There were no signs of malignancy. Post-operatively, status of the patient was uneventful. The patient came to clinic for follow-up after one week, The operation site was healing well and there were no complications.

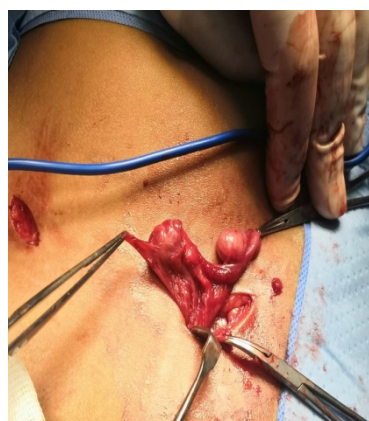


Figure 1.

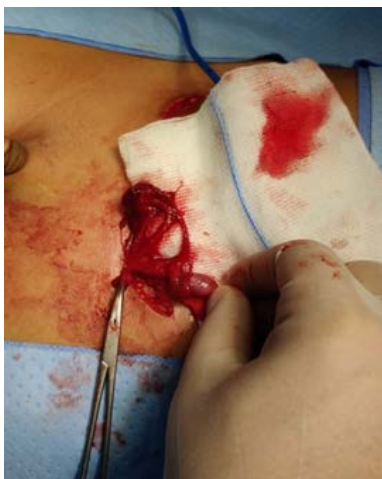

Figure 2.

### 3. Discussion

Undescended testicles is a very common medical condition in pediatrics urology. The standard treatment for it, is orchidopexy. On the contrary, Polyorchidism is uncommon urogenital pathology. There are more than one hundred case has been reported in the literature [4]. Most of cases are found incidentally during examination or surgery exploration. Many reasons had been suggested as the cause of this condition like, transverse division of the genital ridge, initial longitudinal duplication of the genital ridge, and anomalous appropriation of cells [5]. The commonly known anomalies associated with polyorchidism from the most common to the least are, cryptorchidism (40%), inguinal hernia (30%), torsion (15%), hydrocele (9%), and malignancy (6%) [6]. Many cases of polyorchidism has been reported in literature but our case , to our knowledge and literature, is the first one

to be reported as an undescended and atrophied third testicle in down syndrome patient. Our patient presented to the clinic due to absence of testicles in his scrotum. After physical examination and all necessary investigation, the decision of surgery was made. During the surgery, a third testicle which was attached to spermatic cord was excised and was sent to pathology department to rule out malignancy. The pathology report illustrated the sample to be an atrophied testicular tissue with chronic and active inflammation of epididymis and no sign of malignancy was seen.

### Conflict of Interest

The authors have no conflict of interest.

### References

- [1] Virtanen, H. E., Bjercknes, R., Cortes, D., Jørgensen, N., Rajpert-De Meyts, E., Thorsson, A. V., Thorup, J., & Main, K. M. (2007b). Cryptorchidism: classification, prevalence and long-term consequences. *Acta Paediatrica*, 96(5), 611-616.
- [2] Thyoka, M., Lall, A., & Godse, A. (2013). Polyorchidism: a torted right-sided supernumerary testis. *BMJ case reports*, 2013, bcr2013008600.
- [3] Kumar, B., Sharma, C., & Sinha, D. D. (2008). Supernumerary testis: a case report and review of literature. *Journal of pediatric surgery*, 43(6), E9-E10.
- [4] Lawrentschuk, N. (2010). Re: Polyorchidism: A Meta-Analysis. *Journal of Urology*, 183(6), 2470-2471.
- [5] Mastroeni, F., D'Amico, A., Barbi, E., Ficarra, V., Novella, G., & Pianon, R. (1997). Poliorchidismo: descrizione di due casi [Polyorchidism: 2 case reports]. *Archivio italiano di urologia, andrologia: organo ufficiale [di] Societa italiana di ecografia urologica e nefrologica*, 69(5), 319-322.
- [6] Yeniol, C. O., Nergiz, N., & Tuna, A. (2004). Abdominal polyorchidism: a case report and review of the literature. *International urology and nephrology*, 36(3), 407-408.



© The Author(s) 2021. This article is an open access article distributed under the terms and conditions of the Creative Commons Attribution (CC BY) license (<http://creativecommons.org/licenses/by/4.0/>).