

# Infective Endocarditis and COVID 19: A Systematic Review

Pramod Theetha Kariyanna<sup>1</sup>, Amog Jayarangaiah<sup>2,#</sup>, Jeewendra Dulal<sup>3,#</sup>,  
Apoorva Jayarangaiah<sup>4</sup>, Sushruth Das<sup>2</sup>, George Jojo Punnakudiyil<sup>5</sup>,  
Ashkan Tadayoni<sup>6</sup>, Michael Freilich<sup>6</sup>, Isabel M. McFarlane<sup>6,\*</sup>

<sup>1</sup>Division of Interventional Cardiology, Mount Sinai Heart,  
Icahn School of Medicine at Mount Sinai Morningside/Beth Israel Hospitals, New York City, NY-10025, U.S.A.

<sup>2</sup>Trinity School of Medicine, 925 Woodstock Road, Roswell, GA 30075, U.S.A.

<sup>3</sup>Department of Internal Medicine, Icahn School of Medicine at Mount Sinai Morningside,  
New York City, NY-10025, U.S.A.

<sup>4</sup>Division of Hematology-Oncology, Department of Internal Medicine,  
Albert Einstein College of Medicine/ Jacobi Medical Center, Bronx, N.Y.-10461, U.S.A.

<sup>5</sup>Division of Advanced Cardiac Imaging, Department of Cardiology,  
St. Francis Hospital and Heart Center, 100 Port Washington Blvd., Roslyn, NY 11576

<sup>6</sup>Department of Internal Medicine, State University of New York, Downstate Health Sciences University,  
Brooklyn, NY 11203, U.S.A.

<sup>#</sup>These authors contributed equally to this work.

\*Corresponding author: [Isabel.Mcfarlane@downstate.edu](mailto:Isabel.Mcfarlane@downstate.edu)

Received March 05, 2021; Revised April 09, 2021; Accepted April 20, 2021

**Abstract** Coronavirus Disease-19 (COVID-19) is a pandemic caused by severe Acute Respiratory Syndrome Coronavirus 2 (SARS-CoV-2). COVID-19 is known to cause a wide variety of cardiovascular manifestations, including myocarditis, pericarditis, myocardial infarction, stroke, thrombus, pulmonary embolism and acute ventricular failure. In this paper, we explore cases of infective endocarditis (IE) that occurred in patients who were concurrently (not sure if they were concurrently infected but if so, makes the sentence smoother and easier to understand) infected with COVID-19 and discuss its association in contributing to factors that can ultimately lead to the development of infective endocarditis. Some of these factors that contribute to IE in COVID-19 include severe inflammatory response, endothelial damage and dysfunction and immunosuppression caused by medications that are used to treat COVID-19. In this systematic review, 12 papers detailing 15 pertinent cases of IE following an infection with COVID-19 were identified. Data from these cases were tabulated and analyzed. The ages of the patients ranged from 20-70 years, with 73% of the patients developing IE of native heart valves and the remaining 27% developing IE of mechanical and bioprosthetic valves. The three most common organism implicated were *Enterococcus faecalis* (28.57%), Methicillin Resistant *Staphylococcus aureus* (MRSA) (14.28%), and Methicillin Sensitive *Staphylococcus aureus* (MSSA) (14.28%). Medical management of these cases involved antibiotic therapy and was reported in 80% of the cases, while only one patient (6.67%) underwent surgical valve replacement. The mortality rate of the patients in this review was quite high at 38%, and other major complications included cardioembolic stroke (20%) and septic embolization to the extremities (6.67%). COVID-19 infection results in a severe inflammatory response caused by a variety of mechanisms. This severe degree of widespread inflammation may result in damage to the endocardium, thus creating an environment to which microorganisms can adhere to and colonize. Additionally, the immunosuppressive medications used in a COVID-19 infection can result in an increased risk of developing infections that have the potential to spread to the endocardium via a hematogenous route. Physicians should be aware of occurrences of IE in COVID-19, as delay in diagnosis and management may cause significant morbidity and mortality.

**Keywords:** *Coronavirus Disease-19 (COVID-19), severe acute respiratory syndrome coronavirus 2 (SARS-CoV-2), infective endocarditis*

**Cite This Article:** Pramod Theetha Kariyanna, Amog Jayarangaiah, Jeewendra Dulal, Apoorva Jayarangaiah, Sushruth Das, George Jojo Punnakudiyil, Ashkan Tadayoni, Michael Freilich, Moro O. Salifu, and Isabel M. McFarlane, "Infective Endocarditis and COVID 19: A Systematic Review." *American Journal of Medical Case Reports*, vol. 9, no. 7 (2021): 380-385. doi: 10.12691/ajmcr-9-7-11.

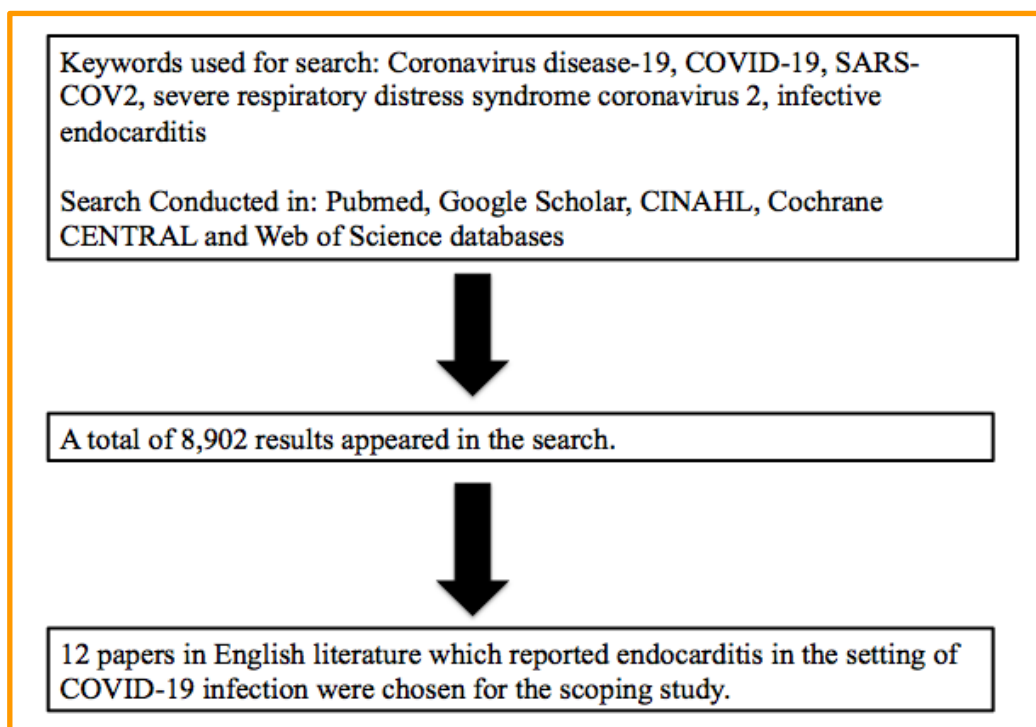
## 1. Introduction

Coronavirus disease 2019 (COVID 19), due to severe Acute Respiratory Syndrome Coronavirus 2 (SARS-COV2), remains a pandemic. Though initially considered a disease primarily of the respiratory system, subsequent data and emerging experiences are highlighting the wide variety of manifestations this disease can have. The cardiovascular system, in particular, is of special interest because cardiovascular risk factors and preexisting chronic cardiovascular conditions are prevalent among COVID 19 patients and are known to be associated with adverse outcomes [1]. Some of the cardiovascular complications of COVID 19 include ST-elevation myocardial infarction [2], myocarditis [3], apical takotsubo cardiomyopathy [4], cardiogenic shock [5], arrhythmias [5], pericardial effusions [5], and cardiac tamponade [5]. Thromboembolic complications are seen as well, including stroke [5], deep vein thrombosis [5], and pulmonary embolism via a thrombus in transit [6]. Infective endocarditis (IE) is a life-threatening disease with serious sequelae even in those that have been treated [7]. While there have been advances in medical and surgical management, IE still has substantial mortality and morbidity [8]. In addition, many of the symptoms of IE such as fever, chills, dyspnea, fatigue,

cough, and myalgia may overlap with those of COVID-19, making it difficult to suspect the presence of IE [9]. Studies have shown increased incidence of IE during the COVID pandemic [10]. Here we present a systematic review of the cases of IE in COVID-19 patients in order to understand the clinical profile of these patients as well as the organisms implicated, the valves affected, management strategies employed and the outcomes.

## 2. Methods

A systematic search was conducted on January 15, 2021 using PubMed, Google Scholar, CINAHL, Cochrane CENTRAL and Web of Science databases (Figure 1). Studies listing the keywords “Coronavirus disease-19”, “COVID-19”, “SARS-COV2”, and “infective endocarditis” were used to identify cases of IE in patients with COVID-19. The reference list of each report was also checked for additional cases. All cases were reviewed in detail. Data reviewed included demographic details, symptoms, cardiovascular risk factors, echocardiographic findings, valves affected, blood cultures and organisms, treatment and outcomes. A total of 12 papers were included, from which 15 pertinent cases were identified.



**Figure 1.** Flow chart summarizing the method of selection of cases for the study

## 3. Results

A total of 15 cases were identified from the systematic review (Table 1). The mean age was  $54.13 \pm 16.7$  years and the median age of  $60 \pm 16.7$  years. 85% of the cases affected males. All of the patients in the study (93%) had active COVID-19 infections on admission and 73% reported confirmed serologic testing with RT-PCR. Only 6% of the patients were reported to have had a previous COVID-19 infection. Of the patients admitted, 20% had presented initially with an additional infection source

(detailed in Table 1). The presenting complaints have been tabulated (Table 2), with the majority presenting with fever (80%), dyspnea (66.66%) and cough (60%). The associated cardiovascular risk factors and co-morbidities in the population were as follows: Hypertension (20%), diabetes mellitus type II (13.33%), hyperlipidemia (13.33%), history of rheumatic heart disease (13.33%), obesity (6.67%), mitral valve replacement (6.67%), Mitral and Aortic prosthetic valve (6.67%), history of closure of Patent Foramen Ovale (6.67%), Bicuspid Aortic valve and Aortic Coarctation repair in childhood (6.67%).

**Table 1. Cases included in the systematic review detailing COVID-19 status on admission and disease manifestations**

Case number	Year, Author	Age*/Sex	COVID-19 Status	Diagnostic test	COVID-19 manifestations	Additional Infections on admission
1	Ramos-Martinez [10]	70/Female	Active infection on admission. No prior infection noted	Positive RT-PCR for SARS COV-2	-	Forearm phlebitis
2	Ramos-Martinez [10]	70/Female	Active infection on admission. No prior infection noted	Positive RT-PCR for SARS COV-2	-	Sternal wound infection
3	Ramos-Martinez [10]	60/-	Active infection on admission. No prior infection noted	Positive RT-PCR for SARS COV-2	-	-
4	Ramos-Martinez [10]	60/-	Active infection on admission. No prior infection noted	Positive RT-PCR for SARS COV-2	-	Central venous catheter infection
5	Alizadehasl [11]	24/Male	Covid-19 infection 3 weeks prior. Active infection on admission	Positive RT-PCR for SARS COV-2	Viral pneumonia	-
6	Amir [12]	61/Male	Active infection on admission. No prior infection noted	Positive RT-PCR for SARS COV-2	Viral pneumonia	-
7	Dias [13]	36/Male	Active infection on admission. No prior infection noted	Positive RT-PCR for SARS COV-2	Severe respiratory distress	-
8	Hussain [14]	69/Male	Active infection noted on retesting . No prior infection noted	Positive RT-PCR for SARS COV-2	Viral Pneumonia	-
9	Kwon [15]	65/Male	Active infection on admission. No prior infection noted	-	-	-
10	Sanders [16]	38/Male	Active infection on admission. No prior infection noted	Positive RT-PCR for SARS COV-2	-	-
11	Spinoni [17]	57/Male	Active infection on admission. No prior infection noted	Positive RT-PCR for SARS COV-2	Acute respiratory distress syndrome (ARDS)	-
12	Velez-Paez [18]	53/Male	Active infection on admission. No prior infection noted	Positive RT-PCR for SARS COV-2	Acute respiratory distress syndrome (ARDS)	-
13	Regazzoni [19]	70/Male	Active infection on admission. No prior infection noted	-	Bilateral pneumonia	-
14	Mantero [20]	59/Male	Active infection on admission. No prior infection noted	-	-	-
15	Toth [21]	20/Male	Active infection on admission. No prior infection noted	-	Pneumonia	-

\*Age in years.  
RT-PCR: Reverse transcription polymerase chain reaction.  
SARS COV-2: Severe Acute Respiratory Syndrome Coronavirus 2

**Table 2. Chief complaint at COVID-19 presentation**

Fever	80%
Dyspnea	66.66%
Cough	60%
Lower limb edema	6.67%
Chest pain	6.67%
Diarrhea	6.67%
Aphasia and right facial deficit	6.67%
Arthritis	6.67%
Meningitis	6.67%

A majority of the patients developed IE of a native valve (73%) and the remaining patients developed it in artificial valves (27%). The most common valves affected were the native mitral (33.33%) and aortic valve (33.33%), followed by prosthetic aortic valve (20%), prosthetic mitral valve (6.67%) and native tricuspid valve (6.67%) (Table 3). The four most common organism implicated were *Enterococcus faecalis* (28.57%), followed by *Methicillin Resistant Staphylococcus aureus* (MRSA) (14.28%), *Methicillin Sensitive Staphylococcus aureus* (MSSA) (14.28%), and *Staphylococcus aureus* (14.28%). Additional organisms that were identified also included *Methicillin-Resistant Staphylococcus hominis* (7.14%), *Pseudomonas aeruginosa* (7.14%) and *Candida albicans* (7.14%). Only one case (7.14%) reported culture negative findings (Table 4). Medical management of the

cases consisted mainly of antibiotic therapy and was reported in 80% of the cases, with only 1 patient (6.67%) undergoing surgical valve replacement. Major complications included cardioembolic stroke (20 %) and septic embolization of extremities (6.67%). Fatality occurred in 38% of the cases (Table 5). The Echocardiographic findings for each case have been tabulated and displayed (Table 6).

**Table 3. Affected heart valves in COVID-19 associated endocarditis**

Native aortic valve	33.33%
Native mitral valve	33.33%
Prosthetic aortic valve	20%
Prosthetic mitral valve	6.67%
Native tricuspid valve	6.67%

**Table 4. Organisms implicated in COVID-19 Infective endocarditis**

<i>Enterococcus faecalis</i>	28.57%
MRSA	14.28%
MSSA	14.28%
<i>Staphylococcus aureus</i>	14.28%
<i>Methicillin resistant Staphylococcus hominis</i>	7.14%
<i>Pseudomonas aeruginosa</i>	7.14%
<i>Candida albicans</i>	7.14%
Culture-negative	7.14%

MRSA *Methicillin resistant Staphylococcus aureus*  
MSSA *Methicillin sensitive Staphylococcus aureus*.

**Table 5. Table showing the implicated organisms and affected valves for the listed cases, as well as the therapeutic management and outcomes**

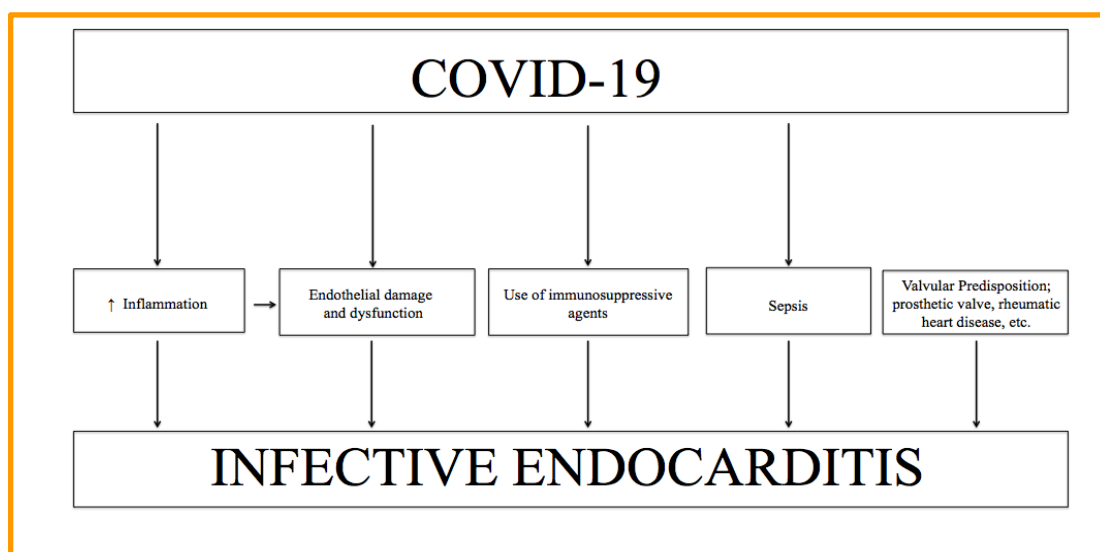
Case number	Year, Author	Age/Sex	Organism implicated	Valve affected	Valve type	Medical management	Valve replacement	Complications	Death
1	Ramos-Martinez [10]	70/Female	Enterococcus faecalis	Mitral valve	Native	Ampicillin, ceftriaxone	-		None
2	Ramos-Martinez [10]	70/Female	Candida albicans	Aortic valve	Prosthetic	Anidulafungin, fluconazole	-		Yes
3	Ramos-Martinez [10]	60/-	Enterococcus faecalis	Mitral valve	Native	Ampicillin, ceftriaxone	-		None
4	Ramos-Martinez [10]	60/-	Methicillin-sensitive Staphylococcus aureus	Mitral valve	Native	Cefazolin	-		None
5	Alizadehasl [11]	24/Male	Staphylococcus aureus	Mitral valve	Mechanical	Azithromycin, hydroxychloroquine, corticosteroids	-		None
6	Amir [12]	61/Male	Culture negative	Mitral valve	Native	-	-		None
7	Dias [13]	36/Male	Methicillin-resistant Staphylococcus aureus	Mitral valve	Native	Vancomycin, meropenem, gentamicin	-	Septic embolization to the right leg and right hand	Yes
8	Hussain [14]	69/Male	Staphylococcus aureus	Aortic valve	Prosthetic	Gentamicin, flucloxacillin	-		Yes
9	Kwon [15]	65/Male	Pseudomonas aeruginosa	Mitral valve	Native	Piperacillin/tazobactam, levofloxacin	-	Cardioembolic stroke causing right sided hemiparesis	None
10	Sanders [16]	38/Male	Enterococcus faecalis	Aortic valve	Native	Ampicillin, ceftriaxone	Yes		None
11	Spinoni [17]	57/Male	Methicillin-resistant Staphylococcus aureus	Aortic valve	Native	Linezolid, ceftazidime/avibactam, Fosfomycin	-		None
12	Velez-Paez [18]	53/Male	Methicillin resistant Staphylococcus hominis	Aortic valve	Native	Vancomycin, gentamicin	-		Yes
13	Regazzoni [19]	70/Male	Methicillin-sensitive Staphylococcus aureus	Aortic valve	Native	-	-	Embolic stroke	-
14	Mantero [20]	59/Male	Enterococcus faecalis	Aortic valve	Prosthetic	Ampicillin, ceftriaxone	-	Embolic stroke	-
15	Toth [21]	20/Male	-	Aortic valve	Native		-		Yes

**Table 6. Cases included in the systematic review and corresponding echocardiography findings**

Case number	Year, Author	TTE	TEE
1	Ramos-Martinez [10]	-	Vegetation 7 mm on mitral valve
2	Ramos-Martinez [10]	-	Hypoechogetic aortic perivalvular thickening (1.3 cm). Extension to mitral-aortic junction and aortic root (abscess)
3	Ramos-Martinez [10]	-	A 22mm Vegetation on the mitral valve. Moderate mitral insufficiency
4	Ramos-Martinez [10]	-	Mild mitral insufficiency without vegetations
5	Alizadehasl [11]	-	Several typical vegetations on the posterior prosthetic mitral valve leaflet
6	Amir [12]	Flail mitral leaflet with a vegetation measuring 10 mm × 3 mm in size, producing severe mitral regurgitation	-
7	Dias [13]	5 cm mobile vegetation on the tricuspid valve with severe tricuspid regurgitation	-
8	Hussain [14]	-	Vegetations on all three cusps of the aortic valve, with no significant aortic regurgitation,

Case number	Year, Author	TTE	TEE
9	Kwon [15]	Vegetation of approximately 5 mm on the mitral valve	-
10	Sanders [16]	10 x 11 mm mobile echo-density on the right coronary cusp as well as a possible smaller vegetation on the left coronary cusp of the aortic valve.	Two aortic valve vegetations: 8 x 14 mm on the right coronary cusp and 3 x 4 mm on the left coronary cusp.
11	Spinoni [17]	A poor ultrasound window, that was not conclusive for IE and showed mild mitral regurgitation	Presence of endocarditis vegetation (6 x 7 mm in diameter) on the non-coronary cusp of the aortic valve
12	Velez-Paez [18]	Vegetation was observed in the aortic valve without signs of valve insufficiency	-
13	Regazzoni [19]	-	Large vegetations on the aortic valve with severe regurgitation
14	Mantero [20]	IE at the level of the biological prosthetic valve and a suspected periprosthetic abscess.	-
15	Toth [21]	Severe aortic regurgitation, a large aortic valve vegetation, and aortic root abscess	-

**TTE** Transthoracic Echocardiography **TEE** Transesophageal Echocardiography **IE** Infective endocarditis



**Figure 2.** Flow chart summarizing the potential factors that lead to the development of endocarditis from a COVID-19 infection

## 4. Discussion

Despite many advancements in care, IE is a disease that still carries a high rate of morbidity and mortality. Mortality rates can be approximately 25% even with appropriate management [7], and it carries a 1-year mortality of about 40% [9]. The occurrence of IE in the setting of COVID-19 infection could possibly be explained by the degree of inflammation caused by the COVID-19 infection. Damaged endocardial surfaces are a prime location for pathogenic organisms to adhere to and subsequently proliferate. Inflammation induced endocardial damage can be an appropriate site that a pathogen can adhere to and colonize [7]. The excessive inflammatory response of COVID-19 is already well defined through numerous mechanisms including a cytokine storm [21], so we can therefore hypothesize that the excessive inflammatory response may lead to damage of the endocardium of native heart valves. This can create a suitable surface to which pathogens can adhere to and precipitate the development of IE. (Figure 2) illustrates a summary of the events that a COVID-19 infection may lead to IE.

Additional factors that can increase the risk of developing IE include sepsis, immunosuppression and possessing prosthetic heart valves. Sepsis creates one of

the core requirements for IE to take place, that is, the presence of an organism that is able to adhere to and colonize the endocardial surface [7]. COVID-19 patients that develop critical illness are at a higher risk of developing bacteremia or even fungemia [23]. This risk of sepsis is also increased due to widespread use of immunosuppressive agents involved in the treatment of COVID-19 patients. Lastly, prosthetic heart valves are a commonly known risk factor for IE [7] and it was seen in 27% of the patients in this study. All of these risk factors can compound with one another and increase the risk of IE. Unfortunately, many of the symptoms can overlap with other conditions and make diagnosis of IE difficult. Due to the high rate of mortality, knowledge of this potential complication is important so that timely treatment can be given and improve survival chances.

Since this systematic review focused on the published literature that reported an instance of stent thrombosis occurring in the setting of COVID-19 infection, it might be subject to selection bias. In addition, due to the limited number of published literature regarding this incidence, the low sample size is a limiting factor of this study. Lastly, all of the referenced studies were either case reports or case series without any control group to enhance the accuracy of the comparison.

## 5. Conclusions

The majority of patients with IE and COVID 19 were elderly males who presented with chief complaints of fever, dyspnea and cough. The most common valves that were affected, were the native mitral and aortic valves, followed by prosthetic aortic valves. The most common organism implicated was *Enterococcus faecalis*. One patient needed valvular replacement and a high mortality of 38% was noted. One of the main goals of this study is to alert physicians of coexisting IE in COVID-19 patients.

## References

- [1] Lang JP, Wang X, Moura FA, Siddiqi HK, Morrow DA, Bohula EA. A current review of COVID-19 for the cardiovascular specialist. *Am Heart J*. 2020; 226: 29-44.
- [2] Kariyanna, P. T., Hossain, N., Jayarangaiah, A., Hossain, N. A., Francois, J. C., Marmur, J. D., Salifu, M. O., & McFarlane, S. I. (2020). Pharmaco-invasive Therapy for STEMI in a Patient with COVID-19: A Case Report. *American journal of medical case reports*, 8(7), 192-196.
- [3] Kariyanna PT, Sutarjono B, Grewal E, et al. A Systematic Review of COVID-19 and Myocarditis. *Am J Med Case Rep*. 2020; 8(9): 299-305.
- [4] Kariyanna PT, Chandrakumar HP, Jayarangaiah A, et al. Apical Takotsubo Cardiomyopathy in a COVID-19 Patient Presenting with Stroke: A Case Report and Pathophysiologic Insights. *Am J Med Case Rep*. 2020; 8(10): 350-357.
- [5] Hendren NS, Grodin JL, Drazner MH. Unique Patterns of Cardiovascular Involvement in Coronavirus Disease-2019. *J Card Fail*. 2020; 26(6): 466-469.
- [6] Kariyanna, Pramod Theetha, et al. 'Thrombus in Transit and Impending Pulmonary Embolism Detected on POCUS in a Patient with COVID-19 Pneumonia.' *American Journal of Medical Case Reports* 8.8 (2020): 225-228.
- [7] Holland TL, Baddour LM, Bayer AS, Hoen B, Miro JM, Fowler VG Jr. Infective endocarditis. *Nat Rev Dis Primers*. 2016; 2: 16059. Published 2016 Sep 1.
- [8] Thuny, F., Grisoli, D., Collart, F., Habib, G., & Raoult, D. (2012). Management of infective endocarditis: challenges and perspectives. *The Lancet*, 379(9819), 965-975.
- [9] Murdoch, D. R., Corey, G. R., Hoen, B., Miró, J. M., Fowler, V. G., Jr, Bayer, A. S., Karchmer, A. W., Olaison, L., Pappas, P. A., Moreillon, P., Chambers, S. T., Chu, V. H., Falcó, V., Holland, D. J., Jones, P., Klein, J. L., Raymond, N. J., Read, K. M., Tripodi, M. F., Utili, R., ... International Collaboration on Endocarditis-Prospective Cohort Study (ICE-PCS) Investigators (2009). Clinical presentation, etiology, and outcome of infective endocarditis in the 21st century: the International Collaboration on Endocarditis-Prospective Cohort Study. *Archives of internal medicine*, 169(5), 463-473.
- [10] Ramos-Martinez, A., Fernández-Cruz, A., Dominguez, F., Forteza, A., Cobo, M., Sanchez-Romero, I., & Asensio, A. (2020). Hospital-acquired infective endocarditis during Covid-19 pandemic. *Infection Prevention in Practice*, 2(3), 100080. <https://www.sciencedirect.com/science/article/pii/S2590088920300445?via%3Dihub>.
- [11] Alizadehasl, A., Salehi, P., Roudbari, S., & Peighambari, M. M. (2020). Infectious endocarditis of the prosthetic mitral valve after COVID-19 infection. *European heart journal*, 41(48), 4604-4604.
- [12] Amir, M., Djaharuddin, I., Sudharsono, A., & Ramadany, S. (2020). COVID-19 concomitant with infective endocarditis: A case report and review of management. *International journal of infectious diseases : IJID : official publication of the International Society for Infectious Diseases*, 98, 109-112.
- [13] Dias, C. N., Brasil Gadelha Farias, L. A., & Moreira Barreto Cavalcante, F. J. (2020). Septic Embolism in a Patient with Infective Endocarditis and COVID-19. *The American Journal of Tropical Medicine and Hygiene*, 103(6), 2160-2161. Retrieved Jan 29, 2021.
- [14] Hussain, A., Roberts, N., & Oo, A. (2020). Prosthetic aortic valve endocarditis complicated by COVID - 19 and hemorrhage. *Journal of cardiac surgery*, 35(6), 1348-1350.
- [15] Kwon, D. H., Park, J. S., Park, H. J., Sohn, S. I., & Hong, J. H. (2020). Cerebral infarction caused by endocarditis in a patient with COVID-19. *Journal of Neurocritical Care*, 13(2), 101-104.
- [16] Sanders, D. J., Sutter, J. S., Tatoes, A., Suboc, T. M., & Rao, A. K. (2020). Endocarditis Complicated by Severe Aortic Insufficiency in a Patient with COVID-19: Diagnostic and Management Implications. *Case Reports in Cardiology*, 2020. <https://www.hindawi.com/journals/cric/2020/8844255/>.
- [17] Spinoni, E. G., Degiovanni, A., Della Corte, F., & Patti, G. (2020). Infective endocarditis complicating COVID-19 pneumonia: a case report. *European Heart Journal: Case Reports*. <https://academic.oup.com/ehjcr/article/4/6/1/5960197>.
- [18] Vélez-Páez, Jorge L., López-Rondon, Edgar F., Jara-González, Fernando E., & Castro-Reyes, Evelyn E .. (2020). Bacterial endocarditis due to native valve *Staphylococcus hominis* in a hospitalized patient with COVID-19. Case report. *Acta Médica Peruana*, 37 (3), 336-340.
- [19] Regazzoni, V., Loffi, M., Garini, A., & Danzi, G. B. (2020). Glucocorticoid-Induced Bacterial Endocarditis in COVID-19 Pneumonia- Something to Be Concerned About?. *Circulation journal: official journal of the Japanese Circulation Society*, 84(10), 1887.
- [20] Mantero, V., Rigamonti, A., Basilico, P., Sangalli, D., Scaccabarozzi, C., & Salmaggi, A. (2020). Stroke in a Feverish Patient with COVID-19 Infection and Unknown Endocarditis. *Journal of clinical neurology (Seoul, Korea)*, 16(4), 707-708.
- [21] Toth, E., Dancy, L., Amin-Youssef, G., Papachristidis, A., & Dworakowski, R. (2020). Collateral implications of the COVID-19 pandemic: belated presentation of infective endocarditis in a young patient. *European heart journal*, 41(45), 4365.
- [22] Jayarangaiah A, Kariyanna PT, Chen X, Jayarangaiah A, Kumar A. COVID-19-Associated Coagulopathy: An Exacerbated Immunothrombosis Response. *Clinical and Applied Thrombosis/Hemostasis*. January 2020.
- [23] Giacobbe, D. R., Battaglioli, D., Ball, L., Brunetti, I., Bruzzone, B., Codda, G., Crea, F., De Maria, A., Dentone, C., Di Biagio, A., Icardi, G., Magnasco, L., Marchese, A., Mikulska, M., Orsi, A., Patroniti, N., Robba, C., Signori, A., Taramasso, L., Vena, A., ... Bassetti, M. (2020). Bloodstream infections in critically ill patients with COVID-19. *European journal of clinical investigation*, 50(10), e13319.

