

# Melkersson-Rosenthal Syndrome Associated to Behçet Disease

Salem Bouomrani<sup>1,2,\*</sup>, Abir Masmoudi<sup>1,2</sup>, Sihem Riahi<sup>1,2</sup>,  
Mohamed Amin Bouaziz<sup>1,2</sup>, Nour Wali<sup>1,2</sup>, Warda Mahdhaoui<sup>1,2</sup>

<sup>1</sup>Department of Internal medicine, Military Hospital of Gabes, Gabes 6000, Tunisia

<sup>2</sup>Sfax Faculty of Medicine, University of Sfax, Sfax 3029, Tunisia

\*Corresponding author: [salembouomrani@yahoo.fr](mailto:salembouomrani@yahoo.fr)

Received February 19, 2021; Revised March 22, 2021; Accepted March 30, 2021

**Abstract** Melkersson-Rosenthal syndrome (MRS) is an extremely rare disorder whose complete and typical form associates the triad: recurrent nonpitting orofacial edema, facial paralysis, and lingua plicata (fissured dorsal tongue). The exact pathogenesis of this disease is not yet fully understood. Its association with several other autoimmune disorders and the granulomatous nature of this syndrome suggest a dysimmune origin. The association with systemic vasculitis remains unusual with only two cases previously reported. We report the original case of MRS associated with Behçet disease in a 36-year-old Tunisian woman with favorable outcome under colchicine. Our observation is, to our knowledge, the first to report this association.

**Keywords:** Melkersson-Rosenthal syndrome, Behçet disease, systemic vasculitis, granulomatosis, lingua plicata

**Cite This Article:** Salem Bouomrani, Abir Masmoudi, Sihem Riahi, Mohamed Amin Bouaziz, Nour Wali, and Warda Mahdhaoui, "Melkersson-Rosenthal Syndrome Associated to Behçet Disease." *American Journal of Medical Case Reports*, vol. 9, no. 6 (2021): 342-344. doi: 10.12691/ajmcr-9-6-10.

## 1. Introduction

Described for the first time in 1928 by Ernst Gustav Melkersson [1], and defined as an authentic nosological entity in 1932 by Curt Rosenthal [2], Melkersson-Rosenthal syndrome (MRS) is an extremely rare neuromucocutaneous disorder with multifactorial pathogenesis involving inflammation, immune deficiency, infections, stress, food intolerance, and genetic predisposition [3,4]. Its incidence is estimated at 0.08%, and its complete and typical clinical presentation associates recurrent nonpitting orofacial edema, facial paralysis, and fissured dorsal tongue (lingua plicata) [3,4,5]. This triad is noted only in 8-25% of patients with MRS; other forms are called oligosymptomatic or monosymptomatic and represent a real diagnostic challenge [5].

The association of this syndrome with other systemic and/or autoimmune diseases has been reported [6]. That with systemic vasculitis remains exceptional and unusual with only two cases found in the world literature [7,8].

We report the original case of MRS associated with Behçet disease; an association which, to our knowledge, has not been reported before.

## 2. Case Presentation

A 36-year-old woman with a past personal history of primary hypothyroidism, allergic rhinitis, asthma, and three episodes of reversible peripheral facial paralysis

managed by systemic corticosteroids, was referred to our consultation for persistent lips edema.

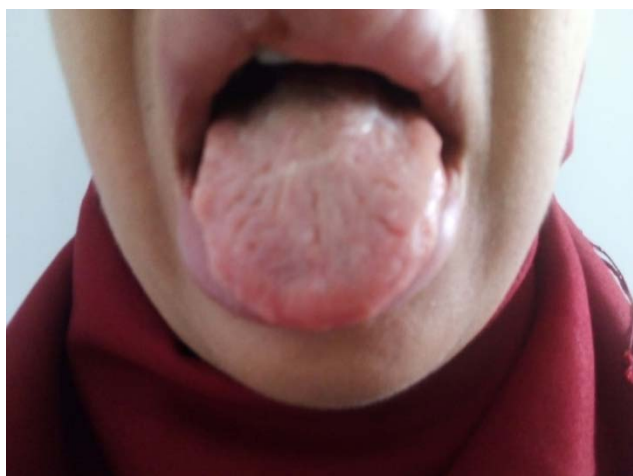
Its history goes back four years, with the occurrence of cyclic episodes of edema of the lips, particularly the upper one, associated three times with peripheral facial palsy (left in 2016, right in 2017, and left in 2018). The biological assessment in the three episodes was without abnormalities as well as cerebral magnetic resonance imaging in 2017. She was treated with systemic corticosteroids with regression of the facial paralysis but the orofacial edemas continue to recur.

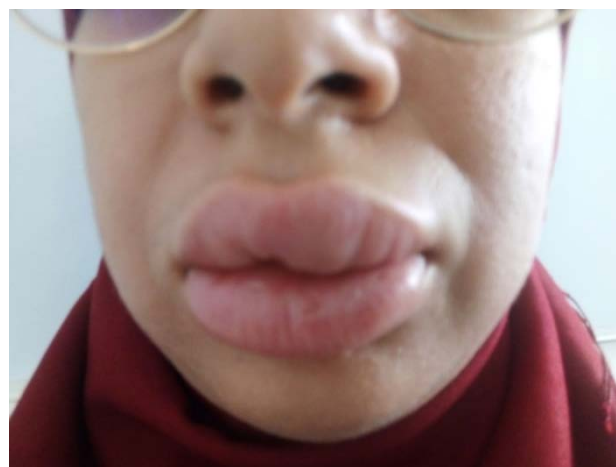

Figure 1. marked edema of the lips

Somatic examination noted an indolent and nonpitting edema of lips without any change in color (Figure 1), macroglossia, and fissured tongue with multiple dorsal

transverse cracks (lingua plicata) (Figure 2). No facial asymmetry was noted and examination of the cranial pairs did not show any abnormalities.



**Figure 2.** macroglossia with fissured tongue (lingua plicata)

Biopsy of accessory salivary glands objectified noncaseating granulomas with chronic sialadenitis, moderate fibrosis, and vasculitis.

The basic laboratory tests were within normal limits: total blood count, erythrocyte sedimentation rate, C-reactive protein, fast glycaemia, transaminases, calcemia, creatinine, uric acid, muscle enzymes, ionogram, lipid parameters, and electrophoresis of serum proteins. Thyroid-stimulating hormone was at 2.60  $\mu$ UI/ml and C1-inhibitor assay was normal.

Subsequent investigations made it possible to eliminate other granulomatosis, especially sarcoidosis and tuberculosis: specialized ENT examination with sinus radiography, chest X-ray, thoraco-abdomino-pelvic CT scan, quantiferon, and angiotensin converting enzyme activity measurement.

Based on these findings (recurrent facial paralysis, recurrent orofacial edema, lingua plicata, and noncaseating granulomas at lip biopsy) the diagnosis of MRS was retained.

The images of vasculitis on the lip biopsy were unusual and prompted us to look for possible associated systemic vasculitis.

The resumption of the questioning revealed the notion of recurrent mouth ulcers since childhood and three episodes of genital ulcers in the last year.

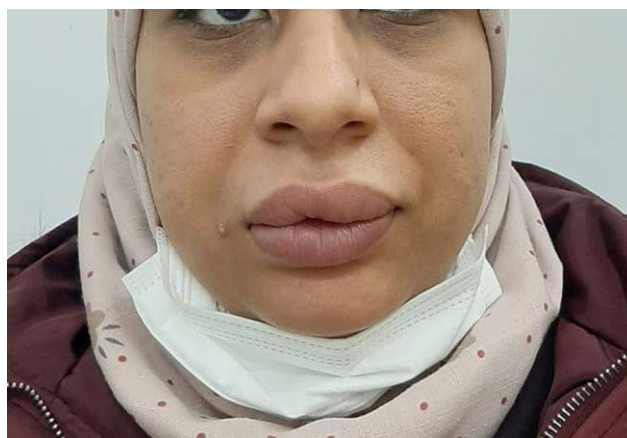Closer somatic examination noted two aphthous ulcerations on the inside of the right cheek, hypochromic scars on the labia majora, dermatographism, and multiple necrotic pseudofolliculitis on the back.

The Pathergy test was positive and HLA typing revealed a B51 haplotype. The ophthalmologic examination was without abnormalities as well as brain MRI and lumbar puncture. Thus, the diagnosis of Behçet's disease without neurological involvement was retained.

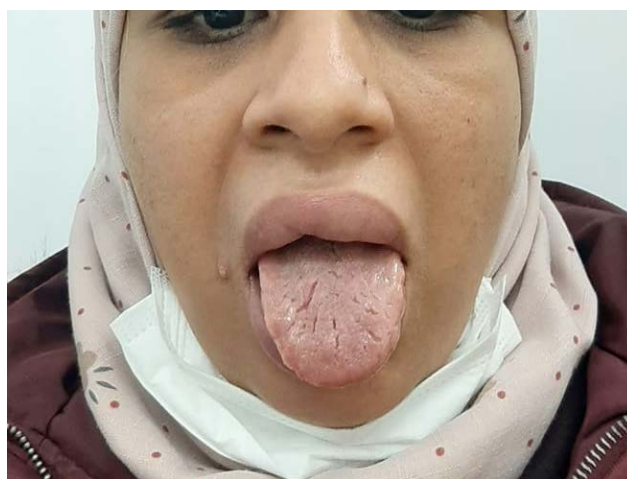Anti-nuclear, anti-double-stranded DNA, anti-soluble antigen, and anti-neutrophil cytoplasmic antibodies (ANCA) were negative eliminating ANCA-associated vasculitis or vasculitis secondary to connective tissue diseases.

The patient was treated with colchicine with a rapidly favorable outcome: total regression of lip edema

(Figure 3), clear regression of macroglossia and lingual fissures (Figure 4), and absence of recurrence.



**Figure 3.** Total regression of lip edema after colchicine treatment



**Figure 4.** Clear regression of macroglossia and lingual fissures after colchicine treatment

### 3. Discussion

Patients diagnosed with MRS may have other comorbidities, particularly of dysimmune origin. The most frequently reported associations are: autoimmune thyroiditis, systemic lupus erythematosus, psoriasis, sarcoidosis, inflammatory bowel diseases, and multiple sclerosis [6,8,9,10,11,12].

The combination of MRS with systemic vasculitis remains exceptional and unusual; indeed the review of the literature finds only two cases: one sporadic case of vascular purpura reported by Braunsteiner and Sailer in 1964 [7], and one case of unspecified vasculitis in 2013 in the large series of Elias MK et al. of 72 patients with biopsy-confirmed MRS [8].

The association with Behçet's disease, which is a systemic vasculitis particularly frequent in the Mediterranean basin and countries along the ancient silk road [13,14], has not been previously reported.

These two diseases present several common pathogenic mechanisms, particularly genetic predisposition, autoinflammatory character, and immune dysfunction [3,4,13,14]. Likewise, several specific symptoms of

Behçet's disease have been reported in patients with MRS: aphthous ulcers [2], uveitis [15], arthritis [16], and erythema nodosum [2].

These different findings suggest that the association between MRS and Behçet's disease is far from being a mere coincidence. MRS can thus, as in our observation, be an early manifestation of Behçet's disease.

#### 4. Conclusion

Our observation is to our knowledge the first reporting the association of Melkersson - Rosenthal Syndrome and Behçet's disease. Behçet's disease should therefore be mentioned in patients with MRS, particularly in countries where this vasculitis is frequently responded and if the patient has other systemic symptoms. In our case, the good evolution under colchicine and the absence of recurrences after treatment reinforce this hypothesis.

#### References

- [1] Melkersson E. Ett fall av recidiverande facialisparese i samband med angioneurotiskt ödem. *Hygiea*. 1928; 90: 737-41.
- [2] Rosenthal C. Klinisch-erbblologischer Beitrag zur konstitutionspathologie Gemeinsames auftreten von (rezidivierender familiärer) facialislähmung, angio-neurotischem gesichtsödem und lingua plicata in arthritismus-familien. *Z Neurol Psychiatr*. 1931; 131: 475-501.
- [3] Bakshi SS. Melkersson-Rosenthal Syndrome. *J Allergy Clin Immunol Pract*. 2017; 5(2): 471-472.
- [4] Wehl G, Rauchenzauner M. A Systematic Review of the Literature of the Three Related Disease Entities Cheilitis Granulomatosa, Orofacial Granulomatosis and Melkersson - Rosenthal Syndrome. *Curr Pediatr Rev*. 2018; 14(3):196-203.
- [5] Basman A, Gumusok M, Degerli S, Kaya M, Toraman Alkurt M. Melkersson-rosenthal syndrome: a case report. *J Istanbul Univ Fac Dent*. 2017; 51(1): 42-45.
- [6] Bouomrani S, Lamloum I, Mesfar R. Melkersson-Rosenthal syndrome associated to Hashimoto's thyroiditis. *Clin Sci Res Rep*. 2020; 3: 1-2.
- [7] Braunsteiner H, Sailer S. Vascular purpura as prodromal symptom of the Melkersson-Rosenthal syndrome. *Wien Z Inn Med*. 1964; 45: 509-12.
- [8] Elias MK, Mateen FJ, Weiler CR. The Melkersson-Rosenthal syndrome: a retrospective study of biopsied cases. *J Neurol*. 2013; 260(1): 138-43.
- [9] Halevy S, Shalom G, Trattner A, Bodner L. Melkersson-Rosenthal syndrome: a possible association with psoriasis. *J Am Acad Dermatol*. 2012; 67(4): 795-6.
- [10] Haaramo A, Kolho KL, Pitkäranta A, Kanerva M. A 30-year follow-up study of patients with Melkersson-Rosenthal syndrome shows an association to inflammatory bowel disease. *Ann Med*. 2019; 51(2): 149-155.
- [11] Cabrera-Gómez JA, Echazabal-Santana N, Real-González Y, Romero García K, Junior Sobrinho M, Gil Ocaña MA, et al. Hereditary Melkersson-Rosenthal syndrome and multiple sclerosis. *Mult Scler*. 2005; 11(3): 364-6.
- [12] Binkley GW. Melkersson-Rosenthal syndrome with associated features of chronic discoid lupus erythematosus and sarcoidosis. *Arch Dermatol*. 1964; 90: 111.
- [13] Bulur I, Onder M. Behcet disease: New aspects. *Clin Dermatol*. 2017; 35(5): 421-434.
- [14] Williams DS. Behcet's Disease. *J Insur Med*. 2019; 48(1): 103-105.
- [15] Ates O, Yoruk O. Unilateral anterior uveitis in Melkersson-Rosenthal syndrome: a case report. *J Int Med Res*. 2006; 34(4): 428-32.
- [16] Liu R, Yu S. Melkersson-Rosenthal syndrome: a review of seven patients. *J Clin Neurosci*. 2013; 20(7): 993-5.



© The Author(s) 2021. This article is an open access article distributed under the terms and conditions of the Creative Commons Attribution (CC BY) license (<http://creativecommons.org/licenses/by/4.0/>).