

Lipoma Arborescence of Left Knee in a 19 Year Old Man: A Case Report

Islam MA*, Shahin MA, Haq SA, Choudhury MR

Department of Rheumatology, Bangabandhu Sheikh Mujib Medical University (BSMMU), Dhaka, Bangladesh

*Corresponding author: ariful_islam7400@yahoo.com

Received January 02, 2021; Revised January 07, 2021; Accepted January 26, 2021

Abstract Lipoma Arborescens is a rare benign intra-articular lesion most frequently found in the knee identified by the villous proliferation of the synovium. It usually presents as an enduring, slowly progressive swelling of one or more joints, which may or may not be associated with pain. Patients typically present with chronic and recurrent painless swelling of the joints. MRI demonstrated replacement of sub synovial tissue by mature fat cell, is clearly seen in STIR sequence.

Keywords: *Lipoma arborescences, Supra patellar, Synovectomy, Sub synovial tissue*

Cite This Article: Islam MA, Shahin MA, Haq SA, and Choudhury MR, "Lipoma Arborescence of Left Knee in a 19 Year Old Man: A Case Report." *American Journal of Medical Case Reports*, vol. 9, no. 4 (2021): 219-225. doi: 10.12691/ajmcr-9-4-4.

1. Introduction

Lipoma arborescences (LA) is a rare and benign condition characterized by diffuse replacement of sub-synovial tissue by mature adipocytes with prominent villous transformation. The etiology of lipoma arborescences is unknown although the causal association between lipoma arborescences and degenerative joint disease give a hint to the possibility of a reaction process [1,2]. Lipoma arborescens is a monoarticular condition that occurs more commonly in men, in the fourth and fifth decade, and most often, in the knee joint. [3] It follows an indolent course. Lipoma arborescens is divided into a primary and a secondary type. The primary type is a rare form of synovial lipomatosis with hypertrophy as the main feature and degenerative knee joint changes. The secondary type has been defined as lipomatosis resulting from chronic irritation of the synovium and is the most common form of lipoma arborescence [4,5]. Though the knee is usually affected joint, there are also reports of involvement in the wrist [6], elbow [7], shoulder [8], ankle [9], and hip [10].

2. Patient and Observation

A 19-year-old male presented to the Department of Rheumatology, Bangabandhu Sheikh Mujib Medical University with gradually increasing inflammatory pain and swelling in the left knee for seven years. Initially, it was episodic. The first episode persisted for two weeks. He experienced 5 episodes of pain and swelling with a relatively symptom-free period of 3-6 months. Fluid from his affected knee was aspirated 7 times, followed by intra-articular glucocorticoid injection. Initially, the patient was

presented with painful swelling, but for last two (2) years, it became painless. He had no past medical history of tuberculosis or any contact with active tuberculosis patients he denies any history of trauma. There was no history of pain in other joints, enthesitis, low back pain, and family history of rheumatic disease or eye disease. On examination, there was diffuse swelling of the left knee predominantly on the suprapatellar aspect (Figure 1). The swelling was doughy in consistency with minimal, limited range of movement. The right knee was normal. Laboratory investigations revealed ESR 28, CRP normal. Tuberculin test was negative. Plain X-ray shows soft tissue swelling in the suprapatellar area with preserved joint space (Figure 2). Figure 3, Figure 4 & Figure 5 MSK USG of left knee Medial, lateral Para patellar and suprapatellar area (Hyperechoic frond-like projection of synovial membrane into effusion). The synovial fluid study was inconclusive with ADA 31.5 and negative gene Xpert for mycobacterium. Musculoskeletal Ultrasonogram revealed frond-like synovial proliferation in the suprapatellar, medial, and lateral parapatellar area with effusion. MRI of the left knee was performed in sagittal SE T1, FSE T2, GE, and axial SE T1, FSE T2, and coronal SE T1, FSE T2 sequences. It showed arborizing hypertrophy of the synovium with frond-like fatty deposition within the knee joint and in the supra patellar recess (Figure 6A). After IV contrast, no appreciable enhancement was noted. Moderate joint effusion was present (Figure 6B). The diagnosis of lipoma arborescence of the left knee was suggested. The patient was treated by open synovectomy of the left knee. A yellowish villous mass (Figure 7) with villous projections on the surface of the synovium (Figure 8) was removed from the suprapatellar pouch and medial and lateral para-patellar recess. Histology revealed infiltration of chronic inflammatory cells and proliferating blood vessels in the

subsynovial fatty tissue. No granuloma, malignancy or haemosiderin pigment was present (Figure 9 and Figure 10). The histological findings established the diagnosis of lipoma arborescens. The post-operative period was uneventful. The patient was discharged and

advised for regular exercise to achieve a full range of motion. The patient was followed 6 months for 1 year and later yearly till the second year. There was no recurrence of swelling, but there was some limitation the left knee joint movement.

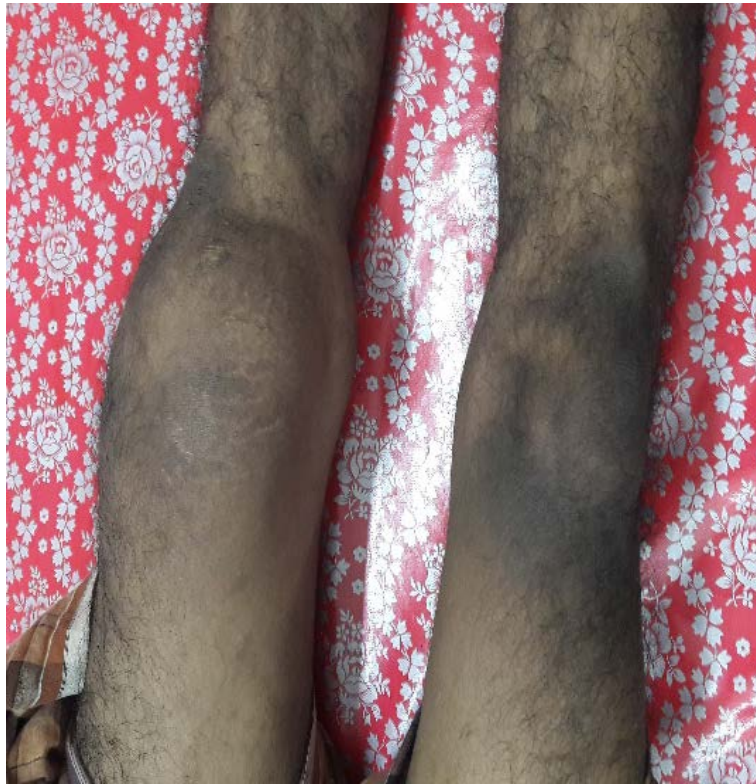

Figure 1. Swollen left knee (suprapatellar space)

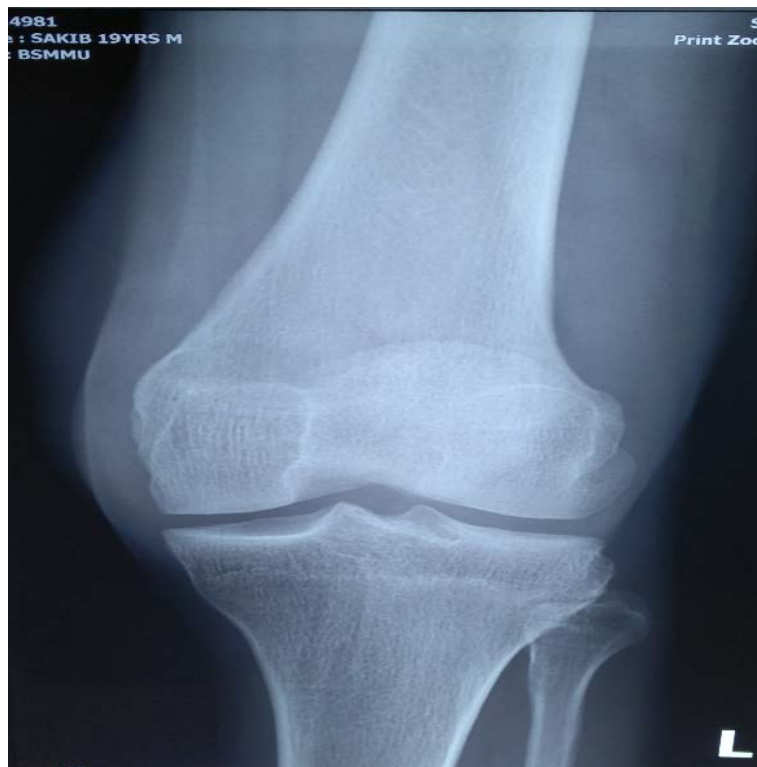

Figure 2. Soft tissue swelling with-preservation of joint space

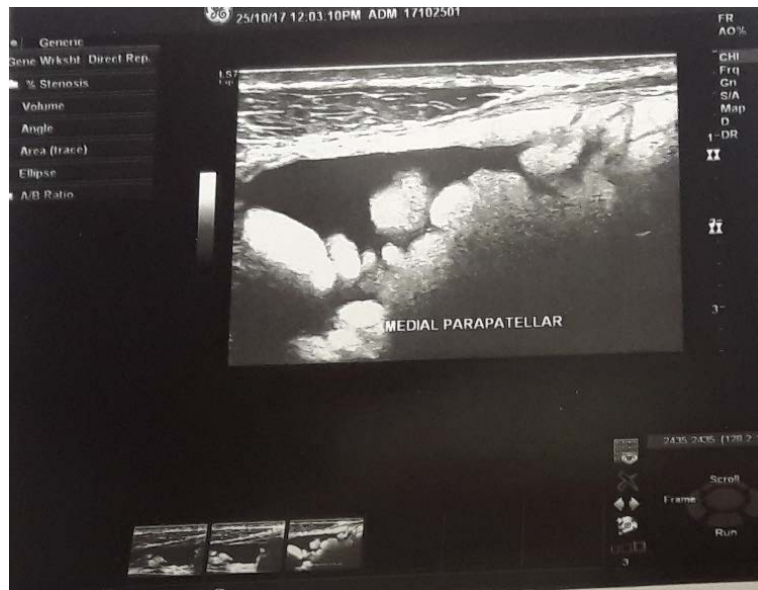

Figure 3. Medial Para patellar

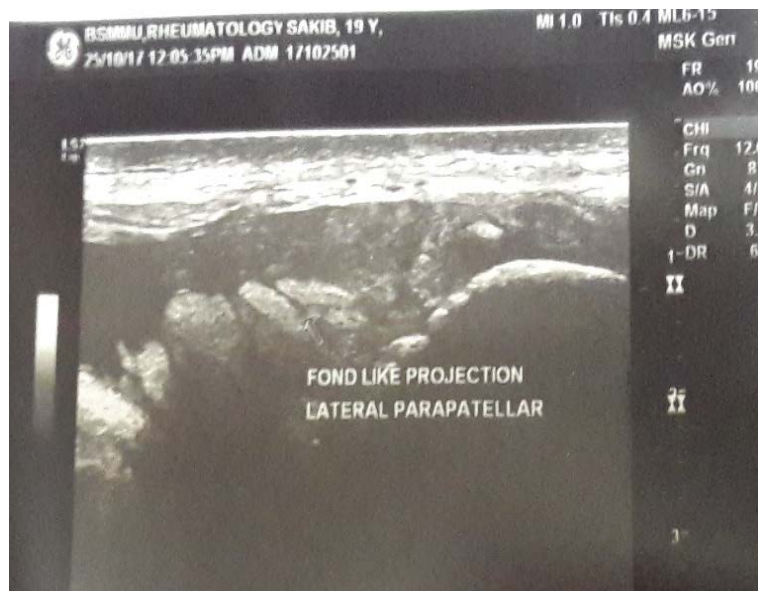

Figure 4. Lateral para patellar

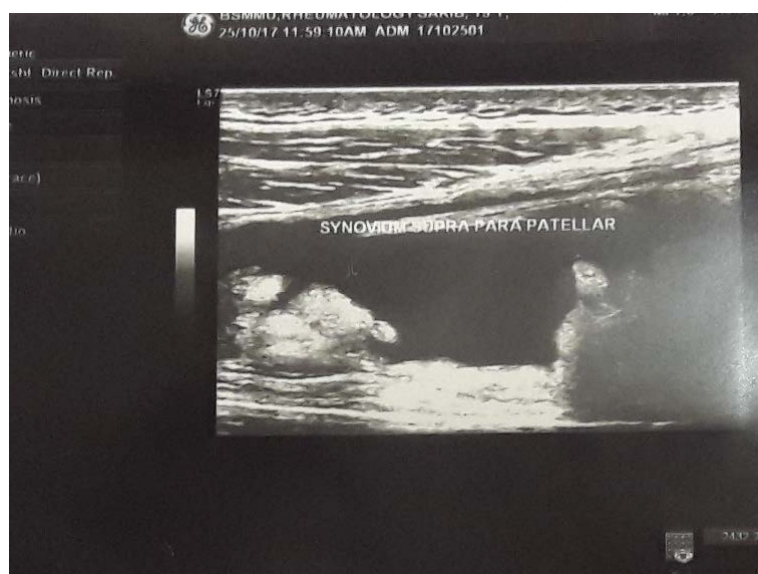
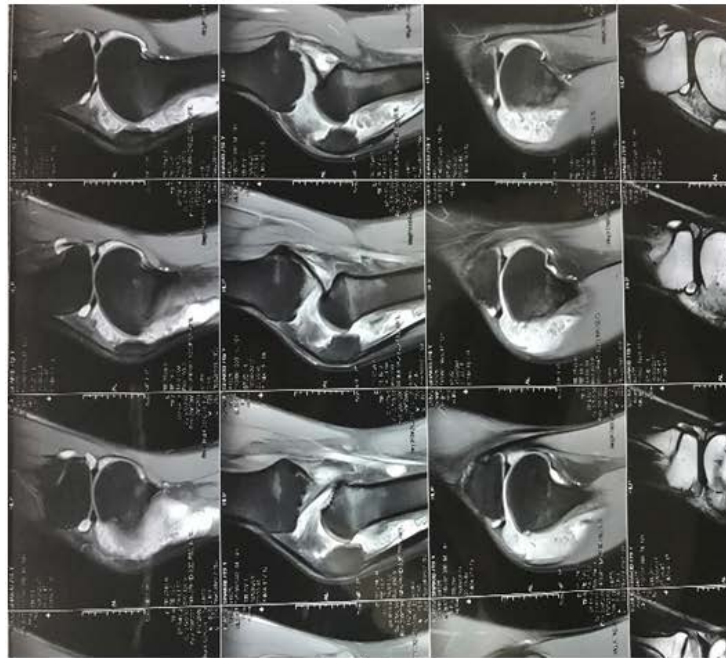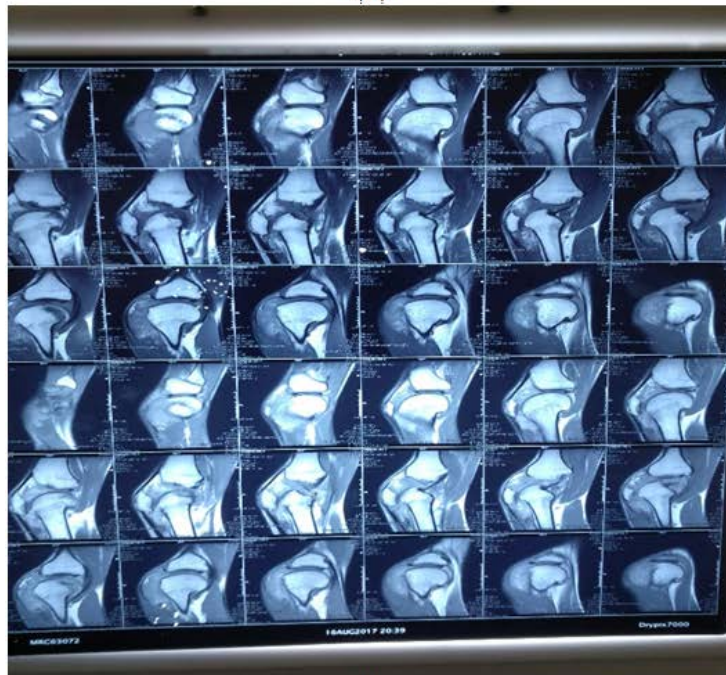


Figure 5. Suprapatellar



(A)



(B)

Figure 6. Arborizing/branching synovial proliferation without significant post-contrast enhancement

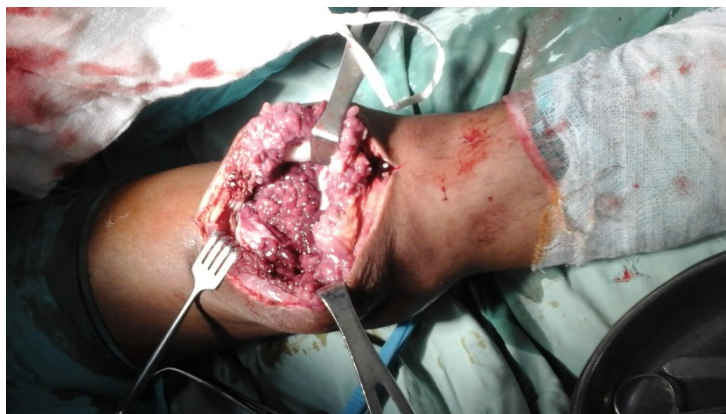

Figure 7. Open Synovectomy

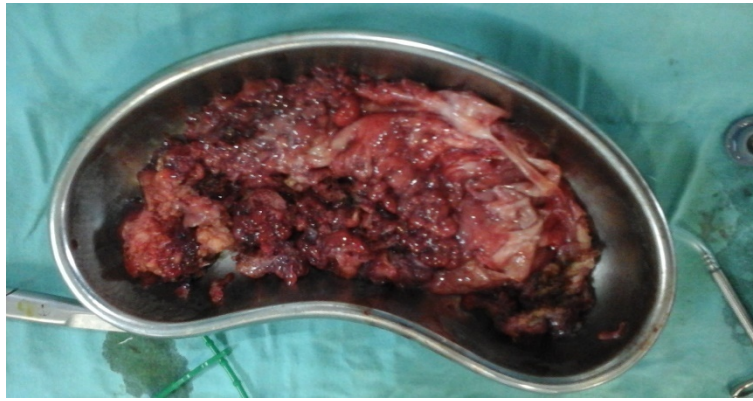

Figure 8. Biopsy specimens

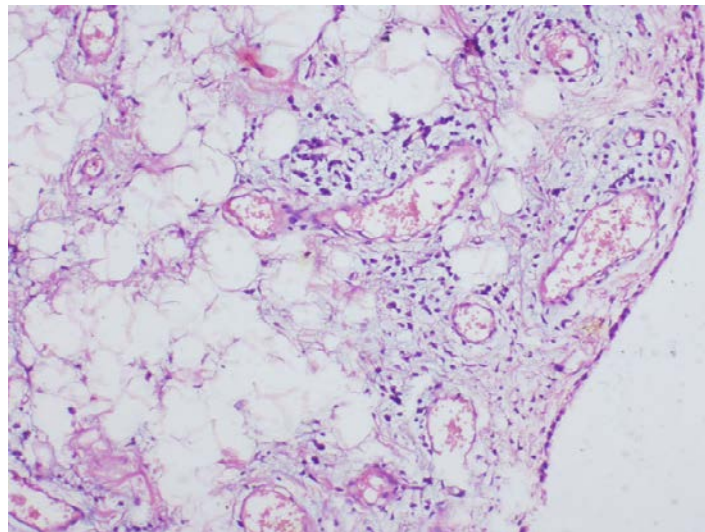


Figure 9. Showing adipose tissue and inflame cells

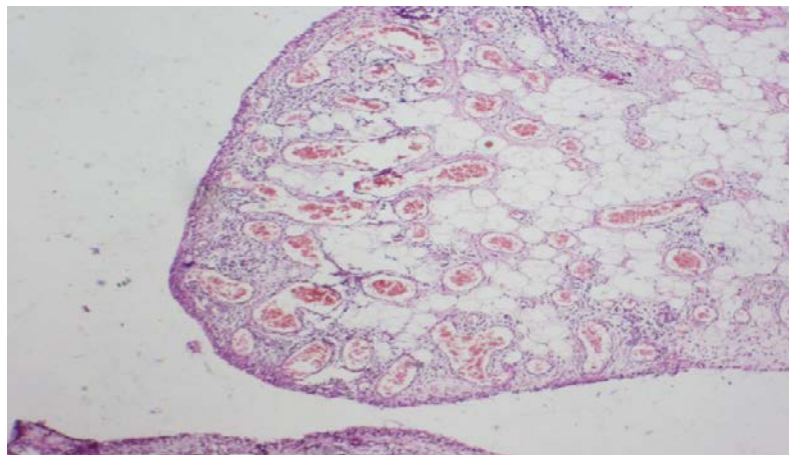


Figure 10. Stromal tissue consists of lobules of mature adipose tissue with chronic inflammatory tissue.

3. Discussion

Lipoma arborescens is an unusual intra-articular benign lesion of the synovium. In 1957 Arzimanoglu [11] published the first case report. Subsequently, approximately 100 cases have been reported [12]. Usually, reports consist of just one case or a small case series during that time, Howe and Wenger described the largest series with 45 lesions in 39 patients. [13] Its etiology and pathogenesis are still not known. A history of trauma is usually present in many patients with LA [14,15]. Diabetes mellitus or

steroid use have also been involved in some cases [13]. Lesions due to either degenerative or inflammatory arthritis are seen quite regularly [16,17,18]. Howe and Wenger [13] reported the presence of arthritic chondral damage at 36 of their 39 patients. Moreover, delay in initiating treatment causes early development of osteoarthritis [19]. Our patient had no history of trauma. The patient develops knee OA during follow up, possibly as a result of the delay in treatment. The clinical differential diagnoses of lipoma arborescens of the knee include pigmented villonodular synovitis, intrarticular

lipoma, synovial chondromatosis, and synovial haemangioma, rheumatoid arthritis, etc. In the pediatric age group, chronic joint effusion and pain can be caused by JIA, vascular malformation, and Behcet syndrome. [20] In our case, these differentials were excluded through the combined use of clinical information, imaging and laboratory studies. MRI is the chosen investigation and can demonstrate different morphological patterns with pathognomonic characteristics [21]. A large frond-like mass arising from the synovium is seen, with signal intensity similar to fat on all pulse sequences [1,22,23] Sub synovial tissue does not enhance after IV administration of contrast medium, but the synovial lining and the joint fluid may demonstrate enhancement, if there is a presence of inflammatory cells [17]. In our case, sagittal, coronal, and axial sequence showed hypertrophy of synovium with frond like a fatty deposition in the suprapatellar pouch and the knee joint with no appreciable contrast enhancement. MRI with IV contrast with gadolinium is immensely useful for diagnosis, but the definite diagnosis can only be established by histological examination, which reveals diffuse replacement of the subsynovial tissue with mature fat cells, causing villous extension of the synovium and inflammatory cells around capillaries [19,24]. LA is a benign tumor. There is no report of malignancy, so some authors consider biopsy is not an essential part of treatment algorithm [25,26,27]. An only a small number of cases with LA reported till now, and the pathology of this entity has not been explained well. We believe that biopsy may be useful in selected cases. Recommended treatment is open synovectomy, and recurrence after surgery is unusual [26]. An arthroscopic synovectomy is also described in recent case reports, with similar rates of recurrence [23,24,28]. Chemical synovectomy with Yttrium has been used to temporarily relieve the symptoms, but not as the conclusive treatment.

4. Conclusion

LA is an uncommon benign lesion, which typically affects knee joints especially the suprapatellar pouch. It should always be considered in the spectrum of differential diagnoses when clinicians deal with chronic painful or painless swelling of a joint. MRI findings are characteristic, and early synovectomy gives the best functional outcome.

Conflicts of Interest

The authors have nothing to disclose.

References

- [1] JC Vilanova., "MR imaging of lipoma arborescens and the associated lesion", skeletal Radiology 32.99 (2003): 504-509.
- [2] K Al-Ismail., et al. "Bilateral lipoma arborescens associated with early osteoarthritis." European Radiology. 12.11 (2002): 2799-2802.
- [3] P Kloen., et al. "Lipoma arborescens of the knee." the journal of Bone and Joint surgery British volume 80.2 (1998): 298-301.
- [4] J Xiao., et al. "Bilateral Knee Lipoma arborescens combined with osteoarthritis in elderly patients." Journal of international medical research 39.4 (2011): 1563-1568
- [5] K Ikushima et al., "Lipoma arborescens of the knee as a possible cause of osteoarthritis." Orthopedics 24.6 (2001): 603-605 01724095919.
- [6] Gaede EA, "A case of synovitis chronicavillosageneralisata", Archive for Orthopedic and Trauma surgery 53 (1961): 315-319.
- [7] Levadoux M, et al. "Lipoma arborescens of the elbow: a case report." Journal of hand surgery 25.3 (2000): 580-584.
- [8] Laorr A et al. "Lipoma arborescens of the shoulder: magnetic resonance imaging findings." L Canadian Association of Radiologists Journal 46.4 (1995): 311-313.
- [9] Napolitano A "Lipoma arborescens of the synovial fluid clinical contribution to a case located at the synovia of the wrist." Progresso Medico 13.4 (1957): 109-118.
- [10] Hubscher O., et al. "Chronic monoarthritis due to lipoma arborescens." Journal of Rheumatology 17.6 (1990): 861-862
- [11] A. Arzimanoglu, "Bilateral arborescent lipoma of the knee", The Journal of Bone and Joint Surgery, vol. 39, no. 4, pp. 976-979, 1957.
- [12] S. Kamaci, M. N. Doral, F. B. Ergen, A. Yucekul, and A. Cil, "Lipoma arborescens of the knee", Knee Surgery, Sports Traumatology, Arthroscopy, vol. 23, no. 8, pp. 2196-2201, 2015.
- [13] B. M. Howe and D. E. Wenger, "Lipoma arborescens: comparison of typical and atypical disease presentations." Clinical Radiology, vol. 68, no. 12, pp. 1220-1226, 2013.
- [14] O. Hubscher, E. Costanza, and B. Elsner, "Chronic monoarthri-tis due to lipoma arborescens." Journal of Rheumatology, vol. 17, no. 6, pp. 861-862, 1990.
- [15] G. Weitzman, "Lipoma arborescens of the knee. Report of a case." The Journal of Bone and Joint Surgery. American Volume, vol. 47, pp. 1030-1033, 1965.
- [16] S. J. Armstrong and I. Watt, "Lipoma arborescens of the knee." British Journal of Radiology, vol. 62, no. 734, pp. 178-180, 1989.
- [17] 17. G. Chaljub and P. R. Johnson, "In vivo MRI characteristics of lipoma arborescens utilizing fat suppression and contrast administration." Journal of Computer Assisted Tomography, vol. 20, no. 1, pp. 85-87, 1996.
- [18] T. Hallel, S. Lew, and M. Bansal, "Villous lipomatous proliferation of the synovial membrane (lipoma arborescens)", Journal of Bone and Joint Surgery—Series A, vol. 70, no. 2, pp. 264-270, 1988.
- [19] L. Natera, P. E. Gelber, J. I. Erquicia, and J. C. Monllau, "Primary lipoma arborescens of the knee may involve the development of early osteoarthritis if prompt synovectomy is not performed", Journal of Orthopaedics and Traumatology, vol. 16, no. 1, pp. 47-53, 2015.
- [20] Ramsay SE, Cairns RA, Cabral DA, Malleson PN, Bray HJ, Petty RE. Knee magnetic resonance imaging in childhood chronic monoarthritis. J Rheumatol. 1999; 26: 2238-43
- [21] J. F Feller, M. Rishi and E.Cc Hughes, "Lipoma arborescens of the Knee: MR demonstration", American journal of Roentgenology, vol. 163, no.1, pp 162-164, 1994.
- [22] E.Y chae H.W. Chung, M.J. Shin and S.H. Lee, "Lipoma arborescens of the glenohumeral jointcausing bone eerosion MRI features with gadolinium enhancement", Skeletal radiology, vol.38, no.8, pp. 815-818, 2009.
- [23] R. soler, E. Rodriguez, A. Bargiela and M. Da Riba "Lipoma arborescens of the knee: MR characteristics in 13 joints", Journal of computer Assisted Tomography, vol.22.no.4, pp 605-609,1998
- [24] D. Azzouz, R. Tekaya, W. Hamdi and M. MontacerKohir, "Lipoma Arborescens of the Knee", Journal of clinical Rheumatology, vol. 14, no.6, pp. 370-372, 200.
- [25] R. E. Blais, R. F. Laprade, G. Chaljub and A. Adesokan, "The arthroscopic appearance of lipoma arborescens of the knee", Arthroscopy: The Journal of Arthroscopic and Related surgery vol. 11, no.5, pp.623-627, 1995.
- [26] M. Franco, J. M Puch, M. J. Carayon, D. Bortolotti, L. Albano and A. Lallemand, "Lipoma Arborescens of the knee": report of a case managed by arthroscopic synovectomy, Joint Bone Spine, vol. 71, no.1, pp. 73-75, 2004.

- [27] P. B. Patil, M.G. Kamalpur, S. K. Joshi, S.K. Dasarand R. V. rao "Lipoma arborescens of Knee Joint: role of imaging" *Journal of Radiology case Reports*, vol.5, no.11, pp 17-25, 2011.
- [28] J. B. Sola and R.W. Wright, Arthroscopic treatment of lipoma arborescens of the knee A case report *The Journal of Bone and Joint Surgery- American volume*, vol.80, no.1, pp.99-103, 1998.



© The Author(s) 2021. This article is an open access article distributed under the terms and conditions of the Creative Commons Attribution (CC BY) license (<http://creativecommons.org/licenses/by/4.0/>).