

Acute Decompensated Heart Failure in a Young Patient Infected with COVID-19

Gil Hevroni, Diego Cepeda-Mora, Zachary Mostel, Luis Lugo, Samy I McFarlane*

Department of Internal Medicine, SUNY-Downstate Health Science University, Brooklyn, New York, USA11203

*Corresponding author: smcfarlane@downstate.edu

Received December 26, 2020; Revised January 03, 2021; Accepted January 13, 2021

Abstract While patients with severe COVID-19 infection often have cardiovascular comorbidities, there is a paucity of literature outlining the potential of this novel coronavirus to trigger acute decompensated heart failure. To date, there is limited understanding of the pathophysiology of heart failure in COVID-19; some suggest decompensation is a result of an incident episode of myocarditis as seen with other respiratory viruses. Here we present a case of a 25 year old man with no known cardiovascular disease, who presented with acute decompensated heart failure found to have an ejection fraction of ten percent in the setting of COVID-19 infection and subsequently had multiple admissions for heart failure decompensation. An extensive work-up was performed and ruled out cardiovascular and rheumatological causes of heart failure, making COVID-19 infection a plausible etiologic factor for heart failure.

Keywords: heart failure, COVID-19, SARS-CoV-2, myocarditis, cardiovascular disease

Cite This Article: Gil Hevroni, Diego Cepeda-Mora, Zachary Mostel, Luis Lugo, and Samy I McFarlane, "Acute Decompensated Heart Failure in a Young Patient Infected with COVID-19." *American Journal of Medical Case Reports*, vol. 9, no. 3 (2021): 163-166. doi: 10.12691/ajmcr-9-3-8.

1. Introduction

Coronavirus disease 2019 (COVID-19) is at the center of a global pandemic caused by severe acute respiratory syndrome coronavirus-2 (SARS-CoV-2); it has resulted in significant morbidity and mortality around the world [1]. Initially described as a respiratory illness, COVID-19 is now recognized as affecting multiple systems. The cardiovascular sequelae of COVID-19 remain poorly understood, with heart failure diagnosed at different stages of the disease. Moreover, new or existing heart failure in the setting of COVID-19 presents unique challenges that can complicate presentation, management, and prognosis [2].

Cardiovascular disease is a common comorbidity among patients with symptomatic COVID-19 infection as was seen with previous outbreaks of other coronaviruses, namely, the severe acute respiratory syndrome coronavirus (SARS-CoV) outbreak in 2002 and the Middle East respiratory syndrome coronavirus (MERS-CoV) outbreak in 2012. For SARS and MERS, the coexistence of hypertension ranges from 35 to 57 percent, coronary artery disease ranges from 10 to 17 percent, and congestive heart failure ranges from six to seven percent [3,4,5]. One case series found a 42.9 percent prevalence of heart failure among patients with COVID-19 admitted to an intensive care unit [6].

Recent reviews of the literature have divided the cardiac manifestations of COVID-19 into either primary

or secondary syndromes [2]. Primary syndromes include arrhythmia, acute coronary syndrome, and myocarditis. Secondary syndromes are largely a consequence of the systemic inflammatory syndrome and can manifest as acute myocardial injury with biomarker elevation and subsequent congestive heart failure [2].

The development of new-onset heart failure has been observed with COVID-19 infection [6]. A retrospective study from Wuhan, China reported congestive heart failure as an outcome in 23 percent of infected patients, with higher prevalence among patients with baseline comorbidities (i.e. hypertension, diabetes, and coronary artery disease) and patients who did not survive hospitalization (52% of non-survivors vs. 12% of survivors) [9]. A case series by Arentz et al found that seven out of 21 critically ill patients developed cardiomyopathy during their stay in the intensive care unit. The exact cause of ventricular failure in COVID-19 remains undetermined as this phenomenon is fairly new and has a variable presentation [7]. As mentioned above, the majority of cases of heart failure occur among patients with COVID-19 that require intensive care management. Here we present a case of a young patient with a history of asthma, who was diagnosed with heart failure and pneumonia during the same hospitalization and was found to be positive for COVID-19.

2. Case Presentation

A 25-year-old male with a past medical history of asthma and obesity had multiple admissions to the

hospital for new-onset heart failure between June and October of 2020. In June he was admitted to an outside hospital for shortness of breath, cough, hemoptysis, and diffuse myalgias with normal vital signs. His physical exam was remarkable for clinical fluid overload and lab work significant for elevated brain natriuretic peptide (BNP) and a SARS-CoV-2 PCR positive. He had extensive imaging including chest x-ray, echocardiogram, CT of the chest with contrast, and right heart catheterization. The echocardiogram revealed an ejection fraction of 10 percent with global hypokinesis; chest x-ray revealed bilateral infiltrates suggestive of fluid overload and/or pneumonia; CT of the chest was negative for pulmonary embolism; and the right heart catheterization revealed increased right-sided heart pressures with no evidence of ischemia. He was treated for acute decompensated heart failure (ADHF) and discharged on furosemide, spironolactone, and sacubitril-valsartan, and was provided a life vest.

One month later, the patient was admitted to the intensive care unit for similar but more severe symptoms. He was tachypneic and hypoxic with an oxygen saturation of 85 percent, and had subsequent improvement of his respiratory symptoms on bilevel positive airway pressure (BiPAP). His chest-x ray revealed bilateral ground-glass opacities, electrocardiogram (EKG) showed sinus tachycardia, and a repeat echocardiogram demonstrated severe hypokinesis with an ejection fraction of 20 percent (Figure 1). On exam, he appeared hypervolemic with jugular venous distension, bilateral coarse lung crackles, and pitting edema. Labs were notable for BNP >1500 and a white blood cell count (WBC) of 15,000. He was treated with furosemide, piperacillin-tazobactam, azithromycin, and supplemental oxygen for ADHF and concurrent pneumonia. His symptoms improved and he was gradually weaned off oxygen. SARS-CoV-2 PCR, legionella antigen (urine), and streptococcal antigen (urine) were all negative. A bronchoscopy was planned; however, the patient declined the procedure. He was stabilized and discharged on amoxicillin-clavulanate, azithromycin, metoprolol, furosemide, spironolactone, sacubitril-valsartan, and canagliflozin with instructions to follow up with cardiology and pulmonology as an outpatient.

Unfortunately, the patient was lost to follow-up and readmitted one month later for cough and pleuritic chest pain. He was found to have a troponin of 1.02, BNP > 2000, EKG with nonspecific ST segment changes, and an overall clinical picture suggestive of non-ST segment elevation myocardial infarction (NSTEMI). The patient refused a diagnostic/therapeutic cardiac catheterization. Chest x-ray showed bilateral unresolved ground-glass opacities and he was admitted for NSTEMI and pneumonia. Repeat echocardiogram was relatively unchanged from the study performed during his prior admission (Figure 2). Pulmonology was consulted and performed a bronchoscopy; the study ruled out both infectious and inflammatory processes. Rheumatology was consulted and work-up revealed low titers of ANA (1:80) and anti-dsDNA antibodies (1:50). He was treated for ADHF, NSTEMI, and refractory pneumonia, and he was discharged with instructions to follow up

with cardiology, pulmonology and rheumatology as an outpatient. He was readmitted two months later for a fourth time with cough, dyspnea on exertion, and generalized fatigue. Rheumatology, cardiology, and pulmonology were all consulted for evaluation and further work-up of non-ischemic cardiomyopathy with multiple episodes of exacerbation. Rheumatology concluded that his heart failure was unlikely to be of autoimmune etiology given his low ANA titers, and lack of other systemic, rheumatological symptoms. He was again managed with diuresis for ADHF and cardiology planned for placement of an automatic implantable cardioverter defibrillator (AICD). However, the patient opted to continue with the life vest and to pursue medical management. He was discharged on metoprolol, furosemide, spironolactone, sacubitril-valsartan and provided with appointments for cardiology and primary care as an outpatient.

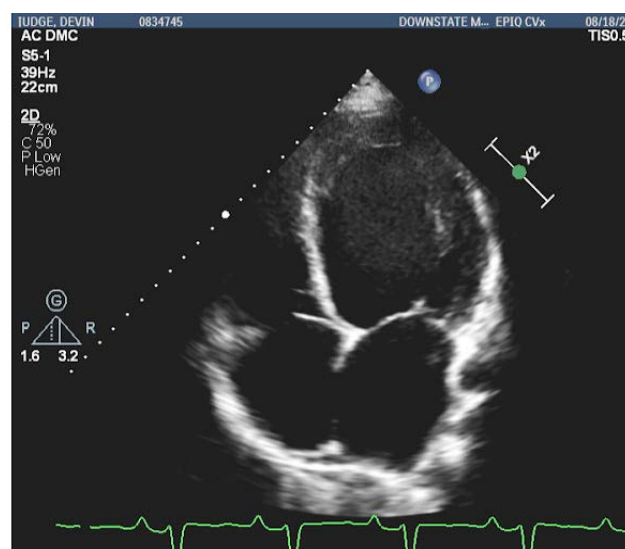


Figure 1. 2D Echocardiogram showing left ventricular dilation and normal wall thickness

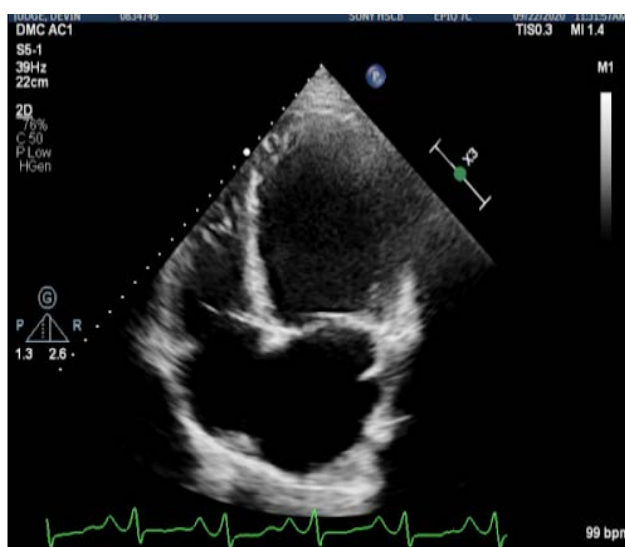


Figure 2. 2D Echocardiogram showing left ventricular dilation and normal wall thickness

Echocardiographic measurements:

M-mode measurements

Left ventricle		Normal
LVID ed	75.5 mm	37-56
LVID es	69.5 mm	--
FS	7.95 %	29-45
Vol ed, Teichholz	303 ml	--
Vol es, Teichholz	251 ml	--
Stroke vol, Teichholz	52 ml	--
EF, Teichholz	17 %	64-83

2D mode measurements

Aorta		Normal
AoR Diam; Mean (2D)	26 mm	
Left Ventricle		Normal
IVSd (2D)	7.11 mm	<12 mm
LVIDd (2D)	76.9 mm	
LVPWd (2D)	7.85 mm	

3. Discussion

COVID-19 is a global pandemic and a public health emergency that was first reported in December 2019 in Wuhan, Hubei Province, China. It is caused by the novel enveloped RNA beta-coronavirus severe acute respiratory syndrome coronavirus-2 (SARS-CoV-2) [10]. The presentation can range from asymptomatic carrier to severe respiratory failure. Mild symptoms include cough, sore throat, changes in taste and smell. Severe symptoms include shortness of breath, fever, fatigue, and complications related to pneumonia, acute respiratory distress syndrome, and coagulopathy disorders [10].

Cardiac involvement has been reported in hospitalized patients with COVID-2019 as evidenced by electrocardiographic changes, elevation in cardiac biomarkers and compromise in cardiac function by echocardiography and other imaging modalities [11]. The mechanism of injury may be a result of ischemia secondary to coronary disease, arrhythmia, sepsis-related cardiomyopathy, pulmonary embolism, myocardial infection or injury secondary to a systemic inflammatory response [2,11].

Myocarditis is an inflammatory disease of the heart most commonly caused by a viral infection; it is characterized by the presence of inflammatory cells and myocardial injury. Several mechanisms have been proposed in the pathophysiology of this entity, including an unbalanced response between type 1 and type 2 T helper (Th) cells, which is postulated as a trigger for a "cytokine storm" and activation of proinflammatory markers like interleukin-6 (IL-6) [12]. This inflammatory cascade leads to migration and infiltration of macrophages that result in direct and indirect myocardial injury, necrosis and remodeling. Human coronaviruses like MERS-CoV and SARS-CoV have been reported as etiologies of myocarditis [13,14]. SARS-CoV-2 enters human cells by binding with its spike protein to the angiotensin-converting enzyme-2 (ACE2) membrane protein. This receptor is widely expressed in different tissues, including the columnar epithelia of the respiratory tract, type II pneumocytes, gut endothelia, kidney parenchyma, and cardiac myocytes [15]. Therefore, it is possible for SARS-CoV-2 to infect cardiac tissue.

Cases of clinical myocarditis associated with COVID-19 have been suspected and reported in the literature but it has been difficult to confirm direct involvement by SARS-CoV-2. The American Heart Association (AHA) and the European Society of Cardiology (ESC) recommend endomyocardial biopsy

with histopathology, immunohistochemistry and viral PCR studies as the gold standard for definitive diagnosis of viral myocarditis, but these societies recognize the limitations of these studies in clinical practice [16]. Non-invasive imaging techniques like cardiac magnetic resonance (CMR), cardiac computed tomography, and echocardiography are useful in making the diagnosis of myocarditis [16,17]. Current recommendations for the diagnosis of suspected myocarditis require a combination of clinical presentation, electrocardiographic changes, elevation of cardiac markers, evidence of functional and structural abnormalities, and tissue characterization by cardiac imaging. Most of the documented cases in the literature are based on the clinical presentation, risk factors, time association with a recent viral illness and image-based evidence of cardiac involvement [17]. Linder et al examined 39 autopsies of patients with COVID-19 with pneumonia as the cause of death in 89.7 percent of them. Although histopathological studies did not meet criteria for acute myocarditis, the viral genome was present in the heart of 61.5 percent of patients, with localization in the interstitial cells and macrophages infiltrating myocardial tissue rather than the myocytes [18]. Notably, hearts infected with the virus were found to have increased activity of proinflammatory markers. These findings suggest an association between COVID-19 and myocardial injury.

Several factors in this case were highly suggestive of COVID-19 infection as the etiology for heart failure, including the patient's young age, lack of risk factors for cardiovascular disease, non-contributory family history, presentation of ADHF, echocardiogram with evidence of reduced ejection fraction and severe hypokinesis, SARS-CoV-2 PCR positivity, and a work-up that was negative for cardiovascular and autoimmune disorders. It remains unclear whether the heart failure is due to viral myocarditis, inflammatory processes triggered by the viral infection, or direct injury by the virus to the myocardium. Additional testing—including CMR, cardiac CT, and biopsy—when available, may be helpful in making the diagnosis and understanding the pathophysiology of this condition.

4. Conclusion

Cardiac involvement in patients with COVID-19 has been reported. The clinical presentation of COVID-19-associated myocarditis is variable among patients; it can range from mild symptoms like fatigue, dyspnea, or palpitations to

more severe symptoms like chest pain, decreased exercise tolerance, and acute onset heart failure or even cardiogenic shock. The exact mechanism and long-term impact of COVID-19 cardiac disease remains unknown. Future research will explore therapies that can impact morbidity and mortality. Further investigations are warranted to elucidate the nature of the disease and develop target therapies.

References

- [1] Nishiga M, Wang DW, Han Y, Lewis DB, Wu JC. COVID-19 and cardiovascular disease: from basic mechanisms to clinical perspectives. *Nat Rev Cardiol*. 2020 Sep; 17(9): 543-558.
- [2] Ranard, Lauren S., et al. "Approach to Acute Cardiovascular Complications in COVID-19 Infection." *Circulation: Heart Failure*, vol. 13, no. 7, 2020.
- [3] Badawi A, Ryoo SG. Prevalence of comorbidities in the Middle East respiratory syndrome coronavirus (MERS-CoV): a systematic review and meta-analysis. *Int J Infect Dis*. 2016; 49: 129-133.
- [4] Zheng YY, Ma YT, Zhang JY, Xie X. Reply to: 'Interaction between RAAS inhibitors and ACE2 in the context of COVID-19.' *Nat Rev Cardiol*. 2020; 17: 313-314.
- [5] Goyal P, Choi JJ, Pinheiro LC, Schenck EJ, Chen R, Jabri A, Satlin MJ, Campion TR, Nahid M, Ringel JB. Clinical characteristics of Covid-19 in New York City. *N Engl J Med*. 2020; 382:2372-2374.
- [6] Petrilli CM, Jones SA, Yang J, Rajagopalan H, O'Donnell LF, Chernyak Y, Tobin K, Cerfolio RJ, Francois F, Horwitz LI. Factors associated with hospitalization and critical illness among 4,103 patients with COVID-19 disease in New York City. *medRxiv*.
- [7] Arentz M, Yim E, Klaff L, Lokhandwala S, Riedo FX, Chong M, Lee M. Characteristics and outcomes of 21 critically ill patients with COVID-19 in Washington State. *JAMA*. 2020; 323: 1612-1614.
- [8] Ranard LS, Fried JA, Abdalla M, Anstey DE, Givens RC, Kumaraiah D, Kodali SK, Takeda K, Karpaliotis D, Rabbani LE, Sayer G, Kirtane AJ, Leon MB, Schwartz A, Uriel N, Masoumi A. Approach to Acute Cardiovascular Complications in COVID-19 Infection. *Circ Heart Fail*. 2020 Jul; 13(7): e007220.
- [9] Zhou F, Yu T, Du R, Fan G, Liu Y, Liu Z, Xiang J, Wang Y, Song B, Gu X, et al.. Clinical course and risk factors for mortality of adult inpatients with COVID-19 in Wuhan, China: a retrospective cohort study. *Lancet*. 2020; 295: 1054-1062.
- [10] Huang C, Wang Y, Li X, et al. Clinical features of patients infected with 2019 novel coronavirus in Wuhan, China. *Lancet*. 2020; 395(10223): 497-506.
- [11] Zhyvotovska A, Yusupov D, Foronjy R, Nakeshbandi M, McFarlane SI, Salifu M. Insights into Potential Mechanisms of Injury and Treatment Targets in COVID-19, SARS-Cov-2 Infection. *Int J Clin Res Trials*. 2020; 5(1): 147.
- [12] Rizzo P, Vieceli Dalla Sega F, Fortini F, Marracino L, Rapezzi C, Ferrari R. COVID-19 in the heart and the lungs: could we "Notch" the inflammatory storm? *Basic Res Cardiol*. 2020 Apr 9; 115(3): 31.
- [13] Riski H, Hovi T, Frick MH. Carditis associated with coronavirus infection. *Lancet* 1980; 2: 100-101.
- [14] Alhagbani T. Acute myocarditis associated with novel Middle East respiratory syndrome coronavirus. *Ann Saudi Med* 2016; 36: 78-80.
- [15] Gheblawi M, Wang K, Viveiros A, Nguyen Q, Zhong J-C, Turner AJ, et al. Angiotensin-Converting Enzyme 2: SARS-CoV-2 Receptor and Regulator of the Renin-Angiotensin System: Celebrating the 20th Anniversary of the Discovery of ACE2. *Circ Res*. 2020 May 8; 126(10): 1456-74.
- [16] Biesbroek PS, Beek AM, Germans T, Niessen HW, van Rossum AC. Diagnosis of myocarditis: Current state and future perspectives. *Int J Cardiol*. 2015 Jul 15; 191: 211-9.
- [17] Alida L. P. Caforio, Sabine Pankuweit, et al, Current state of knowledge on aetiology, diagnosis, management, and therapy of myocarditis: a position statement of the European Society of Cardiology Working Group on Myocardial and Pericardial Diseases, *European Heart Journal*, Volume 34, Issue 33, 1 September 2013, Pages 2636-2648,
- [18] Lindner D, Fitzek A, Bräuninger H, et al. Association of cardiac infection with SARS-CoV-2 in confirmed COVID-19 autopsy cases. *JAMA Cardiol*. Published online July 27, 2020.

