

Aborted Sudden Cardiac Death from Vasospastic-Induced Ventricular Fibrillation with Normal Coronary Angiography: A Case Report and Review of the Literature

Krunal H. Patel¹, Andrew V. Doodnauth¹, Julian C. Dunkley²,
Jennifer Abrams¹, Samy I. McFarlane^{1,*}

¹Department of Internal Medicine, State University of New York, Downstate -Health Science University, Brooklyn, NY, USA - 11203

²Department of Internal Medicine, NYC + HHC Jacobi Medical Center, 1400 Pelham Pkwy S, Bronx, NY, U.S.A- 10461

*Corresponding author: smcfarlane@downstate.edu

Received October 15, 2020; Revised November 16, 2020; Accepted November 25, 2020

Abstract Coronary artery vasospasms have been known to cause episodic angina pectoris, along with ST-T wave changes. In addition, vasospasm if prolonged can cause myocardial ischemia leading to malignant arrhythmias such as ventricular fibrillation and ventricular tachycardia resulting in sudden cardiac death (SCD). Treatment for this disorder can be challenging. Current data is lacking on the management of patients receiving appropriate vasodilator medications who present with Ventricular Fibrillation (VFib) as a consequence of coronary artery vasospasms. We present a case of a 71-year-old man who was hospitalized due to recurrent episodes of coronary vasospasms leading to acute decompensation and VFib with subsequent resuscitation while undergoing cardiac catheterization. We also provide review of the literature and updates on the current guidelines from the American Heart Association on this potentially life-threatening disorder.

Keywords: coronary vasospasm, sudden cardiac death, variant angina, ventricular fibrillation, Prinzmetal angina

Cite This Article: Krunal H. Patel, Andrew V. Doodnauth, Julian C. Dunkley, Jennifer Abrams, and Samy I. McFarlane, "Aborted Sudden Cardiac Death from Vasospastic-Induced Ventricular Fibrillation with Normal Coronary Angiography: A Case Report and Review of the Literature." *American Journal of Medical Case Reports*, vol. 9, no. 1 (2021): 78-82. doi: 10.12691/ajmcr-9-1-20.

1. Introduction

Coronary artery vasospasm also known as Prinzmetal Angina and variant angina was first described by Dr. Myron Prinzmetal in 1959 as a "variant form of angina pectoris." [1]. Since this first description of coronary artery vasospasm by Dr. Prinzmetal we have come to understand is not a simple variation of angina pectoris, but rather a multifactorial disease that has the potential to cause life-threatening arrhythmias. Coronary artery spasms are known to cause transient vessel occlusion leading to symptoms of acute coronary syndrome (ACS) [2,3,4,5]. However, there is limited data on coronary vasospasms causing lethal arrhythmias resulting in SCD. Ventricular fibrillation secondary to coronary artery vasospasm is a well-known complication documented in the medical literature. Case reports involving cardiac arrest due to vasospasms in patients with non-hemodynamically significant coronary artery disease however are rare [6,7]. Coronary artery spasms are primarily medically treated with vasodilatory medications and in rare circumstances medical therapy can fail, resulting in sudden cardiac death.

One prospective study of 733 patients with acute coronary syndrome who underwent cardiac catheterization showed 186 of these patients had no hemodynamically significant coronary artery disease [8]. Additionally, 6 of these patients had hemodynamically insignificant coronary arteries and later went onto develop ventricular arrhythmias [8]. It was speculated that these patients with no hemodynamically significant CAD likely suffered from coronary artery spasms.

As more patients receive coronary angiography, we are beginning to see coronary vasospasm as one end of a spectrum which also includes myocardial infarction, ventricular arrhythmias, and sudden cardiac death [9,10]. We are also beginning to find coronary vasospasms in patients with variable degrees of coronary atherosclerosis and ischemic heart disease as well, showing that many different cohorts are susceptible to vasospasm, and is likely more prevalent than initially suspected [11]. In the ACOVA study, which involved 304 patients, nearly 50% of patients with a diagnosis of stable angina with angiographically normal coronary arteriograms [11]. Of this group, two thirds had abnormal coronary vasospasm when provocative testing was performed, suggesting coronary vasospasm is not only seen in variant angina but

also in patients lacking classical variant anginal symptoms [11]. Here we will present one such case of a 71-year-old gentleman with a history of stable angina who presented with unstable anginal chest pain, and while preparing for angiography went into Ventricular Fibrillation.

2. Case Presentation

71-year-old male with a past medical history of hypertension, diabetes mellitus type II, and history of Prinzmetal Angina who presented to the emergency room with substernal chest pain for 2 hours that was mild to moderate in intensity, non-radiating, and similar to his previous episodes of variant angina. He would normally take sublingual nitroglycerin tablets when experiencing angina but he did not have access to his medication at this time. Patient is compliant with his calcium channel blocker (Diltiazem 120 mg daily) and Metformin 500mg twice a day and reported no shortness of breath, palpitations, cough, fever, chills, abdominal pain, nausea, or vomiting. Patient's review of systems was negative except for the aforementioned retrosternal chest pain. His pain subsided upon receiving sublingual nitroglycerin by EMS personnel, electrocardiogram (EKG) in the field showed normal sinus rhythm (NSR) with no ST-T wave changes.

Upon arrival to the emergency department (ED), he was hemodynamically stable. Initial lab studies showed a normal complete blood count, comprehensive metabolic panel, and troponin of 0.022 (Table 1). Chest X-ray was unremarkable. Initial EKG in the ED revealed NSR with no ST-T wave changes (Figure 1). However, approximately 1 hour later the patient was noted to be diaphoretic and complaining of chest discomfort not relieved by nitroglycerin. Repeat EKG revealed ST elevations in the inferior leads (II, III, and aVF (Figure 2). Patient was

given dual antiplatelets and was transported to a cardiac catheterization lab for further intervention.

Table 1.

| Lab Values on Presentation | |
|----------------------------|---------------------|
| Hgb | 9.7 g/dL |
| HCT | 30.1% |
| WBC | $7 \times 10^9/L$ |
| PLT | $281 \times 10^9/L$ |
| Na | 134 mmol/L |
| Cl | 101 mmol/L |
| K | 4.1 mmol/L |
| CO2 | 28 mmol/L |
| BUN | 18 mg/dL |
| Cr | 0.7 mg/dL |
| Glucose | 114 mg/dL |
| Troponin | 0.022 |

While being transferred, he became unresponsive and sustained a cardiac arrest. His rhythm strip on the cardiac monitor showed ventricular fibrillation (Figure 3). EKG in Figure 3 shows time of defibrillation (arrow) resulting in return of spontaneous circulation after 2 minutes of CPR. He was found to have symptomatic bradycardia with a heart rate in the 30s at which point a trans-venous pacemaker was inserted to maintain perfusion. Emergent cardiac catheterization was performed through right femoral approach which revealed non-obstructive coronary artery disease (Figure 4). Automated intra-cardiac defibrillator was placed prior to his discharge. Symptomatic bradycardia had resolved as well prior to his discharge not requiring pacing. He was sent home on isosorbide mononitrate daily and long-acting diltiazem daily as well, which was titrated to his maximally tolerated doses. Patient was later lost to follow up, unknown if the patient had additional episodes after discharge.

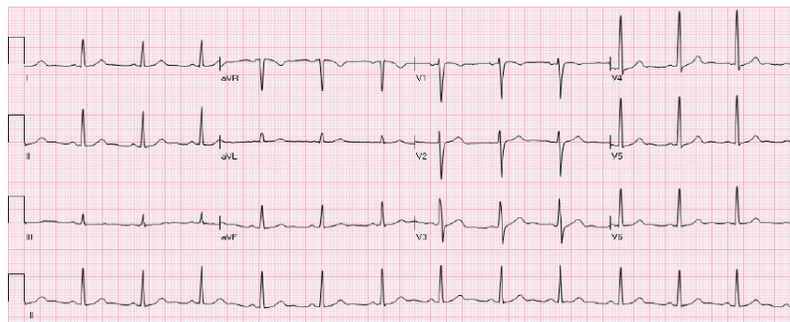


Figure 1. Admission EKG shows normal sinus rhythm with no ST-T wave changes, Q waves, or T wave Inversions

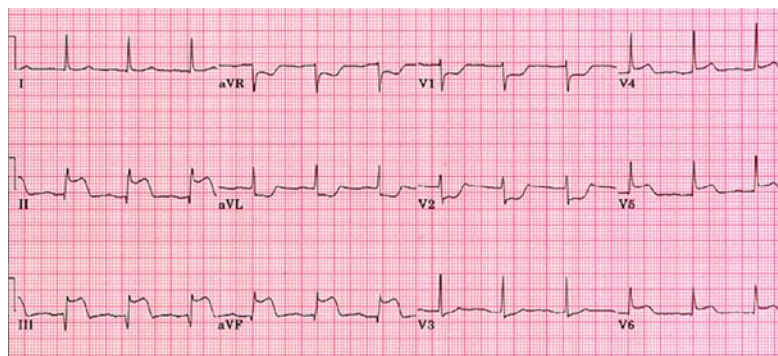


Figure 2. EKG at time of evolving chest pain prior to transport to catheterization lab




Figure 3. EKG at time of decompensations shows ventricular fibrillation. Arrow represents time of defibrillation and subsequent return of spontaneous circulation

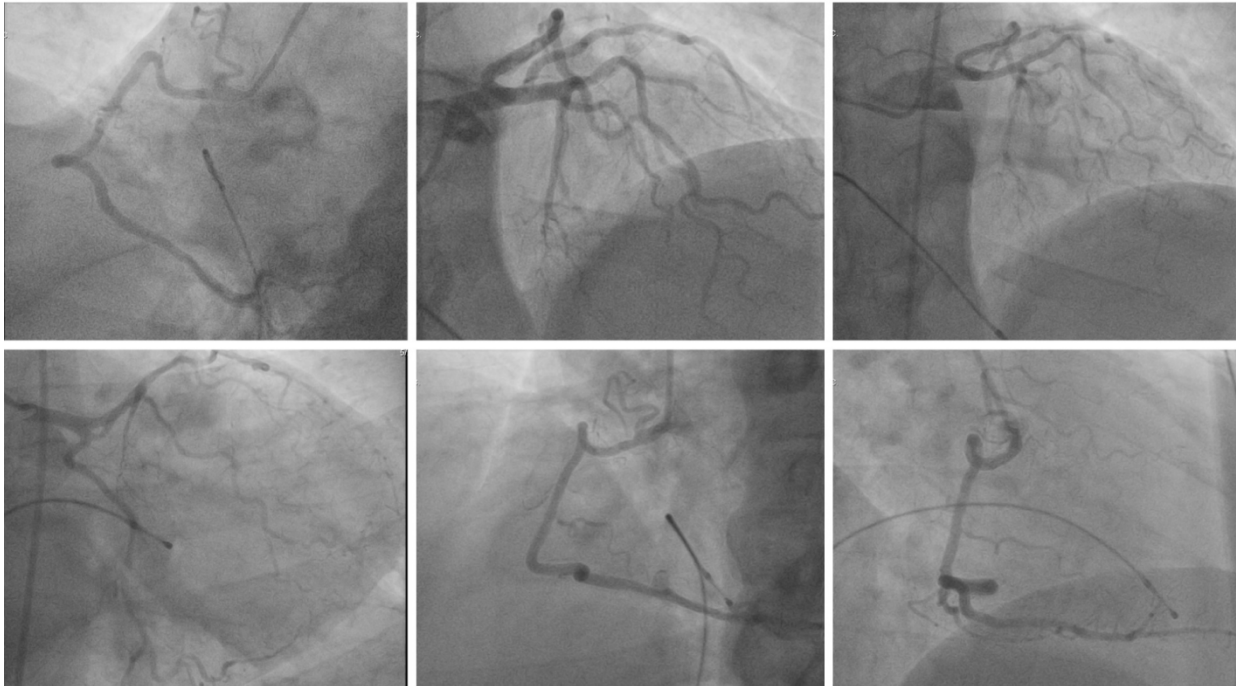


Figure 4. Coronary angiogram after return of spontaneous consciousness shows no significant coronary artery stenosis

3. Discussion

When Dr. Prinzmetal described variant angina in 1959, the effects coronary vasospasm could have on the heart were poorly understood. As it was in this case report, there have been numerous reports and studies completed which show the deleterious effects of coronary vasospasms. It is now well understood that coronary vasospasms play an important role in the pathogenesis of not only variant angina, but also acute myocardial infarctions, unstable angina, atrioventricular block, and just as in this case, aborted sudden cardiac death [12,13]. Variant angina is only one end of the wide spectrum that encompasses myocardial ischemia and its endpoints. As more reports, prospective studies, and provocative testing are done it is becoming clear that coronary artery spasms are not just responsible for variant angina but also play a role in myocardial infarction, malignant arrhythmias such as ventricular fibrillation, and sudden cardiac death [14,15].

In the United States, it is suspected that coronary artery vasospasms are greatly underdiagnosed due to the lack of provocative testing done in patients with anginal pain. Countries within Asia such as Japan and Korea who recognize the lethality vasospasms may have, perform provocative testing far more frequently. It has been reported that almost 40 - 50% of patients who presented with anginal pain have angiographic evidence of vasospasm and 57% in patients with ACS [16]. When coronary

vasospasms are appropriately investigated, its incidence rate appears to be much higher than what was once thought.

Calcium channel blockers are first-line agents for vasospastic angina. Calcium channel blockers (CCB) serve as maintenance and preventative therapy for future vasospastic attacks. CCB serves to promote vasodilation and prevent coronary vasoconstriction seen in variant angina. Currently, the drugs of choice are Diltiazem and Amlodipine. Diltiazem has been reported to be as high as 960mg daily in patients with refractory symptoms. Nifedipine is used to a lesser extent due to the side effects of hypotension and reflex tachycardia seen with the higher doses that these patients usually require [17]. Patients who do not have an adequate response with CCB can be started on long acting nitrates such as isosorbide mononitrate [18]. Additionally, sublingual nitroglycerin can be used as needed as well. In addition to vasodilatory medications, statins have been shown to greatly reduce the frequency of episodes as well. Fluvastatin was studied in an open trial consisting of 64 patients with vasospastic angina diagnosed with coronary angiography and provocative testing [19]. All patients received CCB, however, half received Fluvastatin in addition to the CCB. It was discovered that episodes were significantly lower in the group that received Fluvastatin than those only on CCB (48% vs 79%) [19].

Goal-directed therapy at maximally tolerated doses is effective in treating most patients suffering from vasospastic

angina. Invariably however, some patients will be refractory to CCB and nitrates and continue to experience recurrent anginal episodes. An additional option to aid in the treatment of this subset of patients is percutaneous coronary intervention (PCI) with stenting even in the presence of angiographically normal coronary vasculature [20]. While this is not standard treatment at the moment, it is a known option with some promising evidence already available. In a single-center analysis in China including 21 patients who underwent coronary stenting in the setting of refractory variant angina, only 1 patient continued to have recurrent episodes of variant angina with 5 patients experiencing occasional chest pain and the remaining 15 patients being asymptomatic [21]. The authors concluded that with additional supporting evidence, this could become a viable option for this cohort of patients.

Not all patients with variant angina will go on to develop malignant arrhythmias however, patients with multivessel spasms are at an increased risk for malignant arrhythmias and SCD. Additionally, there is a significant risk for recurrent arrhythmic events after SCD from coronary vasospasms [22]. The current guidelines do not provide a clear consensus on how a patient with vasospastic induced malignant arrhythmias should be managed when it comes to Implantable Cardioverter Defibrillator (ICD) placement. In fact, the American Heart Association's guidelines currently state that in the structurally normal-appearing heart, ventricular arrhythmias should be managed medically alone [23]. In a retrospective multicenter study, an ICD was placed in patients with vasospastic angina and ventricular arrhythmias due to the unpredictability of recurrence. Device placement was supplemented with goal-directed medications as well. Follow up of 2.9 years showed that all patients with the ICD were alive, 4 of whom had recorded VF and 5 episodes of pulseless electrical activity (PEA) [24]. The need for pre-emptive ICD placement seems to be warranted due to the unpredictability and severity of coronary vasospasms. A study assessing the long-term prognosis of patients with variant angina presenting with aborted SCD supported the use of ICD's as a secondary prevention strategy because multiple vasodilatory therapy appeared to be suboptimal. Sueda et al in another study stated that after ICD implantation in patients with aborted SCD from coronary artery spasms, it was observed that 25% of these patients during a 41 month follow up had appropriate shocks delivered [25].

Current guidelines recommend ICD placement for two cohorts, primary and secondary prevention. Primary prevention includes patients with heart failure with an ejection fraction (EF) <35%, patients with previous myocardial infarction and EF <30%, congenital long QT, Brugada Syndrome [12,16]. There is no mention of vasospastic angina among these indications, whereas the patient featured in this case report serves as an example wherein prophylactic ICD placement could have been beneficial. Secondary prevention includes patients with ventricular tachycardia / ventricular fibrillation with no known reversible cause discovered. However, currently, it is unclear if coronary vasospasms that have led to aborted SCD are considered reversible, this is primarily due to lack of large size observational studies regarding the matter [10]. With this said, several small prospective and

retrospective studies have reported significant results showing the high recurrence rates of ventricular arrhythmias and subsequent SCD in these patients [26,27,28]. One of the largest studies which was published in *Journal of the American College of Cardiology*, Ahn et al cited patients with aborted SCD who received an ICD had mortality of about 4.3% on follow up versus 19.3% in those who did not receive an ICD (10). In the case of the featured patient, it was therefore of paramount importance that he received ICD placement prior to discharge for secondary prevention of future recurrences and thus a significant mortality benefit.

4. Conclusion

Reports of cardiac arrests from arrhythmias due to coronary artery vasospasm of hemodynamically stable coronary artery disease are limited, as are observational studies. This case however shows the importance of further investigation in patients who present with persistent anginal chest pain despite adequate goal-directed therapy. Such investigations that may be performed is coronary angiography with or without ergonovine provocation testing. Seemingly harmless coronary vasospasm can indeed not only be the cause of ACS but also subsequently result in a malignant arrhythmia and SCD. Secondly, despite current guidelines having no mention of ICD placement in patients with coronary artery vasospasm induced ventricular arrhythmias, we strongly suggest these patients be evaluated for ICD placement and therefore recognize the need for further prospective studies regarding this matter.

In conclusion, we recommend special consideration for the possibility of coronary vasospasm in patients who have cardiac arrest after angina and are subsequently found to have no hemodynamically significant coronary artery disease. Treatment should not only be aimed at preventing transient episodes of coronary artery spasms but also the consideration of an ICD placement in these high-risk individuals as well.

Acknowledgements

This work is supported, in part, by the efforts of Dr. Moro O. Salifu MD, MPH, MBA, MACP, Professor and Chairman of Medicine through NIMHD Grant number S21MD012474.

References

- [1] Prinzmetal M, Kennamer R, Merliss R, Wada T, Bor N. Angina pectoris. I. A variant form of angina pectoris; preliminary report. *Am J Med* 1959; 27: 375-88.
- [2] M.J. Hung, P. Hu, M.Y. Hung Coronary artery spasm: review and update *Int. J. Med. Sci.*, 11 (11) (2014), pp. 1161-1171 *Journal Article; Review*. 2014-01-20.
- [3] U. Sechtem, P. Ong, A. Athanasiadis, M. Vohringer, R. Merher, A. Yilmaz Coronary vasospasm: is it a myth? *Am. J. Cardiovasc. Drugs*, 10 (Suppl. 1) (2010), pp. 19-26 *Case Reports; Journal Article; Research Support, Non-U.S. Gov't; Review*. 2010-01-20.
- [4] G.A. Lanza, G. Careri, F. Crea Mechanisms of coronary artery spasm *Circulation*, 124 (16) (2011), pp. 1774-1782 *Journal Article; Review*. 2011-10-18.

- [5] H. Yasue, S. Omote, A. Takizawa, M. Nagano Coronary arterial spasm in ischemic heart disease and its pathogenesis *Circ Res*, 52 (suppl 1) (1983), pp. 147-152.
- [6] CL Fellows, WD Weaver, HL Greene Cardiac arrest associated with coronary artery spasm *Am J Cardiol*, 60 (1987), pp. 1397-1399.
- [7] Herman AR, Cheung C, Gerull B, et al. Outcome of apparently unexplained cardiac arrest: results from investigation and follow-up of the Prospective Cardiac Arrest Survivors With Pre-served Ejection Fraction Registry. *Circ Arrhythmia Electrophysiology* 2016; 9: e003619.
- [8] Ming-Jui Hung a, Chi-Wen Cheng a, Ning-I Yang a, Ming-Yow Hung b, Wen-Jin Cherng a Coronary vasospasm-induced acute coronary syndrome complicated by life-threatening cardiac arrhythmias in patients without hemodynamically significant coronary artery disease *International Journal of Cardiology* Volume 117, Issue 1, 12 April 2007, Pages 37-44.
- [9] Gensini GG, Di Giorgi S, Murad-Netto S, Black A. Arteriographic demonstration of coronary artery spasm and its release after the use of a vasodilator in a case of angina pectoris and in the experimental animal. *Angiology* 1962; 13: 550-3.
- [10] R.N. MacAlin Relation of coronary arterial spasm to sites of organic stenosis *Am J Cardiol*, 46 (1980), pp. 143-153.
- [11] Ong P, Athanasiadis A, Borgulya G, Mahrholdt H, Kaski JC, Sechtem U, High Prevalence of a Pathological Response to Acetylcholine Testing in Patients With Stable Angina Pectoris and Unobstructed Coronary Arteries: The ACOVA Study (Abnormal COronary VASomotion in patients with stable angina and unobstructed coronary arteries), *Journal of the American College of Cardiology*, Volume 59, Issue 7, 2012, Pages 655-662.
- [12] T. Fukai, S. Koyanagi, A. Takeshita Role of coronary vasospasm in the pathogenesis of myocardial infarction: study in patients with no significant coronary stenosis *Am Heart J*, 126 (1993), pp. 1305-1311.
- [13] W.C. Roberts, R.C. Curry Jr., J.M. Isner, et al. Sudden death in Prinzmetal's angina with coronary spasm documented by angiography. Analysis of three necropsy patients *Am J Cardiol*, 50 (1982), pp. 203-210.
- [14] S. Sueda, H. Kohno, H. Fukuda, et al. Frequency of provoked coronary spasms in patients undergoing coronary arteriography using a spasm provocation test via intracoronary administration of ergonovine *Angiology*, 55 (2004), pp. 403-411.
- [15] T. Fukai, S. Koyanagi, A. Takeshita Role of coronary vasospasm in the pathogenesis of myocardial infarction: study in patients with no significant coronary stenosis *Am Heart J*, 126 (1993), pp. 1305-1311.
- [16] A.E. Epstein, J.P. DiMarco, K.A. Ellenbogen, et al. ACC/AHA/HRS 2008 guidelines for device-based therapy of cardiac rhythm abnormalities: a report of the American College of Cardiology/American Heart Association Task Force on Practice Guidelines (Writing Committee to Revise the ACC/AHA/NASPE 2002 Guideline Update for Implantation of Cardiac Pacemakers and Antiarrhythmia Devices) developed in collaboration with the American Association for Thoracic Surgery and Society of Thoracic Surgeons *J Am Coll Cardiol*, 51 (2008), pp. e1-e62.
- [17] Kusama Y, Kodani E, Nakagomi A, et al. Variant angina and coronary artery spasm: the clinical spectrum, pathophysiology, and management. *J Nippon Med Sch*. 2011; 78(1): 4-12.
- [18] Conti CR. Role of coronary artery spasm in ischemic heart disease. Therapeutic implications. *G Ital Cardiol*. 1984; 14(11): 901-910.
- [19] Ishii M, Kaikita K, Sato K, et al. Impact of Statin Therapy on Clinical Outcome in Patients With Coronary Spasm. *J Am Heart Assoc*. 2016; 5(5): e003426. Published 2016 May 20.
- [20] Shiroto T, Yasuda S, Tsuburaya R, et al. Role of Rho-kinase in the pathogenesis of coronary hyperconstricting responses induced by drug-eluting stents in pigs in vivo. *J Am Coll Cardiol*. 2009; 54(24): 2321-2329.
- [21] Chu G, Zhang G, Zhang Z, Liu S, Wen Q, Sun B. Clinical outcome of coronary stenting in patients with variant angina refractory to medical treatment: a consecutive single-center analysis. *Med Princ Pract*. 2013; 22(6), pp. 583-587.
- [22] Kleyman R, Goyal R, Patel N, Joseph J, Akel R. Vasospastic Angina and Role of Cardiac Catheterization. *Cureus*. 2019; 11(9): e5588. Published 2019 Sep 6.
- [23] Al-Khatib, S. M. et al. 2017 AHA/ACC/HRS guideline for management of patients with ventricular arrhythmias and the prevention of sudden cardiac death: executive summary. A report of the American College of Cardiology/American Heart Association Task Force on Clinical Practice Guidelines and the Heart Rhythm Society. *Circulation* 138, e210-e271 (2018).
- [24] Matsue Y, Suzuki M, Nishizaki M, Hojo R, Hashimoto Y, Sakurada H. Clinical implications of an implantable cardioverter-defibrillator in patients with vasospastic angina and lethal ventricular arrhythmia. *J Am Coll Cardiol*. 2012; 60(10): 908-913.
- [25] Sueda S, Kohno H. Optimal Medications and Appropriate Implantable Cardioverter-defibrillator Shocks in Aborted Sudden Cardiac Death Due to Coronary Spasm. *Intern Med*. 2018; 57(10): 1361-1369.
- [26] Ahn J, Lee K, Yoo S, Cho Y, Suh J, Shin E, Lee J, Shin D, Kim S, Baek S, Seung K, Nam C, Jin E, Lee S, Oh J, Jang J, Park H, Yoon N, Prognosis of Variant Angina Manifesting as Aborted Sudden Cardiac Death, *Journal of the American College of Cardiology*, Volume 68, Issue 2, 2016, Pages 137-145.
- [27] P. Chevalier, A. Dacosta, P. Defaye, et al. Arrhythmic cardiac arrest due to isolated coronary artery spasm: long-term outcome of seven resuscitated patients *J Am Coll Cardiol*, 31 (1998), pp. 57-61.
- [28] H. Shimokawa, K. Nagasawa, T. Irie, et al. Clinical characteristics and long-term prognosis of patients with variant angina. A comparative study between western and Japanese populations *Int J Cardiol*, 18 (1988), pp. 331-349.

