

# Snorkeling Induced Pulmonary Edema: A Case Report and Review of the Literature

Ruchi Yadav<sup>1</sup>, Pramod Theetha Kariyanna<sup>1</sup>, Dommalur Jayarangaiah<sup>2</sup>, Delroy Thomas<sup>3</sup>, Vivek Yadav<sup>4</sup>, Ashkan Tadayoni<sup>1</sup>, Lyudmila Aurora<sup>1</sup>, Benjamin Ramalanjaona<sup>1</sup>, Isabel M. McFarlane<sup>1,\*</sup>

<sup>1</sup>Division of Cardiovascular Diseases and Department of Internal Medicine, State University of New York, Downstate Medical Center, Brooklyn, NY 11203, U.S.A

<sup>2</sup>Division of Internal Medicine, The American University of St Vincent, B210-5145, Steeles Ave. W. Toronto, ON M9L 1R5, Canada

<sup>3</sup>Milton Cato Memorial Hospital, Kingstown, Saint Vincent and the Grenadines VC0130

<sup>4</sup>Department of Internal Medicine, Brookdale University Hospitals and Medical Center, 1 Brookdale Plaza, Brooklyn, New York, NY 11212, USA

\*Corresponding author: [Isabel.McFarlane@downstate.edu](mailto:Isabel.McFarlane@downstate.edu)

Received March 01, 2020; Revised April 05, 2020; Accepted April 14, 2020

**Abstract** Swimming-induced pulmonary edema (SIPE), also called immersion pulmonary edema (IPE), is a medical condition seen in various water-based activities such as scuba diving, swimming, aqua jogging, triathlete competition and snorkeling. It occurs when transcapillary filtration of low protein fluid collects in the lungs, in the absence of water aspiration during an aquatic activity, causing acute dyspnea, cough and/or hemoptysis. The hallmark of this entity is the complete resolution of symptoms within 48 hours. SIPE in snorkeling is an under-reported and understudied subject. The true prevalence of SIPE is unknown with an estimated range from 1.8-60% among combat swimmers trainee and 1.4% in triathletes. Recent developments have been done in elucidating the pathophysiology of SIPE with regards to pulmonary capillary pressure so that the predisposing factors and potential causes can be targeted. SIPE can be a potentially life-threatening condition, which needs to be recognized by the swimmers, divers, supervising physicians in order to diagnose and manage it promptly. We report a rare case of SIPE in snorkeling which presented with acute respiratory symptoms and managed with supportive measures in the hospital.

**Keywords:** pulmonary edema, immersion pulmonary edema, snorkeling, swimming, athletes

**Cite This Article:** Ruchi Yadav, Pramod Theetha Kariyanna, Dommalur Jayarangaiah, Delroy Thomas, Vivek Yadav, Ashkan Tadayoni, Lyudmila Aurora, Benjamin Ramalanjaona, and Isabel M. McFarlane, "Snorkeling Induced Pulmonary Edema: A Case Report and Review of the Literature." *American Journal of Medical Case Reports*, vol. 8, no. 7 (2020): 173-177. doi: 10.12691/ajmcr-8-7-3.

## 1. Introduction

Swimming-induced pulmonary edema (SIPE), also called immersion pulmonary edema (IPE), is a medical condition, seen in various water-based activities such as scuba diving, swimming, snorkeling, breath-holding diving, surface swimming, military swimming, aqua jogging and triathlete competition [1,2]. In 1981, was the first reported case of SIPE in scuba diving [2]. Presently, SIPE has an estimated prevalence of 1.8-60% among combat swimmers trainee and 1.4% in triathletes [3]. Pons et al calculated the incidence of SIPE in scuba divers as 1.1% [4]. The incidence of IPE based on case studies in Europe is 1.1% [5].

The signs and symptoms of SIPE can range from mild breathlessness to severe dyspnea, pink-tinged sputum, cough, hemoptysis, hypoxia, wheeze and chest tightness [1,6,7]. To the best of our knowledge, to date, a couple of

case reports of immersion pulmonary edema due to snorkeling [8,9] and two cases of snorkeling-induced pulmonary hemorrhage have been reported [10,11]. We are reporting a case of a 50 years old female diagnosed as having an immersion pulmonary edema after snorkeling. Through this article, we try to understand the underlying pathophysiological mechanisms of IPE in order to elucidate its causes and predisposing factors. Subsequently, this knowledge can be useful in preventing its occurrence. Also, this article emphasizes the importance of recognizing this life-threatening condition in potential patients by physicians and paramedics for effective and prompt management.

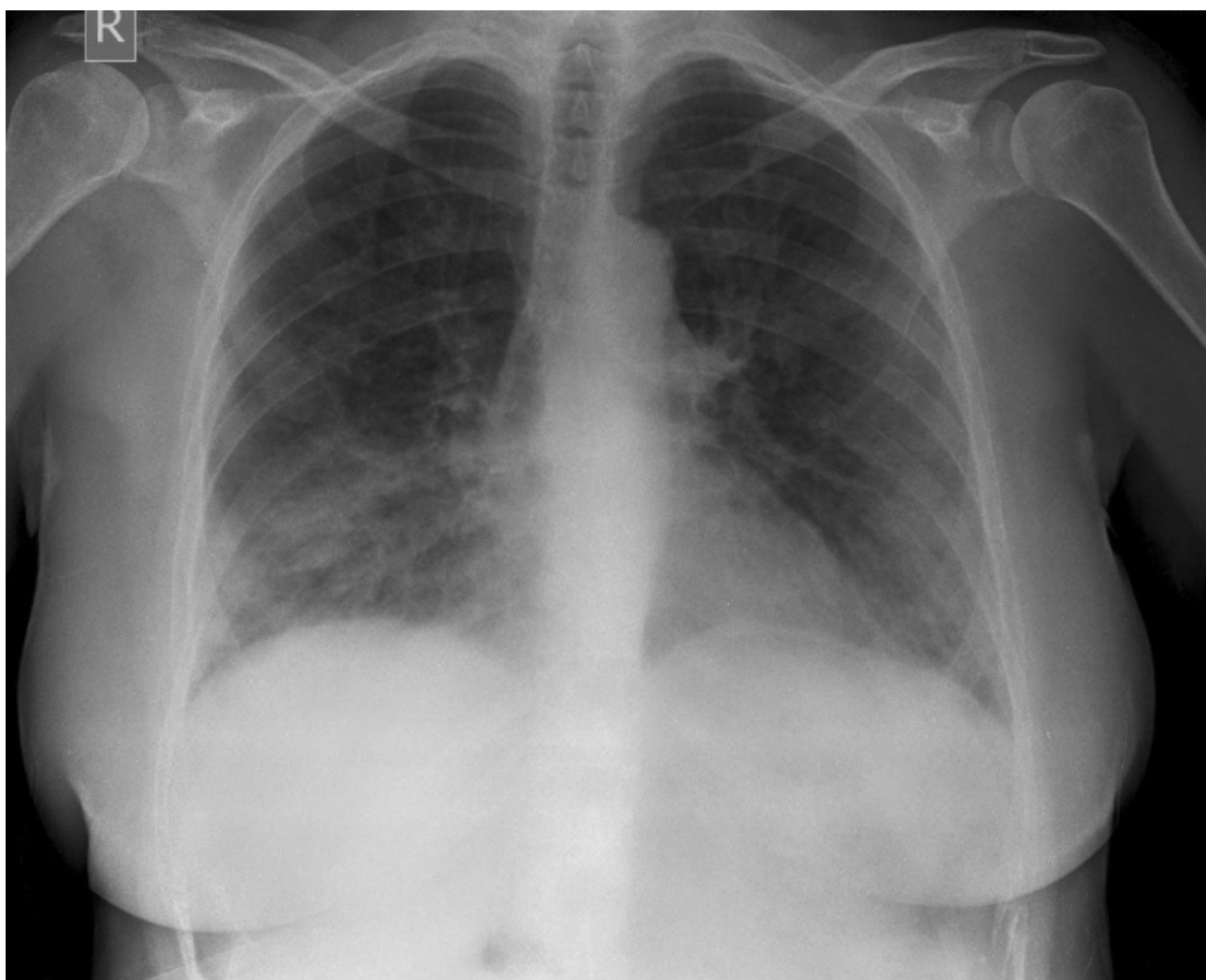## 2. Case Report

A 59 years old female with no known past medical history presented in the hospital with sudden onset of shortness of breath and coughing with blood-tinged

sputum. She experienced these symptoms while she was snorkeling. It was not associated with chest pain, palpitations, dizziness, syncope, headache or vomiting. The episode occurred while she was diving and after 45 minutes of snorkeling, she began to experience sudden onset of shortness of breath. She swam back to the surface where she was lifted by the boat and brought it to the nearby clinic. The patient denied any such episodes in the past. At the clinic, the patient was in severe respiratory distress with tachypnea and tachycardia. The oxygen saturation measured was 75% on room air. She was given oxygen therapy and rushed to the hospital. On examination in the hospital, she was found to be in severe respiratory distress. She was awake, alert and oriented to time, place and person. Her vitals were; heart rate - 110 beats per minute, blood pressure -130/80 mmHg, respiratory rate - 28 per minute. The pupils were equal and reactive to light. There was no jugular venous distension. The cardiovascular examination revealed regular S1 and S2 with no murmur/rub/gallop. The respiratory system on inspection had the use of abdominal muscles and accessory muscles to aid in respiration. There was a

decrease in air entry bilaterally with coarse crackles up to the interscapular area. Per abdomen was soft, non-distended, non-tender with no organomegaly and normoactive bowel sounds. No edema or calf tenderness was found in the extremities. Her neurological examination was unremarkable.

On further investigations, the chest X-ray revealed bilateral congestion to the middle and lower lung fields (Image 1). The electrocardiographic (ECG) findings had sinus tachycardia. Troponin and the rest of the cardiac enzymes were normal. Her blood-work showed no electrolyte abnormality and had normal urine analysis. Transthoracic Echocardiography (TTE) showed normal findings with no chamber or valvular abnormalities and normal ejection fraction. A provisional diagnosis of negative pressure pulmonary edema was made. She was placed in a high fowler position and given oxygen therapy via a face mask. 80 mg of Lasix(Furosemide) was given initially followed by 40 mg after 6 hours. Input and output charting was done with close monitoring of vitals. All her symptoms resolved within 12 hours and she felt symptomatically better.



**Image 1.** Chest X-ray showing bilateral congestion to the middle and lower lung fields

### 3. Discussion

SIPE, is an acute cause of breathlessness in athletes with potentially life-threatening consequences, seen commonly in scuba divers, swimmers and triathletes, characterized by signs and symptoms of immersion pulmonary edema following water immersion [1]. Immersion pulmonary edema (IPE) can be used as an umbrella term for Swimming induced pulmonary edema (SIPE) and Scuba divers pulmonary edema (SDPE) [12]. SIPE occurs due to fluid collection in the lungs, in the absence of water aspiration, in any water sports activity [13]. The incidence of SIPE in triathletes is approximately 1.4% [12,14]. The overall incidence is difficult to assess owing to the minimal number of fatalities attributed to IPE and high reliance on bystanders reporting. The post mortem features of IPE cannot be distinguished from the other causes of deaths in swimming and diving [15]. Also, only the more severe episodes are reported to the healthcare persons as minor episodes tend to resolve quickly [1].

Adir et al. reported the following symptoms of SIPE, in decreasing order, as dyspnea, cough, hemoptysis, wheeze and chest tightness [7]. On examination, there are findings consistent with pulmonary edema such as rales, crackles and/or wheeze. Arterial blood analysis and pulse oximetry show hypoxemia and low oxygen saturation. Chest X-Ray has features suggestive of pulmonary edema and pleural effusions [2,6]. To date, no studies have been done to assess the non-invasive methods of estimating pulmonary arterial pressure or pulmonary vascular resistance among patients of acute SIPE [2]. Ludwig et al. [16] summarized the diagnostic criteria of SIPE as acute onset of dyspnea during or immediately after swimming, hypoxemia with oxygen saturation <92% or alveolar-arterial oxygen gradient of >30mmHg, chest x-ray with alveolar filling process or interstitial pulmonary edema resolving in 48

hours and no history of water aspiration, laryngospasm or preceding infection.

The proposed pathophysiology of SIPE includes elevated pulmonary vascular pressure as the initial insult [2]. IPE is thought to be multifactorial with patient-dependent and external factors. Figure 1 demonstrates the pathophysiology of IPE [17]. The fundamental theory lays importance on the redistribution of blood from the extremities, due to immersion in water, leading to central blood pooling [18]. Coldwater or tight suit, further stimulates peripheral vasoconstriction, leading to an increase in cardiac preload evident by the rise in left atrial pressure, measured by the pulmonary arterial wedge pressure (PAWP) [19]. Any strenuous exercise further increases the cardiac output, leading to an elevated pulmonary artery pressure, which causes alveolar edema and breakdown of the capillary-alveolar barrier [20]. The prone horizontal position of swimming also exacerbates central pooling, which is evident by a theory given by Lund et al., stating a few cases of unilateral SIPE caused by the lateral decubitus position [21]. All individuals with cardiac/pulmonary dysfunction such as left ventricular hypertrophy, hypertension, aortic stenosis, hypertrophic obstructive cardiomyopathy are at a greater risk for SIPE due to an elevated pulmonary pressure [2,22,23]. Casey et al proposed a modified theory in athletes as they already have an augmented cardiac output [21]. Training habits, that are routinely used for terrestrial endurance competition, including salt tablet ingestion and pre-race hydration, may augment the pre-load and predispose the athlete to develop SIPE [2]. Exertion is a common factor found in some cases but many episodes of SIPE have occurred soon after entering into the water highlighting the immersion factor itself as a common cause [23,24]. Various other risk factors proposed are cold water [25], overhydration [26], wetsuit use and female gender [27,28], failure of breathing apparatus with mal-functional valves [14].

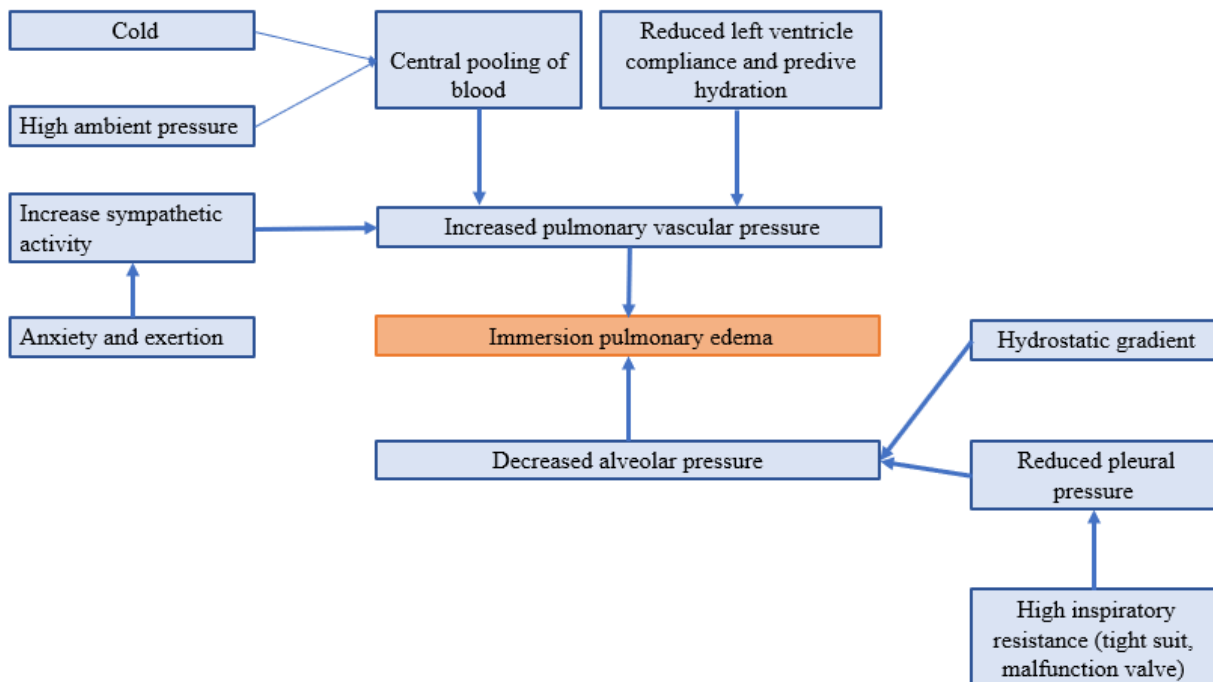


Figure 1. Pathophysiology of immersion pulmonary edema

For the work-up, it is essential to have a prompt and accurate measurement of oxygen saturation in pre-hospital setting that can later aid in monitoring and response to treatment [6]. Chest x-ray, is the investigation of choice, in the emergency department to diagnose pulmonary edema, which was found to be abnormal in 71% of cases reviewed [1,6]. However, mild IPE can be detected only by a CT scan [12]. The latest modality is the Point-of-care-ultrasound (POCUS), used frequently in the pre-hospital setting, to assess SIPE at the waterside events. It is used to differentiate pulmonary edema from the other causes of breathlessness and evaluate the cardiac causes such as stress cardiomyopathy or myocardial infarction [29]. Baseline respiratory functions test and blood gas analysis to rule out any underlying respiratory or cardiac disorder [12]. A detailed cardiac investigation including troponins, creatine kinase-MB, basal natriuretic peptide (BNP), serial ECG, early ECHO is essential [12]. An increase in troponin T level has been seen in IPE attributed to reversible myocardial ischemia [30]. Since therapeutic management is impacted by myocardial injury hence cardiac biomarkers may contribute to screening of patients with IPE [31]. IPE can be differentiated from decompression sickness (DCS) by the levels of cardiac markers as shown by Louge et al. [32]. They founded that copeptin (a surrogate marker for antidiuretic hormone and a stress marker), ischemia-modified albumin (an ischemia/hypoxia marker), BNP (a marker of heart failure) and ultrasensitive-cardiac troponin-I (cTnI) are elevated in IPE versus DCS [12,31]. It is important to differentiate SIPE from DCS as a hyperbaric chamber, used for the treatment of DCS, is not indicated and could cause more harm in SIPE [12].

There has been no randomized trial of SIPE therapy hence the guidelines for the standard care and management are based on logic and clinical experience. The first step in the treatment is the immediate removal from the water, providing a warm environment and removal of any constrictive wetsuit. Additional supportive measures in the form of oxygen, diuretics, beta-2 agonists are given depending on the case [1,2,33,34]. Recently, sildenafil and dihydropyridine calcium channel blockers have been used for the prevention of SIPE [14,18]. In 82% of the cases, there is a complete resolution of the symptoms within 48 hours [1,6].

The rate of recurrence of SIPE in athletes is estimated to be 13-75% [6]. With an average recurrence rate of 30% and the potential for severe outcome, proper diagnosis and reversal of any underlying pathology in IPE should be done by the physician, before the patient returns to the water activity [12]. Any subject with a history of IPE should undergo detailed and thorough investigations including cardio-pulmonary assessment [34,35].

## 4. Conclusion

SIPE is a diagnosis of exclusion with multifactorial origin. IPE can be fatal and life-threatening if not diagnosed and managed on time. The suddenness of its onset, variable presentation and early recovery poses a diagnostic dilemma for the clinicians. Every treating physician should conduct an appropriate primary

assessment and maintain a broad range of differential diagnosis while examining an acutely unwell athlete. Lack of awareness of this entity may result in discharge of the patient, without a formal diagnosis, increasing the chance of its recurrence and severity. More studies and randomized trials are the need of the hour to find a reliable noninvasive method of screening of people who are at risk of SIPE and to have a better understanding of the underlying pathological mechanisms in order to prevent its occurrence.

## Acknowledgements

This work is supported in part by Dr. Moro O. Salifu's efforts through NIH Grant # S21MD012474.

## References

- [1] Smith R, Ormerod JOM, Sabharwal N, Kipps C. Swimming-induced pulmonary edema: current perspectives [Internet]. Open Access Journal of Sports Medicine. 2018 [cited 2020 Feb 16]. Available from: <https://www.dovepress.com/swimming-induced-pulmonary-edema-current-perspectives-peer-reviewed-fulltext-article-OAJSM>.
- [2] Swimming-Induced Pulmonary Edema - American College of Cardiology [Internet]. [cited 2020 Feb 16]. Available from: <https://www.acc.org/latest-in-cardiology/articles/2018/08/14/06/49/swimming-induced-pulmonary-edema>.
- [3] Shupak A, Weiler-Ravell D, Adir Y, Daskalovic YI, Ramon Y, Kerem D. Pulmonary oedema induced by strenuous swimming: a field study. *Respir Physiol*. 2000 Jun; 121(1): 25-31.
- [4] Pons M, Blickenstorfer D, Oechslin E, Hold G, Greminger P, Franzeck UK, et al. Pulmonary oedema in healthy persons during scuba-diving and swimming. *Eur Respir J*. 1995 May; 8(5): 762-7.
- [5] Bousuges A, Ayme K, Chaumet G, Albier E, Borgnotta M, Gavary O. Observational study of potential risk factors of immersion pulmonary edema in healthy divers: exercise intensity is the main contributor. *Sports Med - Open*. 2017 Oct 3; 3(1): 35.
- [6] Grünig H, Nikolaidis PT, Moon RE, Knechtle B. Diagnosis of Swimming Induced Pulmonary Edema—A Review. *Front Physiol* [Internet]. 2017 Aug 31 [cited 2020 Feb 16];8. Available from: <https://www.ncbi.nlm.nih.gov/pmc/articles/PMC5583207/>.
- [7] Adir Y, Shupak A, Gil A, Peled N, Keynan Y, Domachevsky L, et al. Swimming-induced pulmonary edema: clinical presentation and serial lung function. *Chest*. 2004 Aug; 126(2): 394-9.
- [8] Cocharde G, Henckes A, Deslandes S, Noël-Savina E, Bedossa M, Gladu G, et al. Swimming-induced immersion pulmonary edema while snorkeling can be rapidly life-threatening: Case reports. *Undersea Hyperb Med J Undersea Hyperb Med Soc Inc*. 2013 Sep 1; 40: 411-6.
- [9] Yamamoto I, Yamashiro S, Nagano H, Kishaba T, Nei Y, Kinjo K. Immersion Pulmonary Edema During Snorkeling: A Case Report. In: C53 PULMONARY TOXICOLOGY AND CASE REPORTS [Internet]. American Thoracic Society; 2015 [cited 2020 Feb 16]. p. A4670–A4670. (American Thoracic Society International Conference Abstracts). Available from: [https://www.atsjournals.org/doi/abs/10.1164/ajrccm-conference.2015.191.1\\_MeetingAbstracts.A4670](https://www.atsjournals.org/doi/abs/10.1164/ajrccm-conference.2015.191.1_MeetingAbstracts.A4670).
- [10] Choo DM, Kim SS, Chung CU, Park DI, Kim JH. Snorkeling-Induced Pulmonary Hemorrhage: A Case Report. *J Korean Soc Radiol*. 2017 Nov 1; 77(5): 344-7.
- [11] Ionescu RC, Khan BA, Farber MO, Sigua NL. Snorkeling, A Rare Cause Of Diffuse Alveolar Hemorrhage In A Healthy Swimmer. In: D103 CASE REPORTS: GENERAL PULMONARY [Internet]. American Thoracic Society; 2012 [cited 2020 Feb 17]. p. A6594–A6594. (American Thoracic Society International Conference Abstracts). Available from: [https://www.atsjournals.org/doi/abs/10.1164/ajrccm-conference.2012.185.1\\_MeetingAbstracts.A6594](https://www.atsjournals.org/doi/abs/10.1164/ajrccm-conference.2012.185.1_MeetingAbstracts.A6594).

- [12] Hageman SM, Murphy-Lavoie HM. Immersion Pulmonary Edema. In: StatPearls [Internet]. Treasure Island (FL): StatPearls Publishing; 2020 [cited 2020 Feb 17]. Available from: <http://www.ncbi.nlm.nih.gov/books/NBK499853/>.
- [13] Miller CC, Calder-Becker K, Modave F. Swimming-induced pulmonary edema in triathletes. *Am J Emerg Med*. 2010 Oct; 28(8): 941-6.
- [14] Spencer S, Dickinson J, Forbes L. Occurrence, Risk Factors, Prognosis and Prevention of Swimming-Induced Pulmonary Oedema: a Systematic Review. *Sports Med - Open*. 2018 Sep 20; 4(1): 43.
- [15] Vinkel J, Bak P, Juel Thiis Knudsen P, Hyldegaard O. Forensic Case Reports Presenting Immersion Pulmonary Edema as a Differential Diagnosis in Fatal Diving Accidents. *J Forensic Sci*. 2018 Jan; 63(1): 299-304.
- [16] Ludwig BB, Mahon RT, Schwartzman EL. Cardiopulmonary function after recovery from swimming-induced pulmonary edema. *Clin J Sport Med Off J Can Acad Sport Med*. 2006 Jul; 16(4): 348-51.
- [17] (PDF) Immersion Pulmonary Edema [Internet]. [cited 2020 Feb 17]. Available from: [https://www.researchgate.net/publication/299824684\\_Immersion\\_Pulmonary\\_Edema](https://www.researchgate.net/publication/299824684_Immersion_Pulmonary_Edema).
- [18] Wester TE, Cherry AD, Pollock NW, Freiburger JJ, Natoli MJ, Schinazi EA, et al. Effects of head and body cooling on hemodynamics during immersed prone exercise at 1 ATA. *J Appl Physiol Bethesda Md* 1985. 2009 Feb; 106(2): 691-700.
- [19] Moon RE, Martina SD, Peacher DF, Potter JF, Wester TE, Cherry AD, et al. Swimming-Induced Pulmonary Edema: Pathophysiology and Risk Reduction With Sildenafil. *Circulation*. 2016 Mar 8; 133(10): 988-96.
- [20] Tsukimoto K, Mathieu-Costello O, Prediletto R, Elliott AR, West JB. Ultrastructural appearances of pulmonary capillaries at high transmural pressures. *J Appl Physiol Bethesda Md* 1985. 1991 Aug; 71(2): 573-82.
- [21] Lund KL, Mahon RT, Tanen DA, Bakhda S. Swimming-induced pulmonary edema. *Ann Emerg Med*. 2003 Feb; 41(2): 251-6.
- [22] Casey H, Dastidar AG, MacIver D. Swimming-induced pulmonary oedema in two triathletes: a novel pathophysiological explanation. *J R Soc Med*. 2014 Nov; 107(11): 450-2.
- [23] Smith R, Brooke D, Kipps C, Skaria B, Subramaniam V. A case of recurrent swimming-induced pulmonary edema in a triathlete: the need for awareness. *Scand J Med Sci Sports*. 2017 Oct; 27(10): 1130-5.
- [24] Coulange M, Rossi P, Gargne O, Gole Y, Bessereau J, Regnard J, et al. Pulmonary oedema in healthy SCUBA divers: new physiopathological pathways. *Clin Physiol Funct Imaging*. 2010 May; 30(3): 181-6.
- [25] Wilmshurst PT, Nuri M, Crowther A, Webb-Peploe MM. Cold-induced pulmonary oedema in scuba divers and swimmers and subsequent development of hypertension. *Lancet Lond Engl*. 1989 Jan 14; 1(8629): 62-5.
- [26] Weiler-Ravell D, Shupak A, Goldenberg I, Halpern P, Shoshani O, Hirschhorn G, et al. Pulmonary oedema and haemoptysis induced by strenuous swimming. *BMJ*. 1995 Aug 5; 311(7001): 361-2.
- [27] Carter EA, Koehle MS. Immersion Pulmonary Edema in Female Triathletes. *Pulm Med [Internet]*. 2011 [cited 2020 Feb 17]; 2011. Available from: <https://www.ncbi.nlm.nih.gov/pmc/articles/PMC3109347/>.
- [28] Gempp E, Demaistre S, Louge P. Hypertension is predictive of recurrent immersion pulmonary edema in scuba divers. *Int J Cardiol*. 2014 Mar 15; 172(2): 528-9.
- [29] Alonso JV, Chowdhury M, Borakati R, Gankande U. Swimming-induced pulmonary oedema an uncommon condition diagnosed with POCUS ultrasound. *Am J Emerg Med*. 2017 Dec; 35(12): 1986.e3-1986.e4.
- [30] Reversible myocardial dysfunction and clinical outcome in scuba divers with immersion pulmonary edema. - Abstract - Europe PMC [Internet]. [cited 2020 Feb 18]. Available from: <https://europepmc.org/article/med/23497776>.
- [31] Marlinge M, Deharo P, Joulia F, Coulange M, Vairo D, Gaudry M, et al. Troponins in scuba divers with immersion pulmonary edema. *Biosci Rep [Internet]*. 2018 Sep 28 [cited 2020 Feb 18];38(5). Available from: <https://www.ncbi.nlm.nih.gov/pmc/articles/PMC6165839/>.
- [32] Louge P, Coulange M, Beneton F, Gempp E, Le Pennetier O, Algoud M, et al. Pathophysiological and diagnostic implications of cardiac biomarkers and antidiuretic hormone release in distinguishing immersion pulmonary edema from decompression sickness. *Medicine (Baltimore)*. 2016 Jun; 95(26): e4060.
- [33] Groshaus HE, Manocha S, Walley KR, Russell JA. Mechanisms of beta-receptor stimulation-induced improvement of acute lung injury and pulmonary edema. *Crit Care Lond Engl*. 2004 Aug; 8(4): 234-42.
- [34] Kumar M, Thompson PD. A literature review of immersion pulmonary edema. *Phys Sportsmed*. 2019; 47(2): 148-51.
- [35] Desgraz B, Sartori C, Saubade M, Héritier F, Gabus V. [Immersion pulmonary edema]. *Rev Med Suisse*. 2017 Jul 12; 13(569): 1324-8.

