

# Concurrent Anaplastic and Papillary Thyroid Carcinomas: A Case Report

Samara Skwiersky<sup>1</sup>, Gil Hevroni<sup>1</sup>, Gurbaj Singh<sup>1</sup>, Lisel Hope<sup>1</sup>, Tahmineh Haidary<sup>2</sup>,  
Moro O. Salifu<sup>1</sup>, Samy I. McFarlane<sup>1,\*</sup>

<sup>1</sup>Department of Internal Medicine, SUNY- Downstate Health Science University, Brooklyn, New York, United States- 11203

<sup>2</sup>Department of Pathology, SUNY- Downstate Health Science University, Brooklyn, New York, United States- 11203

\*Corresponding author: [smcfarlane@downstate.edu](mailto:smcfarlane@downstate.edu)

Received April 03, 2020; Revised April 16, 2020; Accepted April 22, 2020

**Abstract** Anaplastic thyroid cancer (ATC) is a rare, but extremely aggressive, form of cancer with a high mortality rate. Differentiated thyroid cancer (DTC), on the other hand, including papillary and follicular subtypes, are relatively common and typically follows a more indolent course. Cases have been reported in which ATC transforms from DTC, and where DTC and ATC exist simultaneously. Given the low incidence of such cases, they have not been well studied, and the optimal treatment regimen has yet to be determined. We present a case of a 77-year-old woman who was initially presented with papillary thyroid cancer (PTC) with focal ATC. Five months after undergoing total thyroidectomy, she returned with a new right sided neck mass. Fine needle aspiration (FNA) with biopsies of the mass and lymph node at one level revealed a smear pattern consistent with ATC. However, lymph node biopsy taken from a different level revealed a smear pattern consistent with PTC. Mutation analysis was performed and results were positive for metastatic BRAF V600- mutant ATC. The patient was then started on dabrafenib/trametinib chemotherapy. Seven months later, she was tolerating treatment well. These unique clinical features including the initial presentation and the relatively favorable survival, that is more than double that of the median survival rate for ATC, suggests that those with synchronous PTC and ATC may have a more indolent course with better prognosis than those with ATC alone. It is also possible that the relatively longer survival in our patient is due to the use of the BRAF inhibitor, dabrafenib and the MEK inhibitor, trametinib in this case with concurrent ATC and PTC. While patients with both PTC and ATC have been documented to have mutations in the BRAF V600 gene, the objective of this report is to present the relatively favorable outcomes when a therapeutic regimen is guided by mutation analysis. Future research into advanced treatment options including targeted therapy and /or immunotherapy for both DTC and ATC is needed. Somatic mutation testing may also be helpful to identify oncogenic kinase abnormalities that will inform therapeutic decision making.

**Keywords:** *anaplastic thyroid cancer, papillary thyroid cancer, concurrent*

**Cite This Article:** Samara Skwiersky, Gil Hevroni, Gurbaj Singh, Lisel Hope, Tahmineh Haidary, Moro O. Salifu, and Samy I. McFarlane, "Concurrent Anaplastic and Papillary Thyroid Carcinomas: A Case Report." *American Journal of Medical Case Reports*, vol. 8, no. 7 (2020): 202-205. doi: 10.12691/ajmcr-8-7-11.

## 1. Introduction

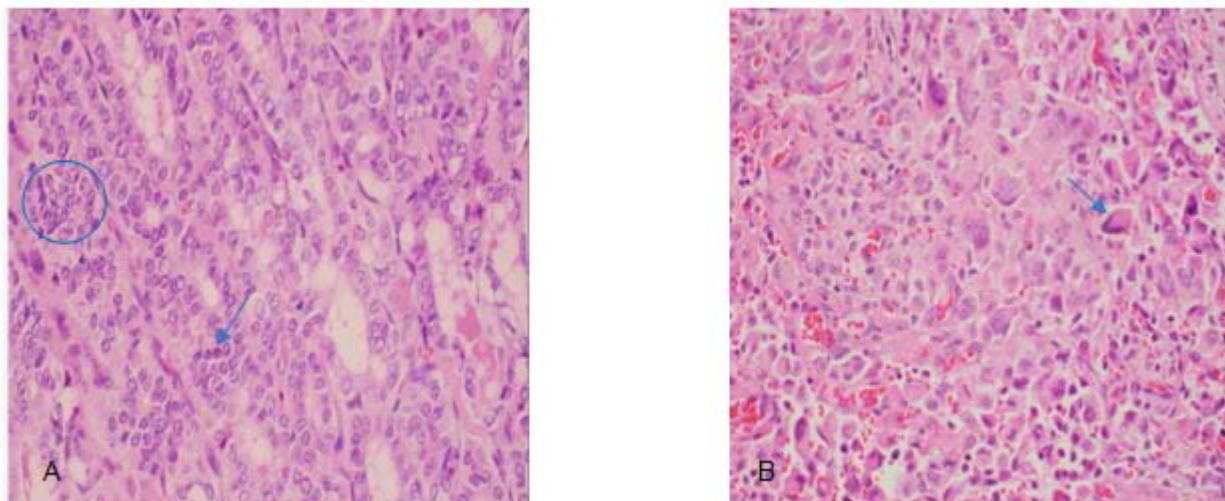
Anaplastic thyroid cancer (ATC) is a type of undifferentiated epithelial thyroid carcinoma. It is a rare form of thyroid cancer, representing only 1.7% of all thyroid cancer cases in the United States [1]. Differentiated thyroid cancer (DTC), including the follicular and papillary subtypes, account for the majority of cases with papillary thyroid cancer (PTC) alone accounting for 85% of all thyroid cancers [2]. We present a case that was diagnosed with thyroid cancer with concurrent anaplastic and papillary malignant components. It is not entirely clear whether our patient's ATC transformed from her pre-existing PTC or if both malignancies co-existed on initial presentation.

## 2. Case Description

A 77-year old female presented to the clinic with a right-sided neck mass. Fine needle aspiration with biopsy of the mass found cells suggestive of PTC. However, excision of the mass showed papillary thyroid carcinoma with focal anaplastic thyroid carcinoma (0.4 cm) extending into the surrounding skeletal muscle and fibro-adipose tissue measuring 0.3 cm from the surgical margin. Lymph node and thyroid dissection revealed papillary carcinoma, follicular variant, with the largest focus in the left lobe. The tumor, staged T3b N1 Mx, was located 0.2 cm from the left posterior margin, with two out of four perithyroidal lymph nodes positive for metastatic carcinoma. Serum thyroglobulin level at that time was

4.76 ng/mL (1.60-59.90), thyroglobulin antibody (Ab) <20.0 IU/mL (0.0-40.0). The patient underwent total thyroidectomy and was started on synthroid 137 mcg daily. The patient then left the country without having received radioactive iodine therapy. Five months later, she returned to our institution with a new, firm, non-mobile swelling on the right side of her neck. PET/CT scan revealed hypermetabolic right lower cervical lymph nodes and hypermetabolic pulmonary nodules compatible with metastatic disease. FNA of right thyroid mass showed the smear pattern suggestive of anaplastic thyroid carcinoma (Figure 1 A) with abundant malignant cells singly and in scant aggregates with eccentrically

placed nuclei, spindle, epithelioid and giant cell features. Lymph node biopsy revealed cytology smear pattern consistent with anaplastic thyroid carcinoma. However, lymph node biopsy taken from a different level revealed smear pattern consistent with papillary thyroid carcinoma (Figure 1 B). Mutation analysis was performed and results were positive for BRAF p.V600E. The patient was subsequently started on a combination of dabrafenib/trametinib therapy. Six months later, the patient appeared to tolerate the treatment well. Three months after treatment initiation, thyroglobulin levels decreased to 0.92 ng/mL (1.60-59.90) with thyroglobulin Ab level <20.0 IU/ml.



**Figure 1.** **Figure A.** Anaplastic Thyroid Carcinoma with high grade pleomorphic cells. The nuclei are large, hyperchromatic, and irregularly shaped with variation in size (blue arrow). Hematoxylin and eosin staining (H&E). 400x. **Figure B.** Histopathological examination of Papillary Thyroid Carcinoma with glandular architecture, overlapping crowded (blue circle) nuclei with high nuclear to cytoplasmic ratio, chromatin clearing and grooves (blue arrow). Hematoxylin and eosin staining (H&E). 400x.

### 3. Discussion

ATC is a rare, but extremely aggressive form of thyroid cancer with a high mortality rate of 33-50%, a median survival of 3-4 months, and less than a 20% survival of 1 year [1,2,3]. In contrast, DTCs including the papillary and follicular subtypes typically follow a more indolent course. In one study, PTC was found to have a disease specific mortality rate of 6% [4]. Despite its low mortality rate, PTC has a high rate of recurrence up to 30%. Recurrence rates are highest among older patients, those with larger tumor sizes, and those with extrathyroidal extension on initial presentation [5].

Despite the low incidence of ATC, cases have been reported in which ATC transforms from DTC, and where DTC and ATC exist simultaneously. Both of these possibilities could explain the concurrence of these cancers in our patient. Data has shown that approximately 20% of patients with ATC have a history of previously diagnosed DTC, and 20-30% of patients with ATC have tumors with components of DTC. In fact, one study of 121 cases of ATC treated at one hospital in Houston, Texas found that 35% of these patients had areas of DTC [6]. PTC, particularly, the aggressive tall cell variant, is the most common type of carcinoma to coexist with ATC [7]. A few cases have been described in which this transformation occurs from a metastatic site. This is a possibility in our case, given the perithyroidal lymph node

involvement and hypermetabolic pulmonary nodules found in the original tumor, compatible with metastatic disease.

The common follicular cell histogenesis in which anaplastic, follicular, and papillary subtype share, could explain the tendency for anaplastic carcinomas to coexist or transform from these differentiated subtypes of thyroid carcinoma [8]. Although the exact mechanism of transformation remains unclear, multiple genes have been hypothesized to be involved in the process. For instance, the mutation in tumor suppressor gene, TP53, is believed to play a role in the de-differentiation from DTC to ATC [9]. Additionally, mutations in proto-oncogenes such as RAS and BRAF have been detected in the development of both PTC and ATC, which is a possible explanation for both the dedifferentiation and coexistence of these two malignancies [10]. Cases have been seen in which malignant thyroid tumors comprised of both ATC and DTC histologies are positive for the BRAF V600E mutation, further rendering BRAF mutations as the common driver mutation which can trigger the dedifferentiation to ATC, which may in fact have occurred in our patient, with mutation analysis positive for positive for BRAF p.V600E [7].

Given the overall uncertainty in nature and origin of a malignant thyroid tumor comprised of both differentiated (papillary) and anaplastic histologies, selecting a treatment regimen can be quite challenging. Therefore, prior to

discussing the treatment options available for such unique and understudied clinical presentations, it is essential that we first compare and contrast concepts that are already understood in the management of ATC and DTC alone. According to the American Thyroid Association (ATA) guidelines, feasible options for ATC include surgery, radiotherapy and/or chemotherapy, and these treatment modalities must be combined in order to maximize clinical outcomes in terms of both local and systemic disease control [7]. The challenge in finding appropriate therapy lays in the fact that ATC is characterized by the accumulation of several different oncogenic alterations. Compared with DTC, which is characterized by mutually exclusive driver mutations, the genetic profile of ATC is defined by the presence of two or more mutations [7]. As mentioned before, about 20% of patients with ATC have co-existing DTC, and complete surgical resection, with or without combined adjuvant chemo and radiotherapy is associated with improved disease-free survival and overall survival [7]. Systemic chemotherapy is often utilized in the treatment of ATC. In fact, according to a review by Cabanillas et al, it is reasonable to consider starting chemotherapy on initial presentation in these patients. Specifically, doxorubicin, taxanes (paclitaxel or docetaxel) and platins (cisplatin or carboplatin) have demonstrated activity in ATC with response rates ranging from 15%-25% [11]. Research is currently underway to identify certain genetic mutations and molecular pathways associated with ATC tumorigenesis in order to develop alternative and improved chemotherapy regimens. Given the limited systemic therapeutic options available for patients with ATC, the feasibility and effectiveness of immunotherapy, including checkpoint inhibitors, should be tested in future clinical trials [7].

Although understudied to date, systemic chemotherapy is sometimes used in metastatic DTC refractory to conventional measures such as RAI, surgical measures and EBRT. There is little data comparing the efficacy of different chemotherapy options used for DTC, but the overall approach per the American Thyroid Association (ATA) utilizes kinase inhibitors which mainly work to inhibit angiogenesis and act on oncogenic signaling pathways (drugs that inhibit oncogenic mutated kinases) [12,13]. ATA recommends mutation specific kinase inhibitors such as BRAF or TRK or anti-angiogenic multi targeted kinase inhibitors namely lenvatinib or sorafenib as first line. If these are not available or if the patient is unable to tolerate them, ATA recommends BRAF inhibitors such as vemurafenib or dabrafenib. Lastly, if the above are not successful, doxorubicin or taxanes can be used as alternatives [12,13].

The treatment selection of our patient was based on a study conducted on patients with BRAFV600 mutated anaplastic thyroid cancer after undergoing prior radiation treatment and/or surgery, in which they were treated with both BRAF inhibitor, dabrafenib and MEK inhibitor, trametinib. The confirmed overall response rate was 69% [14], but overall survival rates were not calculated as of publication. This combination of chemotherapy is the first regimen demonstrated to have clinical activity in patients with BRAF V600E mutated ATC, and was in turn utilized as the basis for treatment selection in our patient. We

hypothesize that our patient's significant clinical response to dabrafenib/trametinib is in part due to the fact that her tumor is comprised of PTC and ATC components, both of which have been documented to have mutations the BRAF V600 gene in previously reported cases.

As discussed previously, ATC is an extremely aggressive and lethal malignancy. With a median survival duration of approximately 3-4 months, it is unique that our patient has survived greater than six months. Typically, ATC is extremely aggressive and tends to cause compressive symptoms early on secondary to rapid volume expansion. These include, but are not limited to dyspnea, hemoptysis, dysphagia, stridor, and pain, which are often rapid in onset, occurring early in the disease course. The rapid local progression of ATC which often results in airway obstruction, is the most frequent cause of death in affected patients [7]. In a retrospective analysis of 79 patients with ATC, 86.1% presented with compressive symptoms [3]. The lung is the most common metastatic site (80%), followed by bone (6-16%), and brain (5-13%). The difference in presentation in our patient suggests that those with synchronous PTC and ATC might have a more indolent course with a better prognosis than those with ATC alone.

In conclusion, although rare, anaplastic thyroid carcinoma may either co-exist with DTC or dedifferentiate from it. Unfortunately, given the low incidence of such cases, they have not been well- studied, and the optimal treatment regimen has yet been determined. We report this case given its unique clinical presentation and favorable prognostic features, and to encourage further research into advanced treatment options including targeted and/or immunotherapy for both DTC and ATC. Given the increasing incidence of thyroid cancer worldwide [2], we recommend somatic mutation testing to identify oncogenic kinase abnormalities present on initial biopsy in order to drive chemotherapy selection. While quite costly, this kind of testing could minimize unnecessary exposure to ineffective therapeutic agents, and thus minimize toxicity to affected patients.

## Acknowledgements

This work is supported, in part, by the efforts of Dr. Moro O. Salifu M.D., M.P.H., M.B.A., M.A.C.P., Professor and Chairman of Medicine through NIH Grant number S21MD012474.

## References

- [1] O'Neill, J.P. and A.R. Shaha, Anaplastic thyroid cancer. *Oral Oncology*, 2013. 49(7): p. 702-706.
- [2] Sipsos, J.A. and E.L. Mazzaferri, Thyroid Cancer Epidemiology and Prognostic Variables. *Clinical Oncology*, 2010. 22(6): p. 395-404.
- [3] Simões-Pereira, J., et al., Anaplastic Thyroid Cancer: Clinical Picture of the Last Two Decades at a Single Oncology Referral Centre and Novel Therapeutic Options. *Cancers*, 2019. 11(8): p. 1188.
- [4] Mazzaferri, E.L. and S.M. Jhiang, Long-term impact of initial surgical and medical therapy on papillary and follicular thyroid cancer. *Am J Med*, 1994. 97(5): p. 418-28.

- [5] Brierley, J. and E. Sherman, The Role of External Beam Radiation and Targeted Therapy in Thyroid Cancer. *Seminars in Radiation Oncology*, 2012. 22(3): p. 254-262.
- [6] Venkatesh, Y.S., et al., Anaplastic carcinoma of the thyroid. A clinicopathologic study of 121 cases. *Cancer*, 1990. 66(2): p. 321-30.
- [7] Molinaro, E., et al., Anaplastic thyroid carcinoma: from clinicopathology to genetics and advanced therapies. *Nat Rev Endocrinol*, 2017. 13(11): p. 644-660.
- [8] Ganguly, R., S. Mitra, and A. Datta, Synchronous occurrence of anaplastic, follicular and papillary carcinomas with follicular adenoma in thyroid gland. *Indian Journal of Pathology and Microbiology*, 2010. 53(2): p. 337-339.
- [9] Wiseman, S.M., et al., Anaplastic Thyroid Cancer Evolved From Papillary Carcinoma: Demonstration of Anaplastic Transformation by Means of the Inter-Simple Sequence Repeat Polymerase Chain Reaction. *Archives of Otolaryngology-Head & Neck Surgery*, 2003. 129(1): p. 96-100.
- [10] Ricarte-Filho, J.C., et al., Mutational profile of advanced primary and metastatic radioactive iodine-refractory thyroid cancers reveals distinct pathogenetic roles for BRAF, PIK3CA, and AKT1. *Cancer research*, 2009. 69(11): p. 4885-4893.
- [11] Cabanillas, M.E., et al., Anaplastic Thyroid Carcinoma: Treatment in the Age of Molecular Targeted Therapy. *Journal of Oncology Practice*, 2016. 12(6): p. 511-518.
- [12] Haugen, B.R., et al., 2015 American Thyroid Association Management Guidelines for Adult Patients with Thyroid Nodules and Differentiated Thyroid Cancer: The American Thyroid Association Guidelines Task Force on Thyroid Nodules and Differentiated Thyroid Cancer. *Thyroid*, 2016. 26(1): p. 1-133.
- [13] Weitzman, S.P. and S.I. Sherman, Novel Drug Treatments of Progressive Radioiodine-Refractory Differentiated Thyroid Cancer. *Endocrinol Metab Clin North Am*, 2019. 48(1): p. 253-268.
- [14] Subbiah, V., et al., Dabrafenib and Trametinib Treatment in Patients With Locally Advanced or Metastatic BRAF V600-Mutant Anaplastic Thyroid Cancer. *Journal of Clinical Oncology*, 2018. 36(1): p. 7-13.



© The Author(s) 2020. This article is an open access article distributed under the terms and conditions of the Creative Commons Attribution (CC BY) license (<http://creativecommons.org/licenses/by/4.0/>).