

Vagal-induced Complete Heart Block during Coronary Angiography due to Bladder Distention

Lyudmila Aurora¹, Abid Ullah², Pramod Theetha Kariyanna¹, Oleg Yurevich¹,
Harshith Priyan Chandrakumar², Erdal Cavusoglu¹, Jonathan D. Marmur¹, Isabel M. McFarlane^{1,*}

¹Division of Cardiovascular Diseases, Department of Medicine, State University of New York Health Sciences University, Downstate Medical Center, Brooklyn, NY 11203, U.S.A.

²Department of Internal Medicine, State University of New York Health Sciences University, Downstate Medical Center, Brooklyn, NY 11203, U.S.A.

*Corresponding author: isabel.mcfarlane@downstate.edu

Received November 14, 2019; Revised December 20, 2019; Accepted January 06, 2020

Abstract Vagal stimulation is common during angiographic procedures. A vasovagal reaction in the setting of coronary angiography most commonly presents as hypotension and/or bradycardia. While the array of signs and symptoms of vasovagal reactions are known, atrioventricular (AV) block maybe overlooked due to its intermittent nature. Below we describe a case of a 47 year-old female who presented with transient complete AV block, mediated by a vagal reaction due to bladder distention in the setting of an invasive coronary angiography procedure.

Keywords: *vasovagal, paroxysmal atrioventricular block, extrinsic atrioventricular block bladder distention, Bezold-Jarisch reflex*

Cite This Article: Lyudmila Aurora, Abid Ullah, Pramod Theetha Kariyanna, Oleg Yurevich, Harshith Priyan Chandrakumar, Erdal Cavusoglu, Jonathan D. Marmur, and Isabel M. McFarlane, "Vagal-induced Complete Heart Block during Coronary Angiography due to Bladder Distention." *American Journal of Medical Case Reports*, vol. 8, no. 2 (2020): 56-59. doi: 10.12691/ajmcr-8-2-5.

1. Introduction

A vagal reaction is defined as the stimulation of parasympathetic nervous system that results in a sudden drop in blood pressure, heart rate and cardiac output. [1] In the elderly, vasovagal reflex leading to hypotension can occur without a change in heart rate. This reaction is elicited by well-known triggers such as emotional stress, sight of blood, prolonged standing and less known causes such as bladder distention. [2] Hemodynamic sequelae is usually preceded by a prodrome of clinical symptoms such as flushing, diaphoresis, abdominal discomfort, nausea, lightheadedness and palpitations- thought to be manifestations of the vagus nerve activation. Parasympathetic system activation through efferent branches of the right vagus nerve can lead to a slowing of the heart rate at the sinoatrial (SA) node and vasodilation of the systemic circulation through cardiac baro-receptor and arterial baro-receptor activation. [1] Animal studies have shown that the vagal stimulation also affects conduction at the AV node by directly increasing the PR interval in a linear fashion.[3] Vagal stimulation has been described to occur in as many as 25% of all coronary catheterization procedures [4,5,6] It is known that vagal stimulation can lead to atrioventricular block (AVB), although it has not been described in the setting of coronary angiography. Parasympathetically-mediated paroxysmal AVB is a relatively little-known type of AVB

that manifests as transient second- or third-degree AVB from physiological atrioventricular conduction and can lead to ventricular asystole. Vagally mediated functional AVB can be distinguished electrocardiographically by demonstrating the slowing of sinus rate, prolongation of the PP and PR interval preceding the AVB. [7] Below we describe a case of transient complete AVB mediated by a vagal reaction due to bladder distention in the setting of an invasive coronary angiography procedure.

2. Case Report

A 47 year-old Black female with a past medical history of congestive heart failure (ejection fraction (EF) which improved from 30% to 55%), known coronary artery disease with ST elevation myocardial infarction status post percutaneous coronary intervention to the mid left anterior descending artery a year prior to presentation, as well as hypertension, hyperlipidemia, diabetes mellitus type 2, came with chest pain at rest. EKG revealed normal sinus rhythm, old anteroseptal infarct, left atrial enlargement and was unchanged from prior EKGs. Two sets of troponins were negative. Echocardiogram showed EF of 60%, grade 1 diastolic dysfunction and mild hypokinesis of the anteroseptal wall. Patient was referred for coronary catheterization due to unstable angina. At the start of the procedure, the patient was hemodynamically stable and received local lidocaine injection to the right radial area, as well as a radial cocktail consisting of 3000

units of heparin, 2.5mg of verapamil, 100 mcg of nitroglycerin. She also received 1 mg of IV midazolam and 25 mcg of IV fentanyl for sedation. At that time the patient's vital signs were recorded as blood pressure of 151/104 mm Hg and heart rate of 120 BPM. 35 minutes into the case, after completion of the diagnostic part of the left heart catheterization, she complained of need to urinate but being unable to do so. Shortly after, she began to experience palpitations, diaphoresis and shortness of breath, as well as nausea, pelvic and lower back pain. Her blood pressure dropped to 103/74 mm Hg and heart rate decreased to 73 BPM. Hemodynamic monitor revealed variable PR prolongation followed by an episode of complete heart block lasting 28 seconds. The heart block

reverted spontaneously to normal sinus rhythm and the patient did not experience syncope. The procedure was halted; patient was sat up and given an IV normal saline bolus. A foley catheter was inserted, which immediately drained 600 cc on clear yellow urine and was clamped to avoid further hypotension and hematuria. It eventually drained 1L urine total. As soon as the Foley catheter was inserted, patient reported resolution of symptoms, with blood pressure recovering to 146/103 mm Hg, heart rate 122 BPM. The rest of the diagnostic case, including right heart catheterization and left ventriculogram, was completed uneventfully. Patient was not found to have any new obstructive coronary disease and evaluation of the left ventricle ejection fraction was compatible to the echocardiogram results.

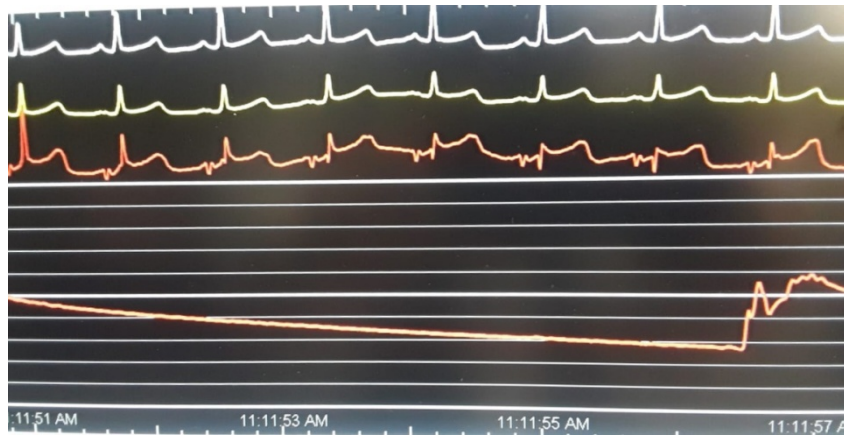

Figure 1. Normal rhythm strip prior to start of vasovagal reaction

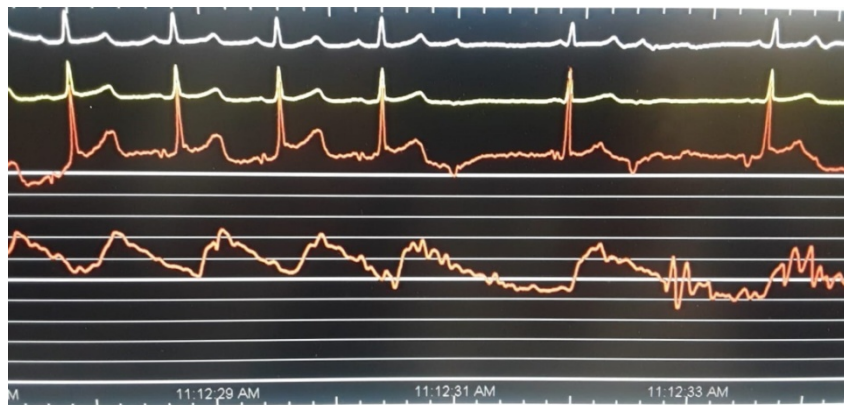


Figure 2. This rhythm strip shows prolonged PR Interval prior to onset of atrioventricular block (AVB)

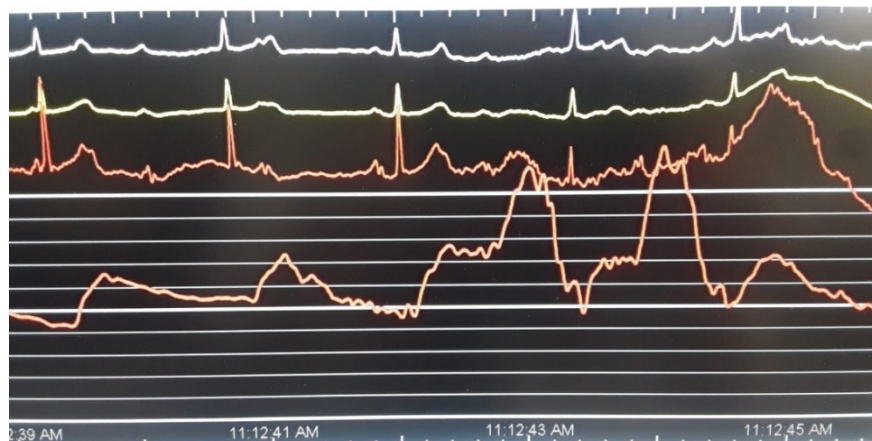

Figure 3. Rhythm strip showing complete atrioventricular block (AVB)

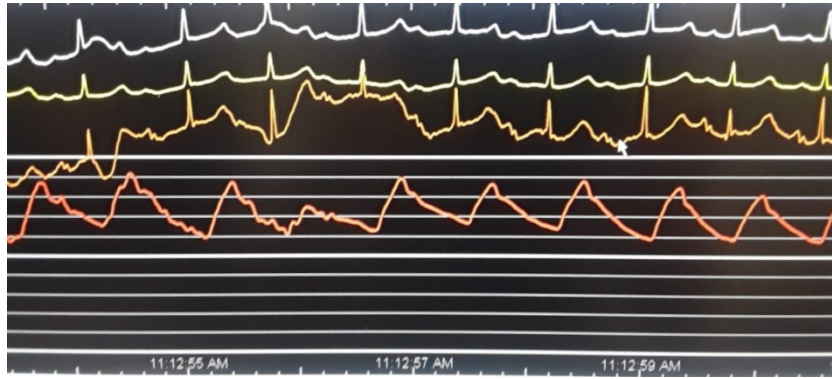


Figure 4. Rhythm strip showing return to normal sinus rhythm

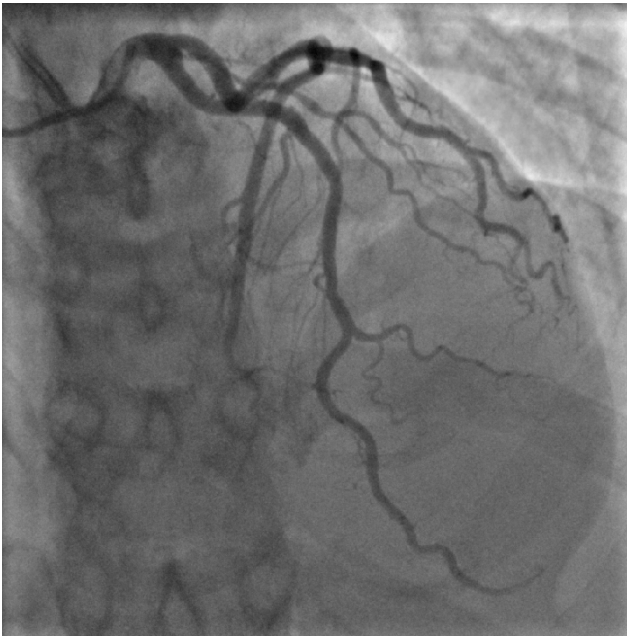

Figure 5. Left heart catheterization with left dominant posterior descending artery (PDA)

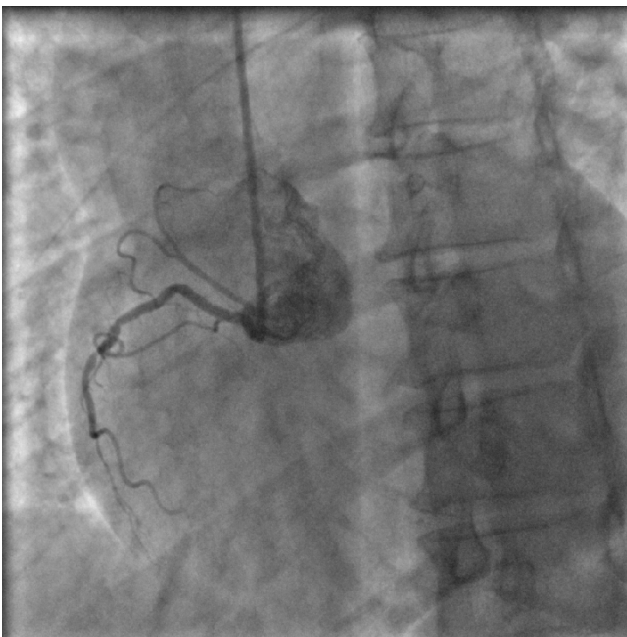


Figure 6. Right heart catheterization with chronic Mid RCA lesion, not intervened due to left dominant circulation.

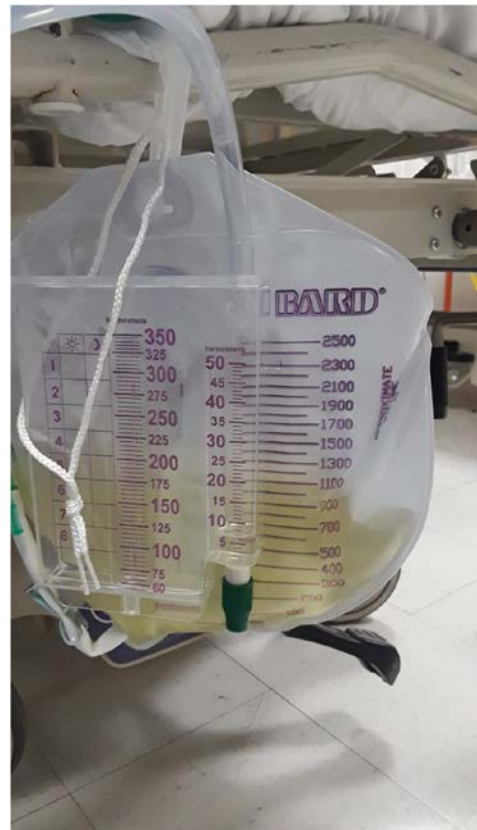

Figure 7. Foley bag showing more than 1 liter of urine drainage

3. Discussion

Hypotension during coronary angiography is an alarming occurrence because it could be associated with a life-threatening event such as hemorrhage, tamponade, coronary artery dissection, acute myocardial infarction or damage to the right bundle branch during a right heart catheterization in a patient with a left bundle branch block. Hypotension during invasive coronary angiography could also be associated with self-limiting or easily treatable causes such as vagal baroreflex activation within the coronary system like Bezold-Jarisch reflex or vagal activation within other organ systems. Vagal stimulation is one of the most common cause of hypotension during coronary angiography, reported to occur in as many as 6-25% of all procedures. [4,5,6] Bladder distention is a known cause of vasovagal reaction, previously described to cause hypotension during coronary catheterization.

[2,8] Complete atrioventricular block during coronary angiography associated with a vagal event has not been described in literature to the best of our knowledge. We attributed this patient's symptoms to a vagal response triggered by a distended bladder due to urinary retention. The patient experienced the typical symptoms of a vagal event (diaphoresis, nausea, abdominal discomfort, palpitations), as well as relative hypotension and bradycardia. Electrocardiographic presentation of the patients transient complete atrioventricular block was most consistent with parasympathetic stimulation of the conduction system. Three types of paroxysmal atrioventricular block (AVB) that can cause syncope have been identified. These include intrinsic paroxysmal atrioventricular block, due to an intrinsic disease of the AV conduction system; this type of "cardiac syncope" is also called Stokes-Adams attack, extrinsic vagal paroxysmal atrioventricular block due to the effect of the parasympathetic nervous system on cardiac conduction, and extrinsic idiopathic paroxysmal atrioventricular block due to low levels of endogenous adenosine. Each type of block presents with unique clinical and electrocardiographic features.[9] The extrinsic atrioventricular block associated with vagal stimulation of cardiac conduction system is often induced by typical triggers, such as emotional distress, prolonged standing, and urinary or bowel movements. Vagal events are accompanied by a prodrome of well described symptoms of autonomic activation, such as diaphoresis, flushing, abdominal discomfort, nausea, palpitations and lightheadedness. [10] Although most vagal events can be recognized from the clinical presentation, more objective diagnostic criteria exist when relating to heart block. Parasympathetically induced extrinsic atrioventricular block presents uniquely on electrocardiography, with gradual slowing of the sinus rate (P-P interval) and a delayed atrioventricular conduction (PR prolonging, or Wenckebach) followed by sinus arrest or complete AVB. [11,12,13,14] This presentation is consistent with electrocardiographic findings of this patient. In contrast, both intrinsic paroxysmal atrioventricular block and extrinsic idiopathic paroxysmal atrioventricular block are associated with sudden onset of complete atrioventricular block. [9] Most vasovagal symptoms resolve spontaneously or with supportive measures such as administration of IV fluids and atropine, or in this case bladder decompression, as was seen in previously reported cases and in our patient. [2] In rare cases, prolonged or severe extrinsic atrioventricular block may require external cardiac pacing, radiofrequency catheter, ablation of ganglionated plexi or even result in cardiac arrest. [7]

4. Conclusion

Vagal reactions are one of the most common causes of hypotension during coronary angiography. Urinary retention leading to bladder distention is a potential trigger for a vagal reaction and should be considered as a potential etiology for hypotension and bradycardia during

invasive cardiac procedures. In some cases, vagal stimulation of the cardiac conduction system can lead to complete AVB, which can cause syncope. In the majority of cases, extrinsic AVB associated with vagal stimulation resolves spontaneously or with supportive measures such as IV fluids, atropine and elimination of the inciting event, such as draining urinary bladder. In extreme cases, extrinsic AVB can be prolonged and may require cardiac pacing.

Acknowledgements

This work is supported, in part, by the efforts of Dr. Moro O. Salifu M.D., M.P.H., M.B.A., M.A.C.P., Professor and Chairman of Medicine through NIH Grant number S21MD012474.

References

- [1] Kern M.J: Hypotension in the Cath lab? Think vagal reaction early. *Cath Lab Digest*. Feb 2012; 20: Issue 2
- [2] Al-Sadawi M., Garcia A.N., Ihsan M., Cavusoglu E., McFarlane S.I. Bladder Distension: An Overlooked Cause Vagal-induced Hypotension during Coronary Angiography. *Am J Med Case Rep*. 2019; 7(8): 180-183.
- [3] Pirola F.T., Potter V.K., Vagal action on atrioventricular conduction and its inhibition by sympathetic stimulation and neuropeptide Y in anaesthetized dogs. *J Auton Nerv Syst*. 1990 Sep; 31(1): 1-12.
- [4] Kern MJ ed. *The Cardiac Catheterization Handbook*, 5th ed. Philadelphia, PA: Elsevier; 2011.
- [5] Landau C, Lange RA, Brent Glamann D, Willard JE, & David Hillis L (1994). Vasovagal reactions in the cardiac catheterization laboratory. *The American Journal of Cardiology*, 73(1), 95-97.
- [6] Gedela M., Kumar V., Shaikh K.A., Stys A., and Tomasz S. Bradycardia during Transradial Cardiac Catheterization due to Catheter Manipulation: Resolved by Catheter Removal. *Case Rep Vasc Med*. 2017; 2017: 8538149.
- [7] Aksu T., Guler T.E., Bozyel S., Mutluer F.O., Golcuk S.E., Yalin K. Electroanatomic-mapping-guided radio-neuroablation versus combined approach for vasovagal syncope: a cross-sectional observational study. *Journal of Interventional Cardiac Electrophysiology* 54 (2), 177-188.
- [8] Yamaguchi Y, Tsuchiya M, Akiba T, Yasuda M, Kiryu Y, Fuzishiro Y, et al. Action of autonomic nervous reflex arising from visceral organs upon the heart. *Acta Neuroveg*. 1966; 28: 224-33.
- [9] Aste M., Brignole M. Syncope and paroxysmal atrioventricular block. *J Arrhythm* 2017 Dec; 33(6): 562-567.
- [10] Moya A., Sutton R., Ammirati F. Guidelines for the diagnosis and management of syncope (version 2009): The Task Force for the Diagnosis and Management of Syncope of the European Society of Cardiology (ESC) *Eur Heart J*. 2009; 30: 2631-2671.
- [11] Lee S., Wellens J.J., Josephson M. Paroxysmal atrioventricular block. *Heart Rhythm*. 2009; 6:1229-1234.
- [12] Sud S., Klein G., Skanes A. Implications of mechanism of bradycardia on response to pacing in patients with unexplained syncope. *Europace*. 2007; 9:312-318.
- [13] Brignole M., Moya A., Menozzi C. Proposed electrocardiographic classification of spontaneous syncope documented by an implantable loop recorder. *Europace* 2005;7;14-18.
- [14] Zysko D., Gajek J., Kozluk E. Electrocardiographic characteristics of atrioventricular block induced by tilt testing. *Europace*. 2009; 11: 225-230.

