

# Rare Case of Incarcerated Bilateral Spigelian Hernia in Ghana: A Case Report and Literature Review

Anwar Sadat Seidu<sup>1,3,\*</sup>, Edwin Mwintierh Ta-ang Yenli<sup>1,3</sup>, Mohammed Sheriff<sup>1,3</sup>,  
Musah Yakubu<sup>1</sup>, Abubakari Bawah Abdulai<sup>2,4</sup>, Emmanuel Akorli<sup>2</sup>, Patricia Akorli<sup>2</sup>

<sup>1</sup>Department of Surgery, Tamale Teaching Hospital, Box TL 16, Tamale, Ghana

<sup>2</sup>Department of Radiology, Tamale Teaching Hospital, Tamale, Ghana

<sup>3</sup>Department of Surgery; School of Medicine and Health Sciences, University for Development Studies, Box TL 1350, Tamale, Ghana

<sup>4</sup>Department of Radiology, School of Medicine and Health Sciences,  
University for Development Studies, Box TL 1350, Tamale, Ghana

\*Corresponding author: [anwarseidu@gmail.com](mailto:anwarseidu@gmail.com)

Received August 16, 2020; Revised September 19, 2020; Accepted September 28, 2020

**Abstract** Spigelian hernia is an uncommon form of abdominal wall hernia. The symptoms can be insidious but the commonest are abdominal pain or a lump on the anterior abdominal wall. Diagnosis can be challenging, but the use of ultrasonography and contrast enhanced CT (CECT) scan is essential to avoid diagnostic delays. In view of a high risk of incarceration and strangulation anticipated, urgent operative intervention is necessary. In this case report, a 42-year old multiparous woman presented with bilateral lumps on the abdominal wall and abdominal pain with no symptoms or signs of obstruction or strangulation. The clinical evaluation was suspicious of bilateral spigelian hernia. This was confirmed by CECT scan of abdomen as ultrasonography was inconclusive. This case report illustrates the diagnostic challenges of spigelian hernia and how early operative intervention is crucial to preventing strangulation.

**Keywords:** *bilateral, spigelian hernia, incarcerated, Rare, Ghana*

**Cite This Article:** Anwar Sadat Seidu, Edwin Mwintierh Ta-ang Yenli, Mohammed Sheriff, Musah Yakubu, Abubakari Bawah Abdulai, Emmanuel Akorli, Patricia Akorli, "Rare Case of Incarcerated Bilateral Spigelian Hernia in Ghana: A Case Report and Literature Review." *American Journal of Medical Case Reports*, vol. 8, no. 12 (2020): 528-531. doi: 10.12691/ajmcr-8-12-26.

## 1. Introduction

Spigelian hernia was named after Adriaan van der Spieghel who was the first anatomist to describe the semilunar line in 1645 [1]. A detailed description of the hernia was later made by Joseph Klinkosh in 1764 [1]. It is caused by herniation through a defect in the spigelian fascia. This mostly occurs in the spigelian belt; a 6cm transverse zone located within the region between the umbilicus and the anterior superior Iliac spines. It accounts for 1-2% of all hernias presenting to the emergency [2,3] and 0.12% of all abdominal wall hernias [4]. This makes spigelian hernias uncommon in the general population. The male to female ratio is 1:1.18 [5]. The symptoms at presentation could be vague but the commonest are pain and lump/protrusion in the abdominal wall [4,6,7,8,9,10].

Spigelian hernia sometimes poses extreme diagnostic challenges to the physician because of the vague nature of symptoms [2,4,6,8,10,11,12]. Diagnosis can be made through clinical assessment but when in doubt, ultrasonography and contrast enhanced CT (CECT) scan can be used for confirmation [4,9,11]. These imaging techniques demonstrate the defect and content of the sac [9,11]. Immediate

operative intervention should always be recommended because of the risk of complications [2,4]. Surgical literature categorizes operative interventions into conventional open approach and laparoscopic approaches (namely Intraperitoneal on-lay mesh, IPOM, transabdominal preperitoneal, TAPP and total extraperitoneal, TEP).

Spigelian hernia is uncommon in Ghana and there is no report of such a case in available scientific literature. We reviewed the literature and described the management of incarcerated bilateral spigelian hernia. We also illustrated our challenges with the diagnostic process in the care of this patient.

## 2. Case Presentation

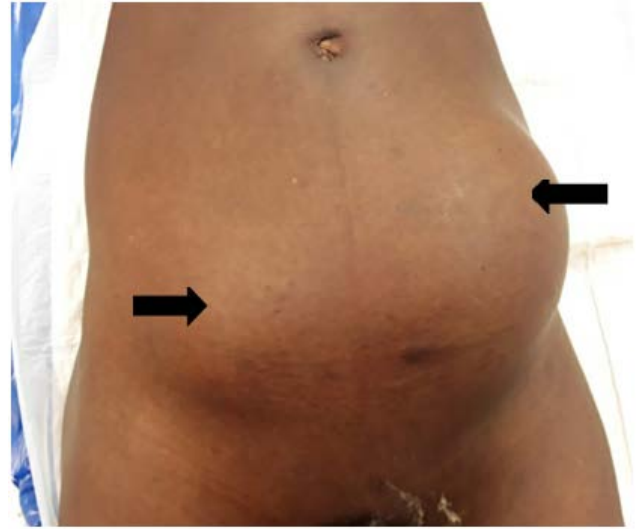A 42-year old female from the Northern part of Ghana presented with bilateral abdominal lumps associated with abdominal pain. She first noticed the abdominal lumps 15-years prior to presentation. The lumps became prominent any time she coughed or bears down. She observed a gradual increase in the size of the lumps over the years but was otherwise in good health. A week prior to presentation, she began to experience dull intermittent abdominal pain not associated with abdominal distension, fever, vomiting or constipation. She had 7 spontaneous

vaginal deliveries at home with the aid of a traditional birth attendant. She had her last delivery 7-years prior to presentation. She participates in farming activities because her husband is a peasant farmer. She had no past history of open or laparoscopic surgeries.

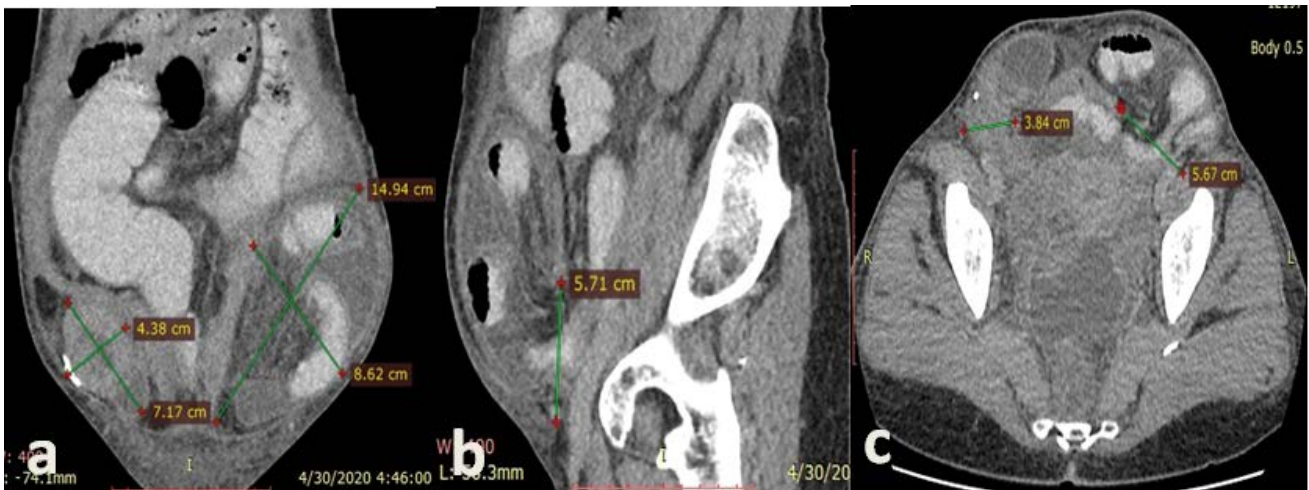
On examination, she was in good health, not obese, not in pain and was hemodynamically stable. Abdomen was full with 2 lumps on either side of the anterior abdominal wall below the umbilicus as shown in Figure 1. Each lump had a visible and palpable cough impulse. The lumps were both irreducible and were located below the umbilicus at the lateral border of the rectus abdominis muscles on both sides. The left lump measured 12×10cm while the right measured 6×4cm. Abdomen was soft and non-tender with normal bowel sounds. Rectal examination was unremarkable. Systemic examination was essentially normal.

Abdominopelvic ultrasound findings were inconclusive. A CECT scan showed a 5.71cm defect at the left iliac fossa region (through the spigelian fascia) with bowel loops and mesentery herniating through the defect into the hernia sac (measuring 14.94 x 8.62cm). The herniated bowel had normal caliber and contained oral contrast. A similar but smaller lesion was noted on the contralateral side with a defect of 3.84cm and hernia sac size of 7.17 x 4.38cm. It also contained bowel loops and mesenteric fat.

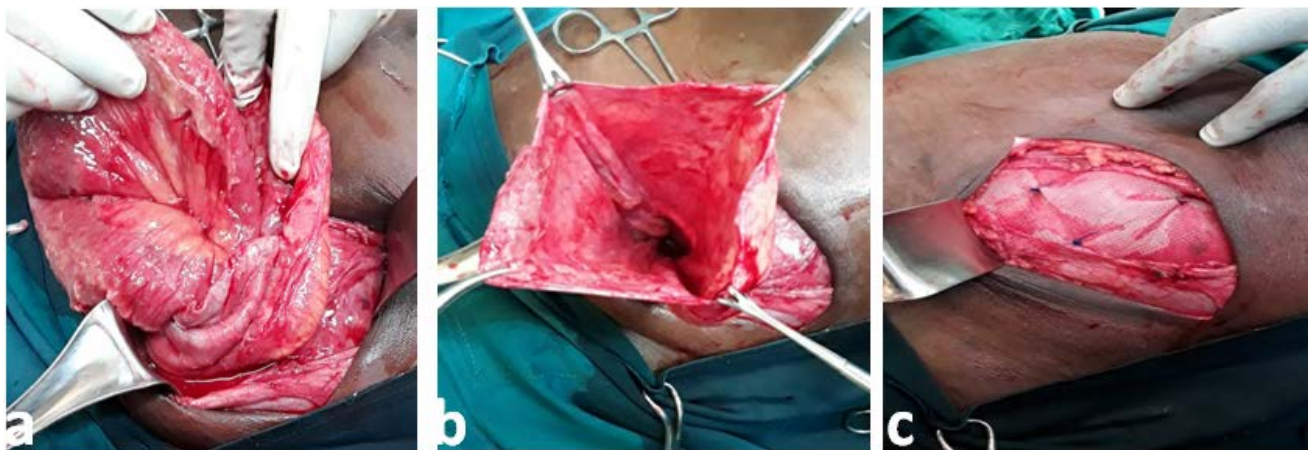These findings are illustrated in Figure 2a, Figure 2b and Figure 2c. Complete blood count and renal function tests were essentially normal. A diagnosis of Incarcerated Bilateral Spigelian Hernia was made and the patient counseled for immediate operative intervention.



**Figure 1.** Bilateral spigelian hernia showing abdominal lumps



**Figure 2.** Contrast enhanced abdominal CT scan showing bilateral spigelian hernia: (a) Coronal view showing content of sacs. (b) Sagittal view showing size of defect of left spigelian hernia. (c) Axial view showing spigelian fascia defect of 5.7cm on the left and 3.7cm on the right



**Figure 3.** (a) Peritoneal sac opened to expose content. (b) Peritoneal sac with content reduced (c) On-lay mesh repair

An open on-lay mesh repair was performed under general anesthesia with endotracheal intubation. A transverse abdominal skin incision was made over the lump on the left side. The incision was deepened with blunt and sharp dissections to expose external oblique aponeurosis. The aponeurosis was incised in the direction of its fibers to expose the transversalis fascia covering the peritoneal sac. The huge sac was then opened to reveal its content which was a viable ileum with thin fibrous adhesions at the neck of the sac. The content was reduced and the peritoneal defect closed. A polypropylene mesh was placed over the defect and the oblique muscles and held in place by nylon 3/0. Intraoperative images are shown in [Figure 3a](#), [Figure 3b](#) and [Figure 3c](#). The aponeurosis was closed with vicryl 3/0. The wound was closed in layers and skin closed with subcuticular sutures. A similar procedure was performed on the right side. The small hernia sac on the right side was found to contain viable ileum with thin fibrous adhesions at the neck. The patient had an uneventful recovery and was discharged on day 3 after surgery. At 2 weeks and 3 months follow up reviews, patient was in good health and wound healed with no complications.

### 3. Discussion

Spigelian hernias account for 0.12% of all abdominal wall hernias and 1-2% of all hernias presenting to the emergency [\[2,3\]](#). This makes it a rare clinical occurrence. The symptoms can be insidious, but pain and a lump in the abdominal wall are the commonest symptoms [\[4,6,7,8,9,10\]](#). Ussia et al illustrated herniation through previous trocar insertion points, so a high index of suspicion is needed in people with a history of laparoscopic procedures presenting with pain and no identifiable organ pathology [\[8\]](#).

The precipitating factors include advanced age, obesity, multiparity, previous laparoscopic surgeries and manual work [\[15\]](#). This patient was a middle-aged farmer who had undergone 7 spontaneous vaginal deliveries at home. She first noticed the lumps after her first delivery but did not report to a health facility because it did not bother her. Her subsequent pregnancies increased her intraabdominal pressure causing a further increase in the size of the lumps until her current presentation. In Northern Ghana, most men are peasant farmers, so it is common practice for their wives to assist them with farming activities. This manual work caused further increase in her intraabdominal pressure.

Spigelian hernia sometimes poses extreme diagnostic challenges to the physician, therefore delaying surgical intervention [\[2,4,5,7,9,10,11\]](#). A high index of suspicion combined with good clinical assessment is needed in order to make a diagnosis. After history and examination of the patient, the clinical suspicion was a bilateral spigelian hernia, but more evidence was needed to support this diagnosis and rule out possible differential diagnoses. Radiological imaging (ultrasonography and CECT scan) are essential in establishing diagnosis when clinical assessment is in doubt [\[4,9,11\]](#). An abdominopelvic ultrasound was done but its findings were inconclusive. It is worth noting that ultrasonography is operator dependent, and for that matter the diagnosis of rare clinical conditions

can be missed by inexperienced operators [\[9\]](#). An abdominopelvic CECT scan was done which clearly delineated the defects on the lateral border of the rectus abdominis. The contents of both sacs were loops of bowel with normal caliber containing oral contrast. This confirmed our suspicion of bilateral spigelian hernia.

The risk of complications of spigelian hernia is high [\[4,5,6,10,13\]](#) and for that reason the patient was counseled for immediate operative intervention. Larson and Farley reported the rate of incarceration and strangulation as 17% and 10% respectively [\[6\]](#). Both open operative and laparoscopic interventions are safe [\[7,14\]](#), but the latter has an added advantage of reducing morbidity and mortality [\[10\]](#). The hospital she was managed in is in a low-middle resource setting and does not have access to laparoscopy, for that reason she was offered an open on-lay mesh repair. She had an uneventful recovery and was discharged on postoperative day 3. Her wounds healed with no complications on subsequent follow up visits.

But for a high index of suspicion, a timely diagnosis would not have been made, resulting in needless complications and prolonged hospital stay. The key lesson here is for clinicians to constantly improve their clinical assessment skills so that rare conditions would not be missed. Novice and inexperienced sonographers should continuously update their knowledge on rare clinical conditions to avoid missed diagnosis.

### 4. Conclusion

Spigelian hernia is an uncommon clinical occurrence. Preoperative diagnosis can be challenging because of the vague nature of the symptoms. A high index of suspicion combined with good clinical assessment is required to make a diagnosis. Urgent operative intervention must be advised in all cases because of the risk of incarceration and strangulation.

### Funding

Authors did not receive funding for this manuscript

### Conflict of Interest

No conflict of interest with respect to authorship and publication of this case report.

### Abbreviations

CECT scan - Contrast enhanced Computed Tomography scan

IPOM - Intraperitoneal on-lay mesh

TAPP - Transabdominal Preperitoneal

TEP - Total Extraperitoneal

### Acknowledgements

We are grateful to Dr Nana Ansua Ababio and



Dr. Destine Tawiah for the excellent operative images, Nurse Rukaya I. Ibrahim and Nurse Colenta Duut for the care of patient and assisting with informed consent.

## References

- [1] Ghosh SK, Sharma S, Biswas S, Chakraborty S, Adriaan van den Spiegel (1578-1625): anatomist, physician, and botanist. *Clin Anat N Y N*. 2014 Oct; 27(7): 952-7.
- [2] Foster D, Nagarajan S, Panait L. Richter-type Spigelian hernia: A case report and review of the literature. *Int J Surg Case Rep*. 2014 Dec 11; 6: 160-2.
- [3] Parambath AN, Hajaji K, Al Hilil SA. Spigelian hernia with Richter-type herniation of the ileum: A rare cause of right iliac fossa pain mimicking acute appendicitis. *J Emerg Med Trauma Acute Care*. 2012 Dec; (2012): 7.
- [4] Mittal T, Kumar V, Khullar R, Sharma A, Soni V, Baijal M, et al. Diagnosis and management of Spigelian hernia: A review of literature and our experience. *J Minimal Access Surg*. 2008 Dec; 4(4): 95.
- [5] Spangen L. Spigelian hernia. *World J Surg*. 1989 Sep 1; 13(5): 573-80.
- [6] Larson DW, Farley DR. Spigelian Hernias: Repair and Outcome for 81 Patients. *World J Surg*. 2002 Oct 1; 26(10): 1277-81.
- [7] Zuvella M, Milicevic M, Galun D, Djuric-Stefanovic A, Bulajic P, Palibrk I. Spigelian hernia repair as a day-case procedure. *Hernia*. 2013 Aug 1; 17(4): 483-6.
- [8] Ussia A, Imperato F, Schindler L, Wattiez A, Koninckx PR. Spigelian hernia in gynaecology. *Gynecol Surg*. 2017 May 15; 14(1): 8.
- [9] Dowdy DJ, Fisher KL. Sonographic Assessment of a Spigelian Hernia. *J Diagn Med Sonogr*. 2017 Sep 1; 33(5): 434-8.
- [10] Martell EG, Singh NN, Zagorski SM, Sawyer MAJ. Laparoscopic Repair of a Spigelian Hernia: A Case Report and Literature Review. *JLS*. 2004; 8(3): 269-74.
- [11] Zaragoza C, Peiró F, Bebek H, Castaño S, García Aguado R, Vivó M, et al. Spigelian hernia: ambulatory surgical treatment. *Ambul Surg*. 2001 Oct 1; 9(3): 127-9.
- [12] Thomasset SC, Villatoro E, Wood S, Martin A, Finlay K, Patterson JE. An unusual Spigelian hernia involving the appendix: a case report. *Cases J*. 2010 Jan 13; 3(1): 22.
- [13] Zacharakis E, Papadopoulos V, Ganidou M, Zacharakis E. Incarcerated Spigelian hernia: a case report. *Med Sci Monit Int Med J Exp Clin Res*. 2006 Jul; 12(7): CS64-66.
- [14] Celdrán A, Señaris J, Mañas J, Frieyro O. The open mesh repair of Spigelian hernia. *Am J Surg*. 2007 Jan 1; 193(1): 111-3.
- [15] Shenoy KR, Shenoy A. *Manipal Manual of Surgery 4Ed* [Internet]. Main Website. [cited 2020 May 23]. Available from: <http://www.cbspd.co.in/manipal-manual-of-surgery-4ed-9788123924168-k-r-shenoy.html>.



© The Author(s) 2020. This article is an open access article distributed under the terms and conditions of the Creative Commons Attribution (CC BY) license (<http://creativecommons.org/licenses/by/4.0/>).