

MFSD8 Mutation Causing Neuronal Ceroid Lipofuscinosis Type 7 in a Bangladeshi Patient: A Rare Case Report and Review of Literature

Bithi Debnath^{1,*}, Ramesh Chandra Nath², Sheikh Azimul Hoque¹, Narayan Chandra Saha¹

¹Department of Pediatric Neurology, National Institute of Neurosciences and Hospital, Dhaka-1207

²Barishal Medical College Hospital, Barishal, Bangladesh

*Corresponding author: Bangladesh.bithidebnath@gmail.com

Received August 13, 2020; Revised September 16, 2020; Accepted September 25, 2020

Abstract The neuronal ceroid lipofuscinoses (NCLs) are a heterogeneous group of inherited neurodegenerative disorders. Their unifying clinical hallmarks are seizures, visual loss, myoclonus, ataxia, cognitive and motor regression which lead to early death. Based on the clinical onset of symptoms NCL-affected individuals have been classified into six categories. Fourteen genetic forms of NCL (CLN1 to CLN14) have been identified so far. The variant late-infantile form of the disease has been linked to CLN5, CLN6, CLN7 (MFSD8) and CLN8 mutations. We report a patient of 9 years from a consanguineous family who presented with progressive visual loss and seizures. Clinical Exome sequencing reveals a homozygous missense mutation in exon 11 of the *MFSD8* gene (c.1235C>T, p.Pro412Leu). To our knowledge, this is the first report of MFSD8 gene mutation in a Bangladeshi patient with variant late-infantile NCL. This study also provides information regarding the phenotypic and molecular spectrum of CLN7 disease.

Keywords: Neuronal ceroid lipofuscinosis (NCL), MFSD8, CLN7, Variant late-infantile NCL, visual loss, exome sequencing

Cite This Article: Bithi Debnath, Ramesh Chandra Nath, Sheikh Azimul Hoque, and Narayan Chandra Saha, "MFSD8 Mutation Causing Neuronal Ceroid Lipofuscinosis Type 7 in a Bangladeshi Patient: A Rare Case Report and Review of Literature." *American Journal of Medical Case Reports*, vol. 8, no. 12 (2020): 508-511. doi: 10.12691/ajmcr-8-12-21.

1. Introduction

The neuronal ceroid lipofuscinoses (NCLs) are the most common inherited pediatric neurodegenerative disorders characterized by accumulations of auto fluorescent lysosomal storage material in the central nervous system as well as in many other organs and tissues [1,2]. Pattern of inheritance is autosomal recessive but autosomal dominant has also been reported in one adult-onset form [3]. The NCLs have a worldwide distribution, but their incidence rates may vary from 1:67000 in Italy and Germany to 1:14000 in Iceland, and their prevalence rates from 1:1,000,000 in some regions to 1:100,000 in the Scandinavian countries [1]. Although the age of presentation is variable, the most common childhood forms are characterized by progressive loss of vision, mental and motor deterioration, epileptic seizures and early death [4].

Based on the age of onset and clinical presentation, NCLs have been classified into six categories (congenital, infantile, late infantile, variant late infantile, juvenile

and adult [5]. Fourteen genetically distinct human NCLs genes (CLN1 to CLN14) have been described to date [4,6] with a report of more than 360 NCL-causing mutations, most of which have been included in the NCL Mutation Database (<http://www.ucl.ac.uk/ncl/mutation>) [7].

The variant late infantile form of the disease has been linked to CLN5, CLN6, CLN7 and CLN8 mutations [4,8]. Homozygous or compound heterozygous mutations in the MFSD8 gene (MIM 611124) cause a particular variant called the Turkish variant LINCL (vLINCL), characterized by a later age of onset and a more severe seizure phenotype. The MFSD8 (CLN7) gene, which is located on chromosome 4q28.1–q28.2, encodes for the MFSD8 (major facilitator superfamily domain-containing protein 8) protein [9].

In this study we analyzed clinical and genetic characteristics of a 9-year-old boy from a consanguineous family who presented with visual loss and epilepsy. Clinical-exome sequencing identified the MFSD8 pathogenic mutations and helped to define the clinical and molecular diagnosis precisely. This case report also provides further information regarding the CLN7 phenotype in a Bangladeshi child.

2. Case Presentation

This patient was a boy of 9 years from Bangladesh. He presented with progressive loss of vision and seizures for 4 years. He was born out of consanguineous marriage with average birth weight and had unremarkable prenatal, perinatal and postnatal history. His parents and other sibs are clinically healthy. Patient had normal developmental milestones and did his schooling at the age of 5 year. Since 6 years of age, his parents noticed visual loss for which he used to bump into objects and people while walking. Gradually the visual loss progressed so much that he could hardly do any activities without assistance. At the age of 7 years, he developed generalized tonic-clonic and later myoclonic type of seizures of several episodes for which he was put on antiepileptic drugs. With time, there was progressive deterioration of intelligence and behavioral changes. However, his motor activities, speech, hearing and communication skills remained unaffected. There was no history of motor weakness, abnormal movements, fever, loss of consciousness, trauma or any chronic illness.

On general examination, the patient had normal physical development: he was 25.5 kg in weight and 123 cm in height. Head was normal in shape and the head circumference was 51.5 cm (normal). His vitals were within normal limit. There were no neurocutaneous markers. Patient was conscious and oriented in time, place and person. Speech was normal too. On cranial nerve examination, his vision was limited to perception of light (PL) and projection of rays (PR) on both eyes. Both the

pupils were normal in size and reacting to light. Examination of fundus revealed bilateral pale optic disc, arteriolar attenuation and peripheral retinal pigmentary changes (Figure 1). Other cranial nerve examination revealed no abnormality. Motor and sensory examination revealed no abnormality. Gait was normal and there were no cerebellar signs. The rest of systemic examination including respiratory, cardiovascular and abdominal examination was normal.

On laboratory examination complete hemogram, biochemical parameters like liver, renal, thyroid functions and basic metabolic screening were within normal limit. His electroencephalogram (EEG) showed focal epileptiform discharges on a slow background (Figure 2). Brain MRI of the patient after admission showed mild cerebellar atrophy (Figure 3).

In the hospital, we continued the previous treatment with anticonvulsant drugs: sodium valproate (40 mg/kg), clobazam (0.5 mg/kg) and levetiracetam (50 mg/kg) as seizure was controlled.

Clinical exome sequencing was carried out by MedGenome Labs Ltd. Bangalore, India. DNA extracted from blood was used to perform targeted gene capture using a custom capture kit. The libraries were sequenced to mean >80-100X coverage on Illumina sequencing platform. A homozygous missense variation in exon 11 of the *MFSD8* gene (**chr4:g.127921639G>A; Depth:230x**) that results in the amino acid substitution of Leucine for Proline a codon 412 (**p.Pro412Leu; ENST00000641686.1**) was detected.

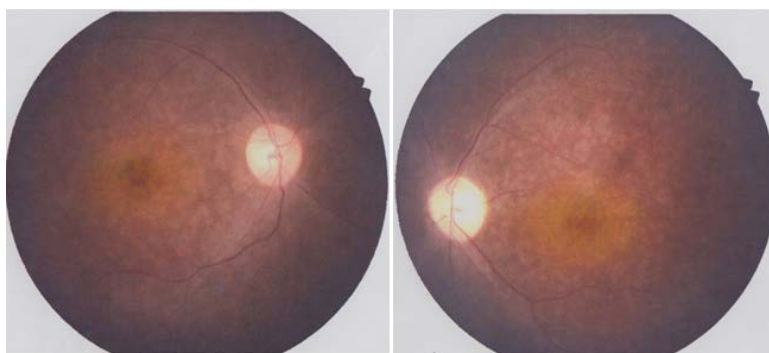


Figure 1. Fundus of the patient showing pale disc, arteriolar attenuation and peripheral retinal pigmentary changes

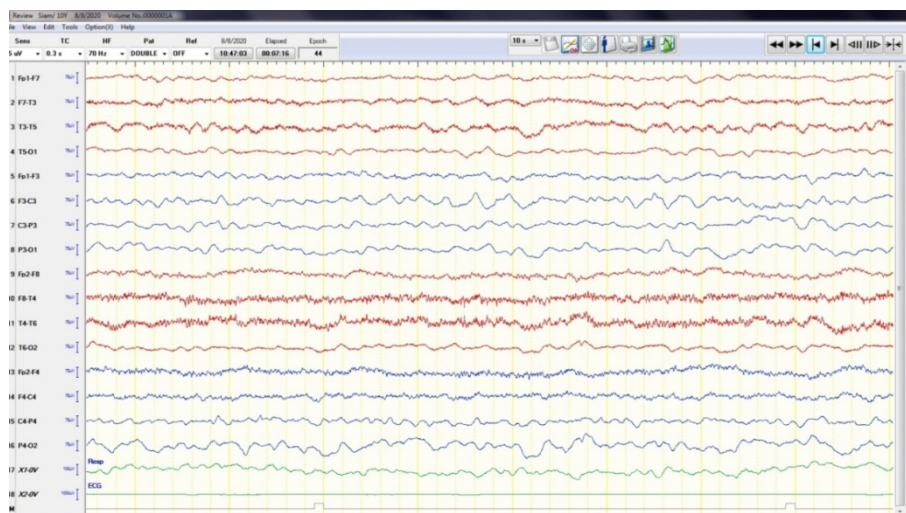


Figure 2. EEG in awake state showing diffuse slow background activities

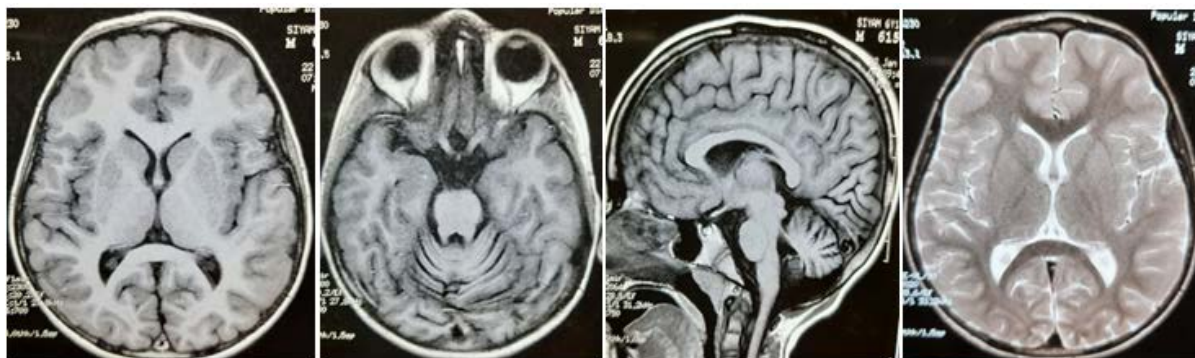


Figure 3. MRI of brain showing cerebellar atrophy

3. Discussion

In this study, we described a boy of 9-year old who presented with progressive visual loss. The disease onset was at 6 years of age followed by seizure and behavioral changes 1 year later. Such features with a family history of consanguinity, were clinically suggestive of a recessive late infantile onset form of neuronal ceroid lipofuscinosis. However, a single candidate gene could not be selected for direct sequencing, since CLN2, CLN5, CLN6, CLN7 and CLN8 patients may share clinical features to those presented by our patient. This would have meant that definitive molecular diagnosis by direct sequencing would have been time-consuming and expensive. Whole-exome sequencing is a cost-effective approach to establishing a molecular diagnosis of Mendelian recessive diseases, particularly when mutations in distinct genes are related to overlapping phenotypes [10,11].

We have identified the underlying genetic defect as a homozygous missense mutation in the MFSD8 in exon 11, c.1235C>T (**p.Pro412Leu**), the latest member of an expanding list of genes linked to NCL. MFSD8 gene. It is located on chromosome 4q28.1-q28.2, encodes CLN7, a putative lysosomal transporter with suggested topology of 12 transmembrane domains that was shown to be localized to the lysosomal membrane and belongs to the major facilitator superfamily (MFS) [12]. Although this protein is ubiquitously expressed, high transcript concentrations have been identified in several brain locations, such as cerebellar cortex and hippocampus [13].

Mutations in MFSD8 gene were initially reported in 2007 as an important cause of vLINCL in patients of

Turkish origin [9]. Since then 38 mutations in MFSD8 were described, most being homozygous missense mutations [14]. This mutation predominantly lead to NCL7 disease - subtype of vLINCL form. The phenotypic presentation varies from patient to patient. In Turkish variant, the mean age of disease onset ranged from 2-7 years. Seizures, ataxia or psychomotor impairment was the most common presenting symptoms, while vision loss developed later, and most patients became non-ambulatory within 2 years after onset [9]. Another study of three children (siblings) from an Arab Palestinian consanguineous family with vLINCL found the disease onset at 3-4 years of age where the presenting symptoms were ataxia and motor regression. Seizure and visual deterioration developed later [15]. A 5 year-old girl from Russia initially (2.5 years) presented with Rett like symptoms. Later she faced motor regression and visual failure [16]. Stogmann et al. reported the Egyptian family of 5 members where no visual impairment was found [17]. Our case is different from above mentioned phenotypes. He first faced visual problem, does not develop ataxia, motor or speech regression. Another case series reported by Mandel et al. reported that their patients had disease onset at 5-7 years, mental and motor regression at 8-10 years, and death between 14 and 23 years [18]. Aldahmesh et al. reported Saudi individuals with vLINCL. The onset of poor vision was at around the age of 6-7 years with progression to blindness within 2 years from the onset of the disease. Seizures and cognitive decline started around the age of 8 years [19]. The Phenotypes of that study are very similar to our case. Clinical profile and MFSD8 mutations of NCL patients are summarized in Table 1.

Table 1. Summary of NCL patients with MFSD8 mutations

Location	Nucleotide change	Amino acid change	Age of onset (years)	Clinical feature (s)	Reference
exon 5	c.362A>G	p.Y121C	5	Seizures	Stogmann et al. [17]
exon 7	c.697A>G	p.R233G	5	Seizures	Siintola et al. [9]
Intron 8	c.754+2T>A	Altered splicing	2-3	Seizures	Siintola et al. [9]
exon 10	c.894T>G	p.Y298X	3-4	developmental delay, ataxia, clonic seizures, mild cerebellar atrophy	Siintola et al. [9]
exon 10	c.929G>A	p.G310D	6	Seizures	Siintola et al. [9]
exon 11	c.1102G>C	p.D368H	3.5	Speech delay, ataxia, sleep disorders, cerebellar atrophy.	Siintola et al. [9]
exon 12	c.1286G>A	p.G429D	5	Motor impairment	Siintola et al. [9]
exon 12	c.1398C>T	p.P412L	6	Visual loss, seizure	Aldahmesh et al [19]
exon 11	c.1235C>T	p.P412L	6	Visual loss, seizure	This study

EEG findings of previous studies found background slowing, focal, multifocal or generalized epileptiform discharges. [15,16,17,18] The radiological findings of NCL are early white matter changes, cerebral and cerebellar atrophy. The presence of thalamic and basal ganglia changes support the diagnosis of vLINCL in comparison to LINCL [20,21,22]. EEG of our case revealed diffuse slow background activities with focal spikes. MRI of brain shows mild cerebellar atrophy.

NCLs remain a challenge for pediatric neurologists, because clinical signs in children are subtle and often overlap with other neurodegenerative diseases, such as mitochondrial disorders, leukodystrophy, Rett syndrome or early-onset Parkinsonism. The clinical data of our patient and the few others that have previously been reported showed that phenotype associated with MFSD8 mutations is fairly consistent. The observed variation c.1235C>T (**p.Pro412Leu**) in our case has previously been reported (as c.1398C>T) in patients affected with NCL [19]. The same missense mutations in this study and that by Aldahmesh et al. result in a very similar phenotype. P412L was causal for the vLINCL phenotype observed in both the studies. The clinical and molecular aetiology of the patient might be useful for future genotype-phenotype correlations.

4. Conclusion

This report describes the first case of NCL7 in Bangladesh. NCL should be suspected in patients with progressive visual failure and seizure. Exome sequencing is a powerful tool for pediatric NCLs for early and accurate diagnosis. Although there is no treatment for this condition, correct and early diagnosis will allow proper genetic counseling and future family planning especially in communities with high rate of consanguineous marriage.

References

- [1] Mole SE, Williams RE, Goebel HH. *The Neuronal Ceroid Lipofuscinoses (Batten Disease)*, second edition, Oxford University Press, Oxford, UK, 2011, pp. 361-365.
- [2] Wisniewski KE, Zhong N, *Batten Disease: Diagnosis, Treatment, and Research*, Academic Press, NY, 2001.
- [3] Nosková L, Stránecký V, Hartmannová H, Přistoupilová A, Barešová V, Ivánek R, et al. Mutations in DNAJC5, encoding cysteine-string protein alpha, cause autosomal-dominant adult-onset neuronal ceroid lipofuscinosis. *Am J Hum Genet.* 2011; 89(2): 241-52.
- [4] Haltia M, Goebel HH. The neuronal ceroid-lipofuscinoses: a historical introduction. *Biochim Biophys Acta* 2013; 1832(11): 1795-1800.
- [5] Mole SE, Williams RE, Goebel HH. Correlations between genotype, ultrastructural morphology and clinical phenotype in the neuronal ceroid lipofuscinoses. *Neurogenetics* 2005; 6(3): 107-126.
- [6] Williams RE, Mole SE (2012) New nomenclature and classification scheme for the neuronal ceroid lipofuscinoses. *Neurology* 2012; 79(2): 183-191.
- [7] Kousi M, Lehesjoki AE, Mole SE. Update of the mutation spectrum and clinical correlations of over 360 mutations in eight genes that underlie the neuronal ceroid lipofuscinoses. *Hum Mutat* 2012; 33(1): 42-63.
- [8] Jalanko A, Braulke T. Neuronal ceroid lipofuscinoses. *Biochim Biophys Acta* 2009; 1793(4): 697-709.
- [9] Siintola E, Topcu M, Aula N, Lohi H, Minassian BA, Paterson AD, Liu XQ, Wilson C, Lahtinen U, Anttonen AK et al. The novel neuronal ceroid lipofuscinosis gene MFSD8 encodes a putative lysosomal transporter. *Am J Hum Genet* 2007; 81(1): 136-146.
- [10] Bamshad MJ, Ng SB, Bigham AW, Tabor HK, Emond MJ, et al. Exome sequencing as a tool for Mendelian disease gene discovery. *Nat Rev Genet* 2011; 12(11): 745-755.
- [11] Ortega-Recalde O, Vergara JL, Fonseca DJ, Rios X, Mosquera H, et al. Whole-exome sequencing enables rapid determination of xeroderma pigmentosum molecular etiology. *PLoS One* 2013; 8(6): e64692.
- [12] Pao SS, Paulsen IT, Saier MH Jr. Major facilitator superfamily. *Microbiol Mol Biol Rev.* 1998;62(1):1-34.
- [13] Sharifi A, Kousi M, Sagné C, Belenchi GC, Morel L, Darmon M, et al. Expression and lysosomal targeting of CLN7, a major facilitator superfamily transporter associated with variant late-infantile neuronal ceroid lipofuscinosis. *Hum Mol Genet.* 2010; 19(22): 4497-514.
- [14] NCL mutation and patient Database <https://www.ucl.ac.uk/ncl/mutation.shtml>. Accessed 1 June 2018.
- [15] Kentab AY. MFSD8 mutation causing variant late infantile neuronal ceroid lipofuscinosis (vLINCL) in three Palestinian siblings of Arab Descent. *Curr Pediatr Res* 2017; 21 (2): 190-196.
- [16] Kozina AA, Okuneva EG, Baryshnikova NV, Krasnenko AY et al. A novel MFSD8 mutation in a Russian patient with neuronal ceroid lipofuscinosis type 7: a case report. *BMC Medical Genetics* 2018; 19:151.
- [17] Stogmann E, El Tawil S, Wagenstaller J, et al. A novel mutation in the MFSD8 gene in late infantile neuronal ceroid lipofuscinosis. *Neurogenetics* 2009; 10: 73-77.
- [18] Mandel H, Cohen Katsanelson K, Khayat M, et al. Clinico-pathological manifestations of variant late infantile neuronal ceroid lipofuscinosis (vLINCL) caused by a novel mutation in MFSD8 gene. *Eur J Med Genet* 2014; 57: 607-612.
- [19] Aldahmesh MA, Al-Hassnan ZN, Aldosari M, et al. Neuronal ceroid lipofuscinosis caused by MFSD8 mutations: a common theme emerging. *Neurogenetics* 2009; 10: 307-311.
- [20] Sayit E, Yorulmaz I, Bekis R, et al. Comparison of brain perfusion SPECT and MRI findings in children with neuronal ceroid-lipofuscinosis and in their families. *Ann Nucl Med* 2002; 16: 201-206.
- [21] Seitz D, Grodd W, Schwab A, et al. MR imaging and localized proton MR spectroscopy in late infantile neuronal ceroid lipofuscinosis. *AJNR Am J Neuroradiol* 1998; 19: 1373-1377.
- [22] Petersen B, Handwerker M, Huppertz HI. Neuroradiological findings in classical late infantile neuronal ceroid-lipofuscinosis. *Pediatr Neurol* 1996; 15: 344-347.

