

# Sturge-Weber Syndrome: A Boy with Port-wine Stain and Seizure

Maliha Hakim\*, Mashfiqul-Hasan, Mahmudul Islam, Mohammad Akter Hossain,  
Jobaida Naznin, Saifur Rahman Khan

Department of Neurology, National Institute of Neurosciences and Hospital, Dhaka, Bangladesh  
\*Corresponding author: [drmalihahakim@yahoo.com](mailto:drmalihahakim@yahoo.com)

Received April 10, 2019; Revised May 20, 2019; Accepted June 16, 2019

**Abstract** Neurocutaneous disorders are a heterogeneous group of genetic disorders that include Sturge-Weber syndrome (SWS), which is characterized by congenital capillary-venous malformation manifesting as port-wine stain, leptomeningeal angiomas and ocular angiomas. Diagnosis is made when at least two of these three areas are involved. Abnormal vessels lead to stasis and congestion resulting in decreased regional perfusion and eventually cause hypoxic brain injury with neuronal loss and gliosis. Seizures are common neurological manifestation in SWS patients and many patients have intractable seizures, eventually leading to motor deficits or developmental and cognitive delays. Here we report a case of a 16-year-old boy who presented with typical port-wine stain and seizure disorder since childhood. Neuroimaging revealed evidence of cerebral vascular malformation ipsilateral to the cutaneous lesion. Seizure was controlled with antiepileptic drugs. Early diagnosis and prompt treatment may reduce the incidence of neurologic sequelae. Proper counselling is necessary to improve compliance.

**Keywords:** Sturge-Weber syndrome, seizure, port-wine stain

**Cite This Article:** Maliha Hakim, Mashfiqul-Hasan, Mahmudul Islam, Mohammad Akter Hossain, Jobaida Naznin, and Saifur Rahman Khan, "Sturge-Weber Syndrome: A Boy with Port-wine Stain and Seizure." *American Journal of Medical Case Reports*, vol. 7, no. 7 (2019): 121-124. doi: 10.12691/ajmcr-7-7-1.

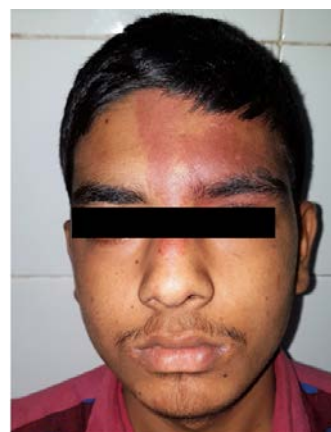calcifications observed in advanced cases of SWS [8].

## 1. Introduction

Sturge-Weber syndrome (SWS) is characterized by port-wine stain, leptomeningeal angiomas and ocular angiomas [1,2]. Port-wine stain is nothing but a congenital capillary-venous malformation manifesting as pink or purple birthmark on one side of head, face or neck. To diagnose SWS, at least two of these three criteria are needed [3]. The frequency of this rare syndrome worldwide is 1 in 50000 and a somatic activating mutation of the guanine nucleotide-binding protein alpha (GNAQ) is observed to be attributable to this condition [2,4]. One of the commonest features of the condition is Epilepsy that occurs in 72% and 90% of cases of SWS with unilateral and bilateral cerebral involvement respectively [5,6].

SWS is included in a heterogeneous group of genetic disorders called neurocutaneous disorders. As the name implies, these disorders are characterized by involvement of the cutaneous as well as nervous systems. Examples of such condition are Tuberous sclerosis complex (TSC), neurofibromatosis type I (NF1), and Sturge-Weber syndrome (SWS). The common mechanism of these disorders is developmental dysfunctions caused by genetic mutations in cell growth regulating pathways of brain, skin and other organs [7]. Although first described by Schirmer in 1860, description of SWS was provided by Sturge 19 years later. Weber, Dimitri and Wissing added to our knowledge by describing the typical gyriform

## 2. Case Presentation



**Figure 1.** Port-wine stain distributed along left ophthalmic division of trigeminal nerve

A 16-year-old boy presented to our department with history of recurrent focal motor seizure involving right side of the body with secondary generalization. Seizure started at the age of 4 years. He was treated with several anti-epileptic drugs including carbamazepine and levetiracetam, but compliance was poor and seizure remained uncontrolled, occurring in clusters with long seizure free period in between. Parents of the boy noticed reddish facial

discoloration at birth involving left upper part of face since birth. He is the first issue of consanguineous marriage, delivered normally at full term. Perinatal history was unremarkable and developmental milestones were age appropriate, but his school performance was poor.

During admission to hospital the boy was drowsy, right hemiparetic along with typical port-wine stain distributed along left ophthalmic division of trigeminal nerve (Figure 1). The hematological and biochemical profile including cerebrospinal fluid study was normal. Computed tomography of head revealed calvarial thickening with mild atrophy of left cerebral hemisphere (Figure 2). Magnetic resonance imaging (MRI) with contrast revealed left cerebral parenchymal shrinkage with intense enhancement

of basal cisterns and cortical-subcortical branching of vascular channels in left side suggesting vascular malformation in the form of leptomeningeal angiomatosis (Figure 3). Interictal electroencephalogram (EEG) was normal. Ophthalmological evaluation was done but there was no evidence of ocular involvement (Figure 4).

After admission he was treated with intravenous phenytoin and levetiracetam. Progress was satisfactory, seizure was controlled and his residual neurological deficit resolved within twenty four hours. The boy was discharged on oral levetiracetam with counselling to parents regarding the nature of the disease and importance of drug compliance. Now he is doing well and is under regular follow-up.

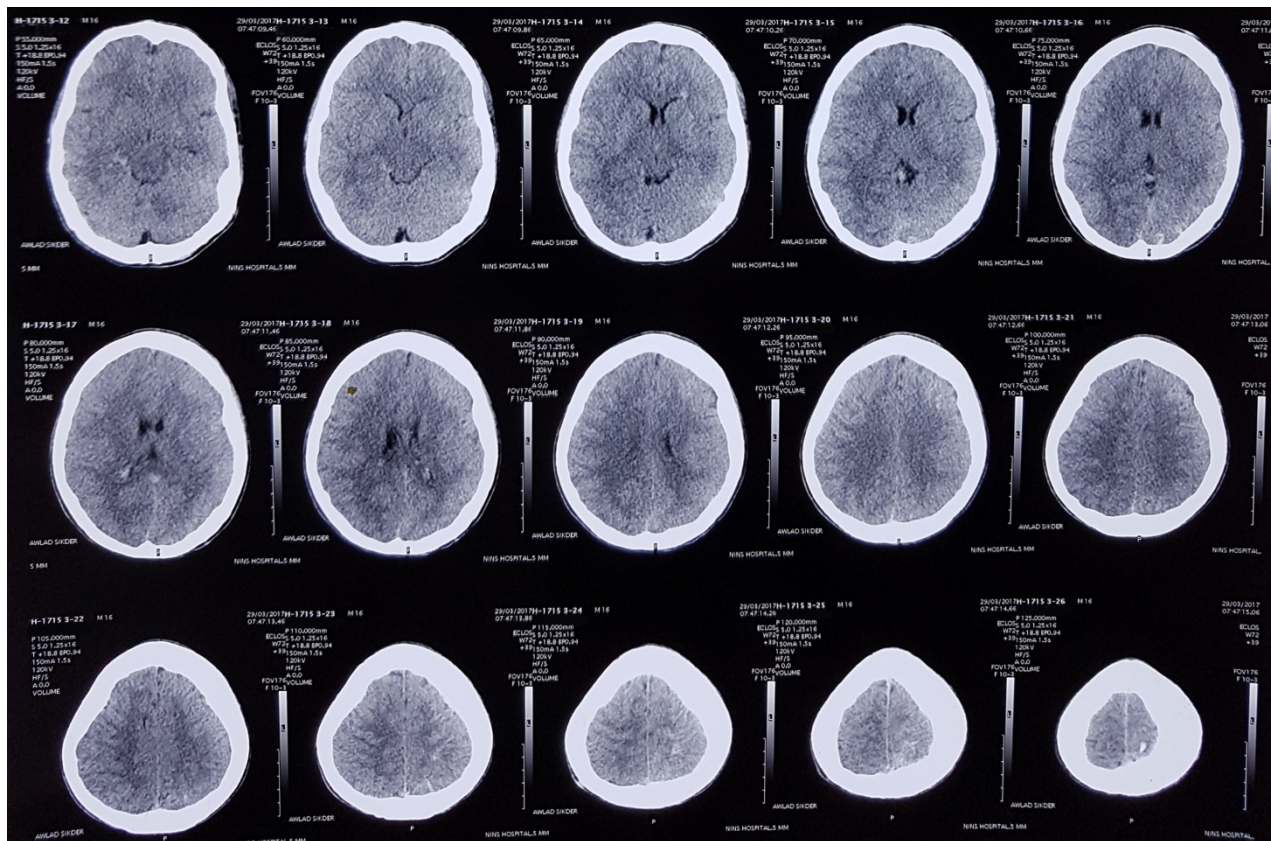


Figure-2. Computed tomography of head revealed left calvarial thickening with mild atrophy of left cerebral hemisphere

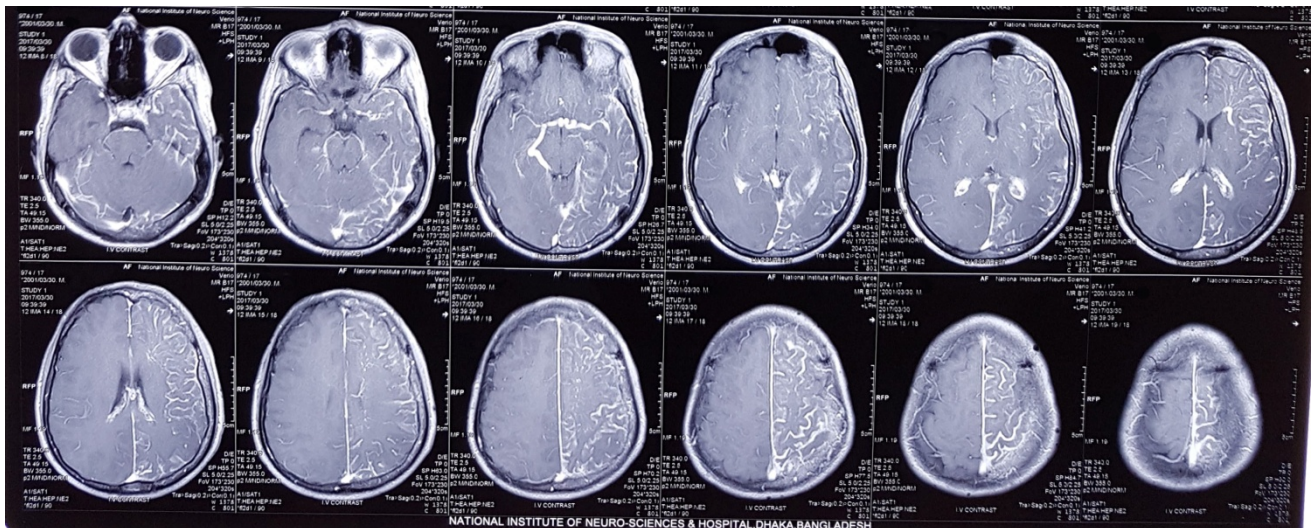
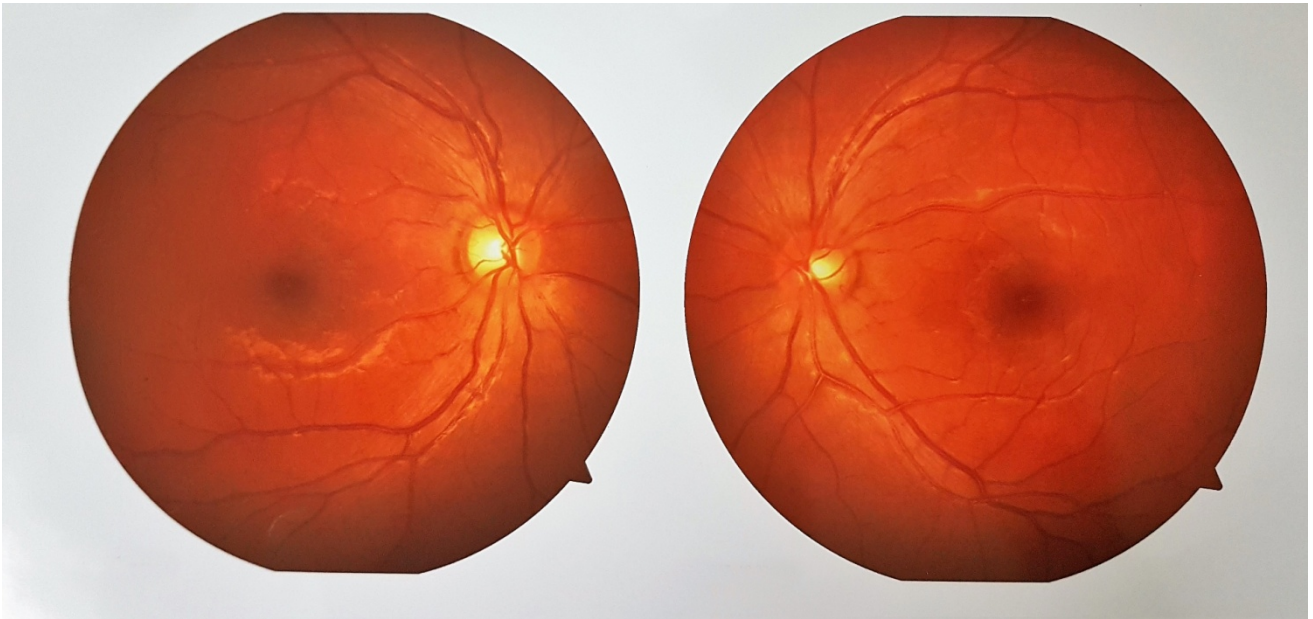


Figure 3. MRI of brain with contrast (axial T2 weighted image) revealed evidence of left cerebral hemiatrophy with leptomeningeal angiomatosis



**Figure 4.** Colour fundal photography of the patient showing normal findings

### 3. Discussions

Leptomeningeal angiomas of SWS tend to involve the occipital and posterior parietal region. They usually occur on the same side of facial nevus but the degree of involvement is variable [9]. Most common neurological symptoms are focal motor seizures which may be intractable and may lead to motor deficits or developmental and cognitive delay in children [10]. Three out of four patients develop epilepsy and may develop status epilepticus with prolonged weakness on one side of the body [1,11]. Clusters of seizures, separated by many months or years of seizure free period, are also common [12]. Nevertheless, prior to diagnosing a seizure patient with port-wine stain as SWS, other causes of seizure always need exclusion [13,14,15]. Abnormal blood vessel in SWS is thought to be important in development of epilepsy in SWS. Anomalous vessels bring about stasis and congestion, which reduces regional perfusion and ultimately causes hypoxic insult to the brain with neuronal damage and gliosis [16]. Brain calcifications develop faster in children with early onset epilepsy and may designate a risk for worse neurocognitive consequence [17].

Cutaneous vascular aberration commonly occurs due to a surplus of capillaries in forehead and eyelid following the distribution of 1<sup>st</sup> or 1<sup>st</sup> and 2<sup>nd</sup> divisions of the trigeminal nerve [1]. Depending on skin complexion it can differ from light pink to deep purple. SWS should be assumed in any newborn with a port-wine stain along the ophthalmic division of trigeminal nerve. A port-wine stain of any size in typical area has around 10-20% risk of SWS brain involvement. The risk rises with the size, magnitude and bilaterality of the birthmark [10,18]. Ophthalmological scrutiny is essential to detect and treat ocular involvement like choroidal angioma. Half of the affected persons may suffer with glaucoma [1].

Our patient had first seizure at age of four year. He had history of poor school performance and right hemiparesis at presentation. Computed tomography of head typically shows calvarial thickening but gyriform calcifications was

not observed which may require further period to develop. He had left cerebral atrophy demonstrated on MRI. Despite being treated with anti-epileptic drugs by several physicians, the compliance was not good and seizure was not controlled. Proper counselling and regular follow up was ensured to improve the compliance and control of seizure. Treatment targets primarily on seizure control. Surgical resection is indicated only rarely in refractory cases. Seizure control is critical for psychological and cognitive wellbeing, long term neurological consequence and quality of life [4,19]. Low-dose aspirin has been used empirically in SWS as venous stasis and microvascular thrombosis possibly contribute to neurologic decline [20].

### 4. Conclusion

Patients with port-wine lesions over the face, especially along the first division of trigeminal nerve, should be evaluated for SWS. Early diagnosis and prompt treatment may reduce the incidence of neurologic sequelae. Proper counselling is necessary to improve compliance.

### References

- [1] Lindsay KW, Bone I, Fuller G. Neurology and neurosurgery illustrated. 5<sup>th</sup> edition, Edinburgh, Churchill Livingstone Elsevier; 2010. Neurocutaneous syndromes; p. 561-63.
- [2] Thomas-Sohl KA, Vaslow DF, Maria BL. Sturge-Weber syndrome: a review. *Pediatr Neurol.* 2004; 30(5): 303-10.
- [3] Catherine DB, Anne MC. Sturge-Weber syndrome. *Curr Treat Options Neurol.* 2013; 15(5): 607-17.
- [4] Shirley MD, Tang H, Gallione CJ, Baugher JD, Frelin LP, Cohen B et al. Sturge-Weber syndrome and port-wine stains caused by somatic mutation in GNAQ. *N Engl J Med* 2013; 368(21): 197-9.
- [5] Bebin EM, Gomez MR. Prognosis in Sturge-Weber disease: comparison of unihemispheric and bihemispheric involvement. *J Child Neurol* 1988; 3(3): 181-4.
- [6] Jagtap S, Srinivas G, Harsha KJ, Radhakrishnan N, Radhakrishnan A. Sturge-Weber syndrome: clinical spectrum, disease course, and outcome of 30 patients. *J Child Neurol* 2013; 28(6): 725-31.

- [7] Pilli VK, Behen ME, Hu J, Xuan Y, Janisse J, Chugani HT, Juhász C. Clinical and metabolic correlates of cerebral calcifications in Sturge-Weber syndrome. *Dev Med Child Neurol*. 2017 Apr 11.
- [8] Jeevankumar B, Thapa DM. Sturge Weber syndrome: A report of three cases. *Indian J Dermatol* 2001; 46(3):185-87.
- [9] Comi AM. Pathophysiology of Sturge-Weber syndrome. *J Child Neurol* 2003; 18: 509e16.
- [10] Ch'ng S, Tan ST. Facial port-wine stains clinical stratification and risks of neuro-ocular involvement. *J Plast Reconstr Aes* 2008; 61, 889-93.
- [11] Maria BL, Neufeld JA, Rosainz LC, et al. Central nervous system structure and function in Sturge-Weber syndrome: evidence of neurologic and radiologic progression. *J Child Neurol* 1998; 13:606-618.
- [12] Kossoff EH, Ferenc L, Comi AM. An infantile-onset, severe, yet sporadic seizure pattern is common in Sturge-Weber syndrome. *Epilepsia* 2009; 50: 2154-2157.
- [13] Satyarthee GD, Mahapatra AK. Seizure as presentation of pituitary adenomas; series of four cases. *Neurosciences Today* 2002; 6: 167-169.
- [14] Rishabh Pasricha, Satyarthee GD. Seizure occurrence in spinal dysraphism operated cases: series of four cases with Literature Review. *American J Clinic Neurol Neurosurg* 2015; 2: 41-44.
- [15] Gupta DK, Satyarthee GD, Sharma MC, Mahapatra AK. Hypothalamic glioma presenting with seizures. A case report and review of the literature. *Pediatr Neurosurg* 2006; 42(4): 249-53.
- [16] Pinto A, Sahin M, Pearl PL. Epileptogenesis in neurocutaneous disorders with focus in Sturge-Weber syndrome. *F1000Res* 2016; 5: 370.
- [17] Stafstrom CE, Staedtke V and Comi AM. Epilepsy mechanisms in neurocutaneous disorders: tuberous sclerosis complex, neurofibromatosis type 1, and Sturge-Weber syndrome. *Fron. Neurol* 2017; 8:87.
- [18] Tallman B, Tan OT, Morelli JG, et al. Location of port-wine stains and the likelihood of ophthalmic and/or central nervous system complications. *Pediatrics* 1991; 87: 323-327.
- [19] Comi AM. Update on Sturge-Weber syndrome: diagnosis, treatment, quantitative measures, and controversies. *Lymphat Res Biol* 2007; 5 (4): 257-64
- [20] Garcia JC, Roach ES, McLean WT. Recurrent thrombotic deterioration in the Sturge-Weber syndrome. *Childs Brain* 1981; 8: 427-433.



© The Author(s) 2019. This article is an open access article distributed under the terms and conditions of the Creative Commons Attribution (CC BY) license (<http://creativecommons.org/licenses/by/4.0/>).