

# Neglected Congenital Muscular Torticollis: Dramatic Impact on Craniofacial Growth

Aziz Zakaria<sup>1,\*</sup>, Ibnouelghazi Naouar<sup>1</sup>, Aboulouidad Salma<sup>1</sup>, Lakouichmi Mohamed<sup>2,3</sup>, Mansouri Hattab Nadia<sup>1</sup>

<sup>1</sup>Department of Maxillofacial Surgery, Mohammed VI University Hospital Center, Marrakesh, Morocco

<sup>2</sup>Maxillofacial Surgery Department Avicenna Military Hospital, Med VI University Hospital Center, Marrakesh, Morocco

<sup>3</sup>Faculty of Medicine and Pharmacy of Marrakesh, Cadi Ayyad University, Morocco

\*Corresponding author: Dr.zakaria2011@gmail.com

Received July 05, 2018; Revised August 09, 2018; Accepted September 07, 2018

**Abstract** The neglected congenital muscular torticollis (NCMT) of the adult is rare. It is due to a fibrous retraction of the sternocleidomastoid muscle. **Observation:** Patient, aged 17, consulted for a neglected congenital muscular torticollis. The Clinical and radiological investigations showed severe craniofacial dysmorphism. **Discussion:** NCMT is a common abnormality of the child who must be treated before the age of ten. When neglected, the consequences on craniofacial growth are of order morphological, functional and psychological. We report the case of a NCMT having resulted in severe and dramatic abnormalities of the cephalic extremity.

**Keywords:** Torticollis, neglected, deformities, growth, craniofacial

**Cite This Article:** Aziz Zakaria, Ibnouelghazi Naouar, Aboulouidad Salma, Lakouichmi Mohamed, and Mansouri Hattab Nadia, "Neglected Congenital Muscular Torticollis: Dramatic Impact on Craniofacial Growth." *American Journal of Medical Case Reports*, vol. 6, no. 8 (2018): 161-162. doi: 10.12691/ajmcr-6-8-4.

## 1. Introduction

The neglected congenital muscular torticollis (NCMT) in adults is rare [1]. It is characterized by the shortening and congenital fibrous retraction of the sternocleidomastoid muscle (SCMM). Diagnosed and treated at an early age, the evolution is favorable without repercussion neither functional nor aesthetic [1]. When neglected, complications are severe on craniofacial growth [1,2]. We report the case of a neglected torticollis of the SCMM left with serious morphological and functional consequences on the craniofacial growth.

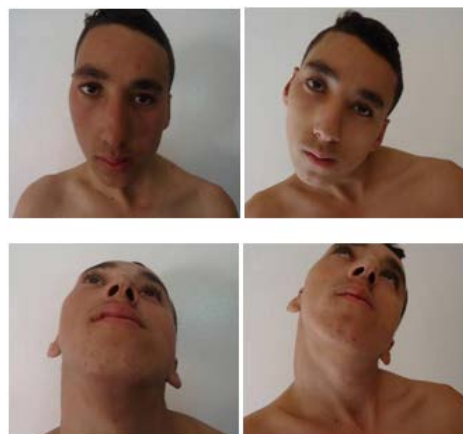


Figure 1. Clinical aspect

## 2. Observation

Patient, aged 17, consulted for a vicious attitude of the head and neck. He came with the head inclined towards the left shoulder, a contralateral translation of the face and a retractile bridle at the expense of the left sternocleidomastoid muscle. The general examination found a patient in good general condition weighing 78 kg for a height of 1.82 m. The lower bipolar tenotomy followed by multiple sessions of physiotherapy and occupational therapy advice. Six months after the symmetry of the shoulders, the cervical mobility and the straightness of the cephalic extremity were recovered but the deformation and craniofacial asymmetry persisted (Figure 1 and Figure 2).

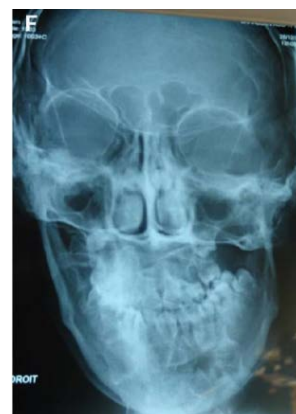

Figure 2. Radiological deformities

### 3. Discussion

Congenital muscular torticollis (CMT) is a condition that must be diagnosed and treated in children at an early age, to avoid the appearance of disorders of growth of the cephalic extremity [1,3]. These disturbances are serious and are of a morphological nature, functional and psychological [4]. The CMT is a common anomaly of the child. The incidence is between 0.3 and 2% [2].

The etiopathogenesis remains uncertain, many theories have been evoked (traumatic, intrauterine compression, hematoma ...)

Without being able to establish a satisfactory anatomic clinical correlation [3]. Of easy diagnosis, if it is well treated the craniofacial growth is normal [2,4], the NCMT leads to a true craniofacial dysmorphism, which results in plagiocephaly and facial asymmetry, the importance of which depends on the degree of retraction [5]. The shorter and longer the retraction, the more severe the morpho-functional deformities [6]. Craniofacial asymmetry is manifested by hypotrophy of the contracted hemiface, imbalance and loss of harmony of the three stages [1,5,6,7]. Dysmorphic disorders affect bone structures and tissue cover (tissue atrophy) [1]. These morphological abnormalities are accompanied by functional disorders with, above all, the obliquity of the bipupillary line and occlusal disorders (cross occlusion, endomaxillary, lateromandibulia ..) [2,7]. The psychological impact of the NCMT is non-negligible, most often with withdrawal and social isolation [3,6]. Schooling is most often disturbed or even stopped.

Most authors agree on the need for NCMT surgical treatment in adults [8,9]. Several techniques are proposed, the lower or upper uni or bipolar tenotomy under general anesthesia is the most used [8-10]. Muscle elongation and injection of botulinum toxin may be alternatives in less severe muscle dystonia with limited effect [11,12]. The results published in the literature demonstrate that two essential factors condition the functional and aesthetic prognosis of the CMT: the age at the intervention and the severity of the torticollis [1,5,9]. The earlier the age of intervention, the more craniofacial growth is symmetrical and harmonious.

The best results are obtained with a tenotomy performed before the age of five, after ten years the

asymmetry is already significant [9,10]. The recurrence rate according to the literature is between 0.8 and 20% [1,9,11].

### Conflict of Interest

The authors declare that they have no conflict of interest.

### References

- [1] Pombo castro M, Luaces Rey R, Vázquez Mahia, Lopez-Cedrun Cembranos JL. Congenital Muscular Torticollis in adult patients: literature review and a case report using a harmonic scalpel. *J Oral Maxillofac Surg* 2013; 16: 1-6.
- [2] Nilesh K, Mukherji S. Congenital muscular torticollis. *Ann Maxillofac Surg*. 2013; 3(2): 198-200.
- [3] Tatli B, Aydinli N, Caliskan M, et al: Congenital muscular torticollis: Evaluation and classification. *Pediatr Neurol* 34: 41, 2006.
- [4] Morrison DL, MacEwen GD. Congenital muscular torticollis: observations regarding clinical findings, associated conditions, and results of treatment. *J. Pediatr. Orthop.* 1982; 2: 500-505.
- [5] Seo SJ, Yim SY, Lee IJ, Han DH, Kim CS, Lim H, Park MC. Is craniofacial asymmetry progressive in untreated congenital muscular torticollis?. *Plast Reconstr Surg*. 2013; 132(2): 407-13.
- [6] Stevens P, Downey C, Boyd V, Cole P, Stal S, Edmond J, Hollier L. Deformational plagiocephaly associated with ocular torticollis: a clinical study and literature review. *J Craniofac Surg*. 2007; 18(2): 399-405.
- [7] Van Vlimmeren LA, Helders PJ, van Adrichem LN, Engelbert RH. Torticollis and plagiocephaly in infancy: therapeutic strategies. *Pediatr Rehabil*. 2006; 9(1): 40-6.
- [8] Jones CD, Nakhdejvani A, Lidder S. (2012). Surgical management of idiopathic torticollis secondary to a fibrotic band. *Orthop. Rev. (Pavia)* 4:e27.
- [9] Seyhan N, Jasharllari L, Keskin M, Savaci N. Efficacy of bipolar release in neglected congenital muscular torticollis patients. *Musculoskelet Surg*. 2012; 96(1): 55-7.
- [10] Patwardhan S, Shyam AK, Sancheti P, Arora P, Nagda T, Naik P. Adult presentation of congenital muscular torticollis: a series of 12 patients treated with a bipolar release of sternocleidomastoid and Z-lengthening. *J Bone Joint Surg Br*. 2011; 93 (6): 828-32.
- [11] Collins A, Jankovic J. Botulinum toxin injection for congenital muscular torticollis presenting in children and adults. *Neurology*. 2006; 67: 1083-1085.
- [12] Cheng JC, Tang SP, Chen TM, et al: The clinical presentation and outcome of treatment of congenital muscular torticollis in infants: A study of 1086 cases. *J Pediatr Surg* 35:1091, 2000.