

Gastric Sarcoidosis: An Atypical Presentation of a Rare Disease

Yanardag H¹, Tetikkurt C^{2,*}, Bilir M¹, Kepil N³, Verdi Y¹

¹Department of Internal Medicine Medicine, Cerrahpasa Medical Faculty, Istanbul University

²Department of Pulmonary Medicine, Cerrahpasa Medical Faculty, Istanbul University

³Department of Pathology, Cerrahpasa Medical Faculty, Istanbul University

*Corresponding author: tetikkurt@gmail.com

Abstract Sarcoidosis is a multisystemic granulomatous disease characterised by the histologic evidence of granulomas in various organs. Clinically discernible gastric sarcoidosis is extremely rare, reported in less than 1% of the patients. We present a case of gastric sarcoidosis with atypical manifestations and without current pulmonary disease. The patient was admitted for gastric fullness, anorexia, and weight loss. She had a history of migraine and nodular goiter. Family history revealed bladder carcinoma in the mother and gastric carcinoma in the uncle. Initial laboratory findings and chest x-ray were normal. Biopsies from the gastric mucosa revealed noncaseating granulomas with focal multinucleate giant cells. Six months after the patient was admitted for dry cough and fatigue. Chest x-ray and CT revealed diffuse nodules in the upper and middle lung zones. Transbronchial biopsy demonstrated noncaseating granulomas compatible with sarcoidosis. The patient was started on methylprednisolone and had a significant improvement in her symptoms. This case is an unique paradigm for the exceptional presentation of sarcoidosis. Isolated extrapulmonary organ involvement without simultaneous lung disease may be the initial manifestation of sarcoidosis. Meticulous follow-up for sarcoidosis is required for patients presenting with atypical symptoms and noncaseating granulomas in any extrapulmonary organ.

Keywords: *sarcoidosis, stomach, gastric*

Cite This Article: Yanardag H, Tetikkurt C, Bilir M, Kepil N, and Verdi Y, “Gastric Sarcoidosis: An Atypical Presentation of a Rare Disease.” *American Journal of Medical Case Reports*, vol. 5, no. 6 (2017): 135-140. doi: 10.12691/ajmcr-5-6-1.

1. Introduction

Sarcoidosis is a chronic systemic disease of unknown etiology characterized by the formation of noncaseating granulomas in various organs [1]. The clinical manifestations of sarcoidosis are highly variable and nonspecific. Although thoracic involvement occurs in more than 90% of the patients, every organ may be affected [2,3,4]. Gastrointestinal tract involvement is rare with an incidence of less than 1%. Stomach is the most common site but these cases are often clinically silent [5,6]. In literature, there are only few cases of symptomatic gastric sarcoidosis with documented histopathological evidence of noncaseating granulomas [7]. Diagnosis of isolated gastric sarcoidosis constitutes difficulties for the clinician due to its atypical clinical profile and subclinical occurrence.

We report a case of gastric sarcoidosis presenting without initial pulmonary disease. Gastric sarcoidosis is a rare form of extrapulmonary sarcoidosis and clinicians should bear in mind that isolated gastric sarcoidosis may occur without simultaneous pulmonary involvement.

2. Case Report

A 55 year old Caucasian female was admitted for gastric fullness, anorexia, and weight loss (6 kg) in the last three months. She had a history of migraine and nodular goiter. Her mother had bladder carcinoma and her uncle had died of gastric carcinoma. She was an ex-smoker for 10 years with a previous smoking history of 10 pack-years. Physical examination was remarkable for mild tenderness in the epigastric area.

Her initial laboratory results revealed WBC 5.9×10^3 /mm³, hemoglobin 14g/dl, platelets 288×10^3 /mm³, lymphocytes 1.4×10^3 /mm³, creatinine 0.88 mg/dl, AST 18 IU/L, ALT 20.6 IU/L, LDH 201 IU/L, albumine 5.1 gr/dl, CRP 0.5 mg/dl, and calcium 8.9 mg/dl. ECG showed sinus rhythm. Serum ACE was 18 IU/L. Tuberculin test was negative. Chest x-ray (Figure 1) was normal. Stool studies were negative for blood, culture, and parasites. Histopathology of the gastric mucosal biopsies taken from the white milium nodules in the corpus revealed granulomatous gastritis multiple small noncaseating granulomas composed of epithelioid cells, histiocytes, and multinucleated giant cells (Figure 2, Figure 3) while

colonoscopic examination was normal. Biopsies stained for *Helicobacter pylori*, *m.tuberculosis*, fungal organisms, and culture of the gastric aspirate were negative. Other

laboratory workup to rule out differential granulomatous etiology was not diagnostic. Treatment with proton pump inhibitors was not curative.

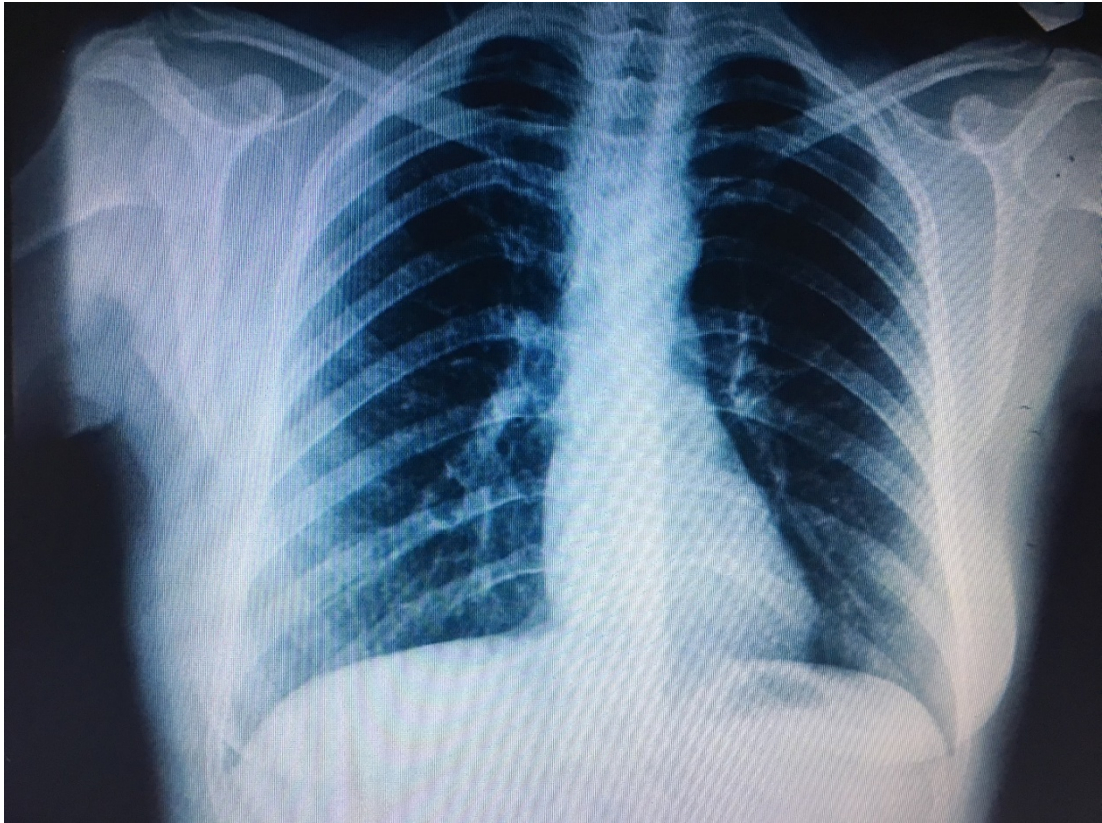


Figure 1. Initial normal chest x-ray

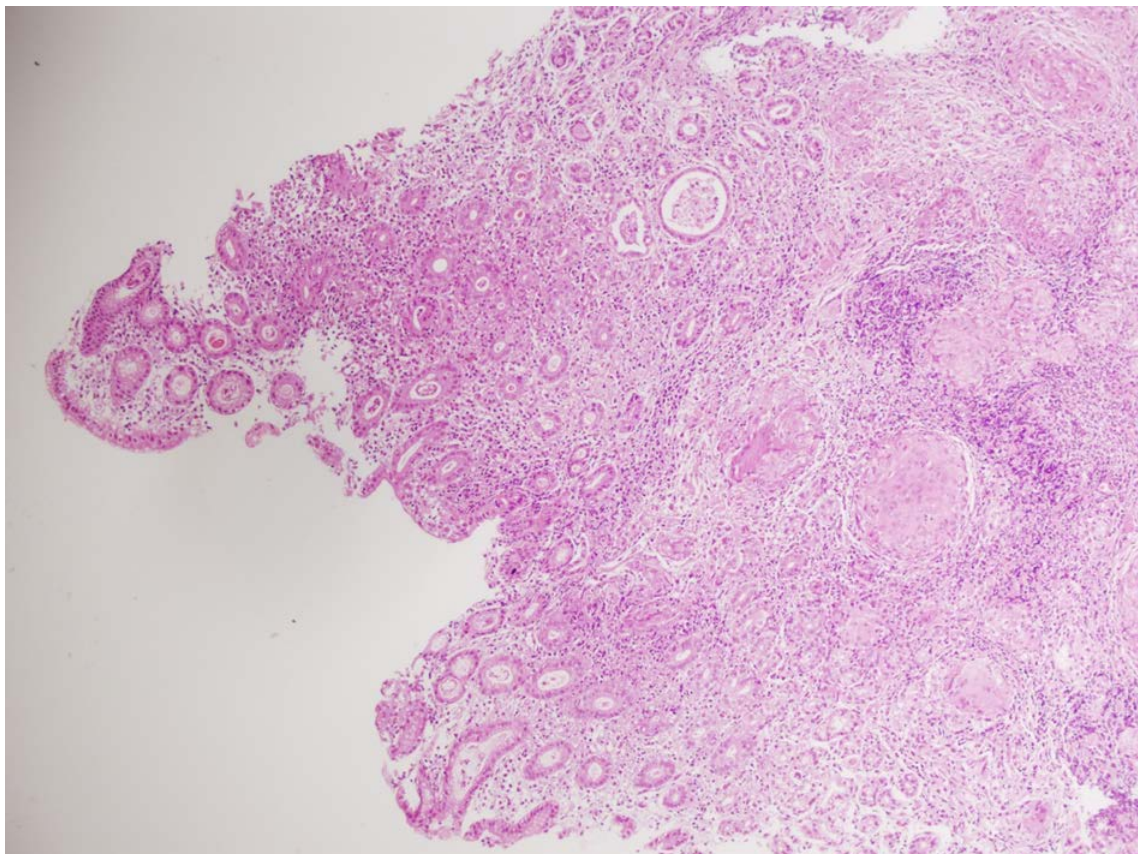


Figure 2. Histopathology of gastric mucosal biopsy showed discrete noncaseating granulomas composed of epithelioid histiocytes and multinucleated giant cells in the lamina propria (HEX100)

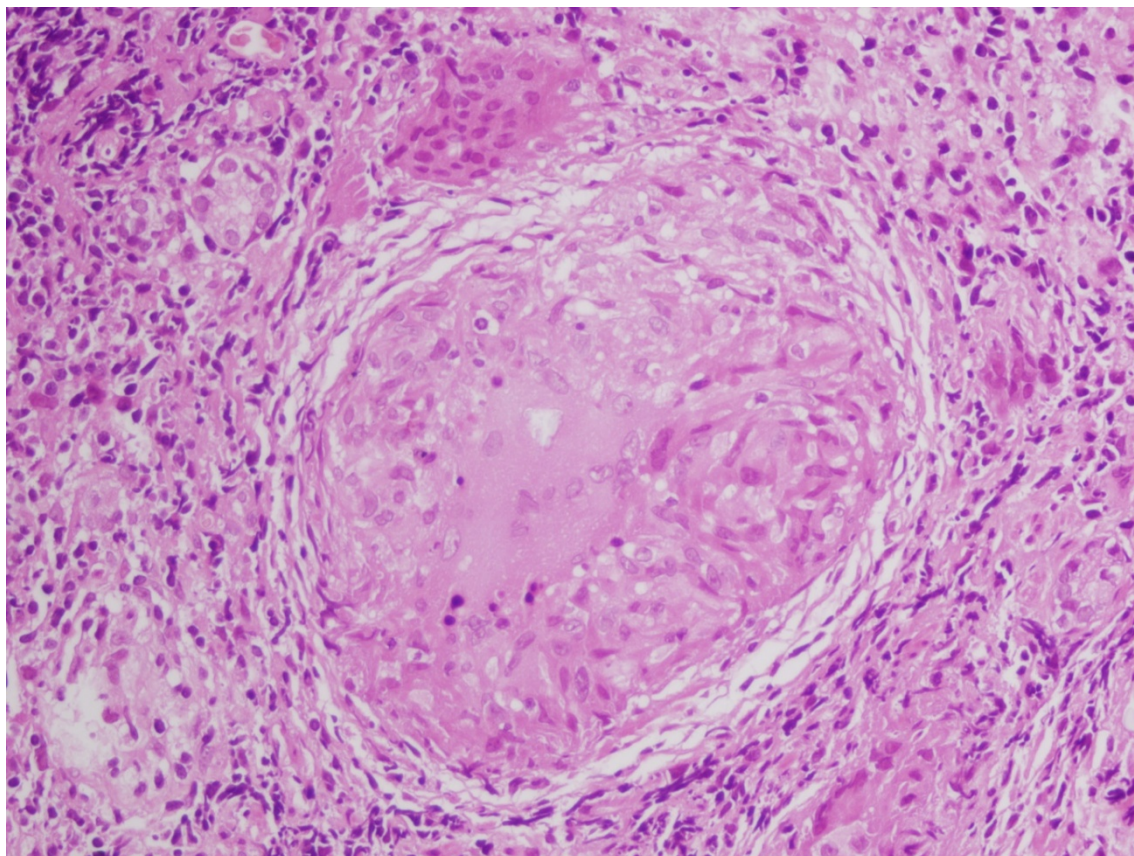


Figure 3. Histopathology of gastric mucosal biopsy showed discrete noncaseating granulomas composed of epithelioid histiocytes and multinucleated giant cells in the lamina propria (HEX400)

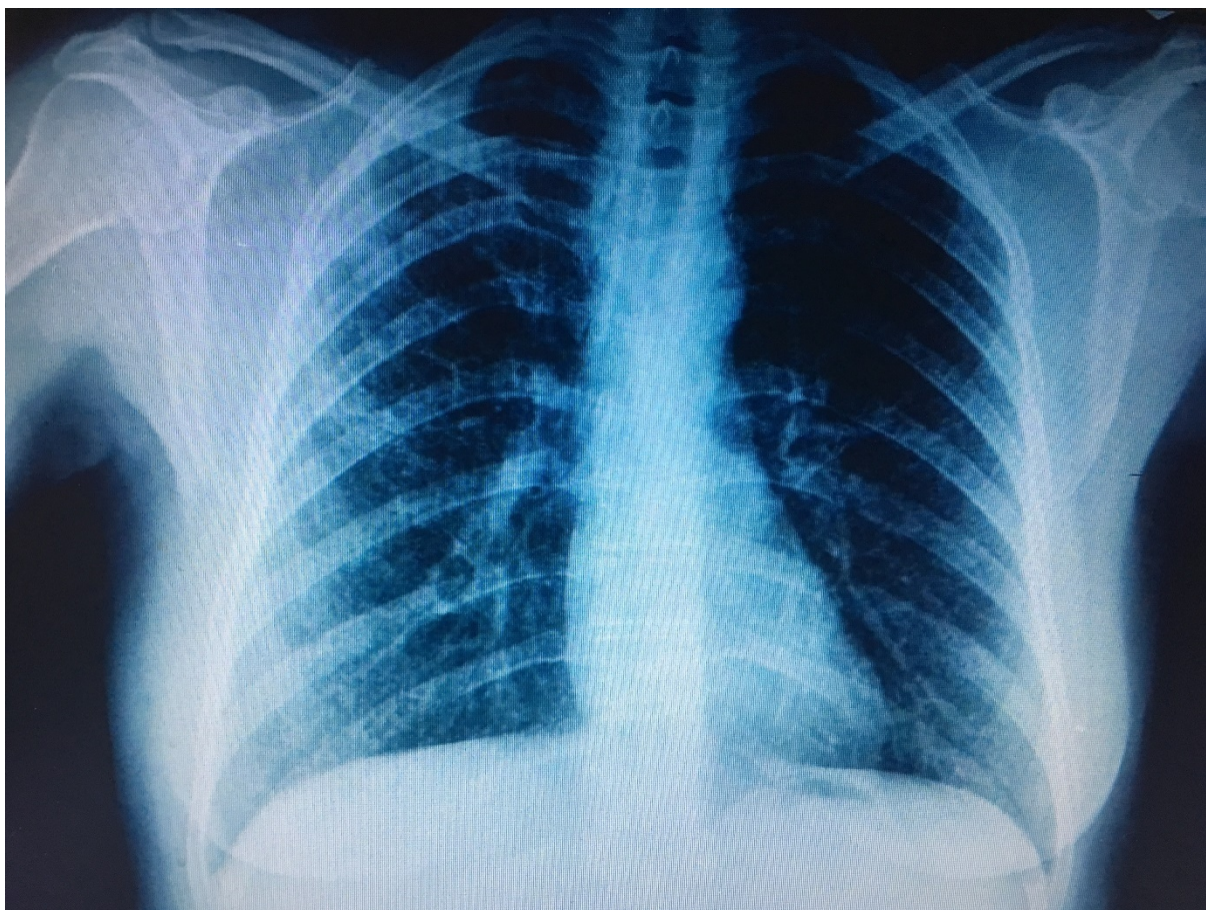


Figure 4. Chest x-ray showed bilateral micronodular opacities

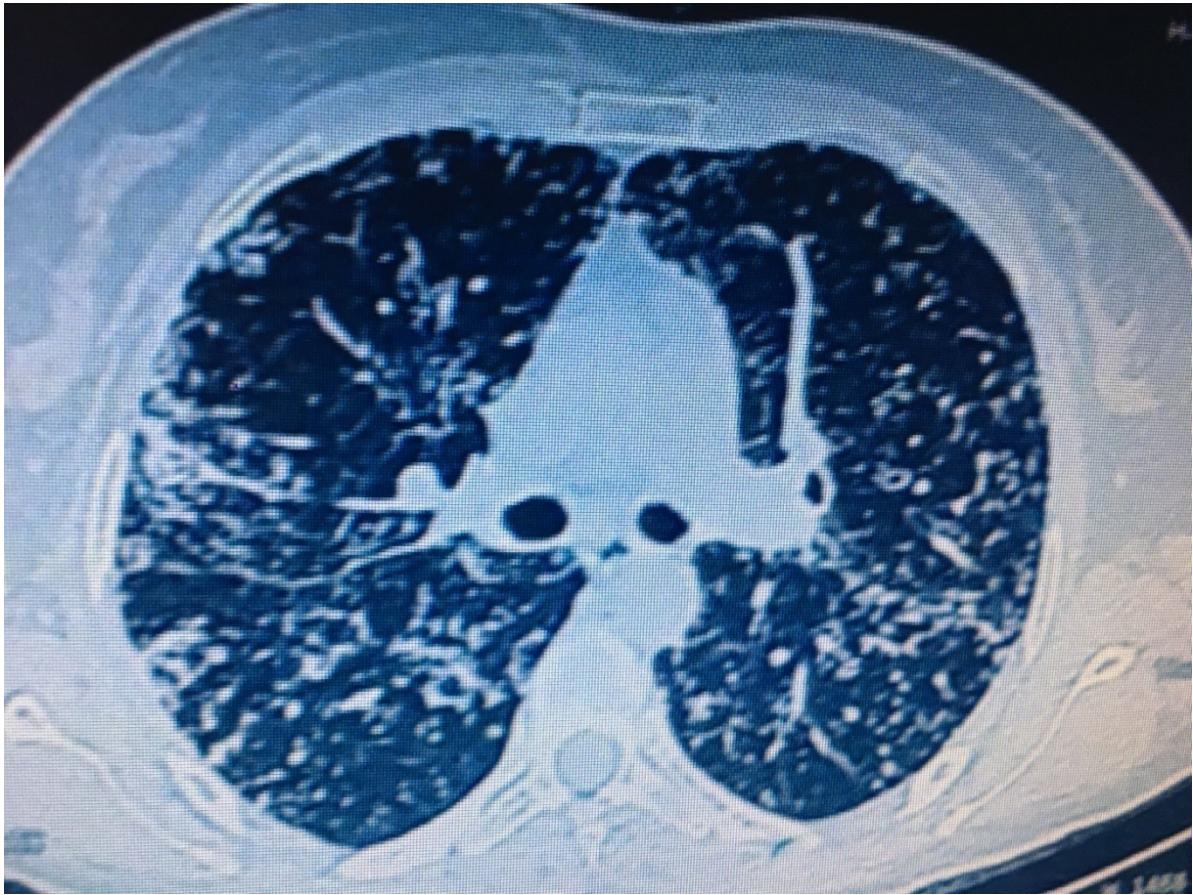


Figure 5. Computed tomography of the thorax revealed micronodular centrilobular nodules and thickened interlobular septa in both upper lobes

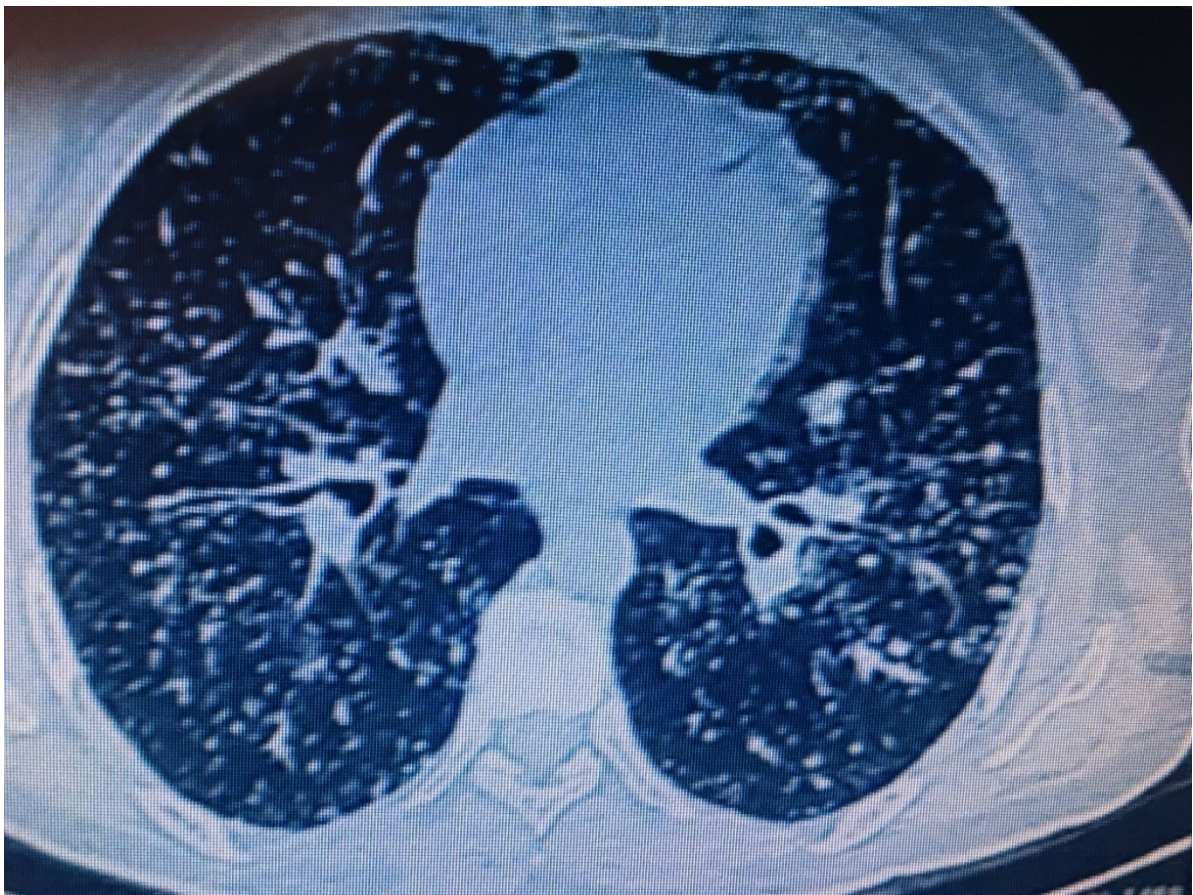


Figure 6. Computed tomography of the thorax revealed micronodular centrilobular nodules and thickened interlobular septa in both middle lobe and lingula

Six months later the patient was admitted for dry cough and fatigue. Blood count was WBC $6.2 \times 10^3 / \text{mm}^3$, hemoglobin 13.8 g/dl, platelets $284 \times 10^3 / \text{mm}^3$, and lymphocytes $1.6 \times 10^3 / \text{mm}^3$. creatinine 0.76 mg/dl, AST 20 IU/L, ALT 24 IU/L, LDH 208 IU/L, albumine 4.2 gr/dl, CRP 0.4 mg/dl, and calcium 8.6 mg/dl. Urine analysis was normal. Chest x-ray showed bilateral multiple nodules (Figure 4). Thorax CT revealed micronodular centrilobular nodules, thickened interlobular septa, and ground-glass opacities in both upper and middle zones (Figure 5, Figure 6). Serum angiotensin-converting enzyme level was 76 IU/L. Smear and culture of BAL sample was negative for bacteria, fungus and mycobacteria. Histopathologic examination of the bronchoscopic mucosal biopsy samples revealed noncaseating granulomatous inflammation with histiocytes, epithelioid, and multinucleated giant cells. A diagnosis of sarcoidosis with gastric involvement was made. A twelve month course of methylprednisolone treatment led to complete resolution of gastric and pulmonary symptoms.

3. Discussion

The disease course in sarcoidosis is highly variable. Although the lungs are the most commonly affected organ, concomitant involvement of extrapulmonary organs can be seen in up to 50% of cases [8]. On the other hand, GI tract involvement is uncommon and extremely rare. It is reported in less than 1% of the patients [1]. True incidence may be unknown due to the great number of asymptomatic patients [5]. We present a case of gastric sarcoidosis presenting with atypical symptoms and histopathologic evidence of noncaseating granulomatous inflammation of the corpus without lung involvement.

Diagnosis of sarcoidosis is based upon a compatible history, the presence of granulomas in at least two organs, negative staining or culture for acid fast bacilli, and lack of exposure to toxins or drugs. Granulomatous inflammation only in one organ is not diagnostic of sarcoidosis. Histologic confirmation may not be required in a second organ if the alternative causes of granulomatous inflammation is excluded [1,6,9,10]. Clinical presentation of gastric sarcoidosis varies depending on the intensity of granulomatous inflammation. The disease usually manifests itself as gastric ulcer or diffuse infiltration of gastric mucosa with granulomas causing luminal narrowing [5,6,11]. In our case, the patient had white miliary nodules in the corpus. The initial symptoms, presentation, clinical manifestations, and the laboratory findings were not compatible with sarcoidosis. Only the gastric mucosa biopsy revealed noncaseating granulomatous inflammation that may be associated with various granulomatous diseases including sarcoidosis. There was no lung or any other extrapulmonary organ involvement pointing out to sarcoidosis initially. The diagnosis was confirmed six months later by transbronchial biopsy when the patient presented with dry cough, fatigue, and nodules in the chest CT.

Our case presented with an unusual manifestation of sarcoidosis having an isolated and a rare organ involvement. Clinically recognizable GI involvement is

uncommon occurring in less than %1 of the patients, although the incidence of subclinical disease may be much higher [1,12,13]. On the other hand, granulomas in the gastric biopsy specimens are extremely rare and are mostly associated with Crohn's disease, tuberculosis, histoplasmosis, isolated granulomatous gastritis, vasculitis, and lymphoma [7,14,15,16]. Second the symptoms were exceptional. Third, lung disease occurred six months later than the gastric involvement. Fourth, the laboratory results were indecisive and nonspecific. The patient did not have any respiratory symptoms initially and thorax CT was not performed. It may be considered unusual for a patient with a normal chest x-ray to develop stage III disease after six months. If CT had been done at admission the lung parenchyma would be much more delineated. Consequently, the final diagnosis was conclusive.

Clinicians should bear in mind that sarcoidosis may present with an isolated and an unusual organ involvement without clinical evidence of current lung disease that may lead to a diagnostic dilemma. Follow up of such patients constitutes a crucial and critical step for final diagnosis.

References

- [1] Statement on sarcoidosis. Joint Statement of the American Thoracic Society (ATS), the European Respiratory Society (ERS) and the World Association of Sarcoidosis and Other Granulomatous Disorders (WASOG) adopted by the ATS Board of Directors and by the ERS Executive Committee, February 1999. *Am J Respir Crit Care Med.* 1999 Aug; 160(2):736-55.
- [2] Hillerdal G, Nou E, Osterman K, Schmekel B. Sarcoidosis: epidemiology and prognosis. A 15-year European study. *Am Rev Respir Dis.* 1984 Jul; 130(1):29-32.
- [3] Lynch JP 3rd, Kazerooni EA, Gay SE. Pulmonary sarcoidosis. *Clin Chest Med.* 1997 Dec; 18(4):755-85.
- [4] Reich JM. Mortality of intrathoracic sarcoidosis in referral vs population-based settings: influence of stage, ethnicity, and corticosteroid therapy. *Chest.* 2002 Jan; 121(1):32-9.
- [5] Sharma AM, Kadakia J, Sharma OP. Gastrointestinal sarcoidosis. *Seminars in Respiratory Medicine.* 1992 13(6):442-449.
- [6] Chaudhary P1, Gopaluni S, Sanyal S, Shah C. Atypical sarcoidosis masquerading as neutropenia. *Sarcoidosis Vasc Diffuse Lung Dis.* 2010 Jul; 27(2):160-163.
- [7] Afshar K, Bodyking A, OP Sharma, Shigemitsu H. Gastric sarcoidosis and review of the literature. *Journal of the National Medical Association* 2010 102(5):419-422.
- [8] Baughman RP1, Teirstein AS, Judson MA, Rossman MD, Yeager H Jr, Bresnitz EA, DePalo L, Hunninghake G, Iannuzzi MC, Johns CJ, McLennan G, Moller DR, Newman LS, Rabin DL, Rose C, Rybicki B, Weinberger SE, Terrin ML, Knatterud GL, Cherniak R; Case Control Etiologic Study of Sarcoidosis (ACCESS) research group. Clinical characteristics of patients in a case control study of sarcoidosis. *Am J Respir Crit Care Med.* 2001 Nov 15; 164 (10 Pt 1): 1885-1889.
- [9] Johns CJ1, Michele TM. The clinical management of sarcoidosis. A 50-year experience at the Johns Hopkins Hospital. *Medicine (Baltimore).* 1999 Mar; 78(2): 65-111.
- [10] Judson MA. The diagnosis of sarcoidosis. *Baughman R and Drent M, eds. Clin Chest Med.* 2008; 29(3):415-427.
- [11] Beniwal RS1, Cummings OW, Cho WK. Symptomatic gastrointestinal sarcoidosis: case report and review of the literature. *Dig Dis Sci.* 2003 Jan; 48(1):174-178.
- [12] Shkolnik LE1, Shin RD, Brabeck DM, Rothman RD. Symptomatic gastric sarcoidosis in a patient with pulmonary sarcoidosis in remission. *BMJ Case Rep* 2012 Jul 13; 2012.
- [13] Tokala H, Polsani K, Kalavakunta JK. Gastric sarcoidosis: a rare clinical presentation. *Case Rep Gastrointest Med.* 2013; 2013: 260704.
- [14] Friedman M1, Ali MA, Borum ML. Gastric sarcoidosis: a case report and review of the literature. *South Med J.* 2007 Mar; 100(3): 301-3033.

- [15] Ectors NL1, Dixon MF, Geboes KJ, Rutgeerts PJ, Desmet VJ, Vantrappen GR. Granulomatous gastritis: a morphological and diagnostic approach. *Histopathology*. 1993 Jul; 23(1):55-61.
- [16] Pramod Theetha Kariyanna, Apoorva Jayarangaiah, Robert Adrah, Jason Yi, Mujibur Majumder. Gastric Sarcoidosis: A Difficult to Diagnose Rare Disease. Gastric Sarcoidosis: A Difficult to Diagnose Rare Disease. *American Journal of Medical Case Reports* Vol. 4, No. 2, 2016, pp 58-61.