

Manuscript Title: Epidural Ropivacaine Infusion Causing Fluctuating Arrhythmia

Moustafa Elsheshtawy*, Vasudev Virparia, Falgun Patel, Ashok Khanna

Division of Cardiology, Department of Medicine, Coney Island Hospital, Brooklyn, NY 11235, U.S.A.

*Corresponding author: melsheshtawymd@gmail.com; moustafa.elsheshtawy@nychhc.org

Abstract The material has not been previously published elsewhere and is being considered solely by the American Journal of Medical Case Reports. This case report determined to be “A Healthcare Operations Activity and does not include Human Research – Institutional Review Board approval is not required” by Maimonides Institutional Review Board, an institutional ethics committee.

Keywords: Epidural infusion, Local anesthetic, Ropivacaine, sinus arrhythmia

Cite This Article: Moustafa Elsheshtawy, Vasudev Virparia, Falgun Patel, and Ashok Khanna, “Manuscript Title: Epidural Ropivacaine Infusion Causing Fluctuating Arrhythmia.” *American Journal of Medical Case Reports*, vol. 4, no. 4 (2016): 148-149. doi: 10.12691/ajmcr-4-4-10.

1. Introduction

Ropivacaine among other local anesthetics is known to depress the myocardium and decrease heart rate. Electrocardiogram changes including PR interval and QRS complex prolongation reflect ropivacaine effects on the heart. Although both bradycardia and ventricular arrhythmias have been commonly observed as signs of ropivacaine toxicity, we report a unique fluctuating sinus arrhythmia after epidural ropivacaine infusion to control a labor pain.

This is a 35 year old African American female patient G7P3033 who presented to the labor and delivery department in active labor. Pt has suffered two miscarriages and one elective abortion. She had three spontaneous vaginal deliveries and her three children were delivered at full term with no complications. Patient has a past medical history of fibroids and salivary gland cancer cured after surgical excision of salivary glands and radiation therapy eight years before presentation. She denied any cardiac history including palpitations and her

exercise tolerance was unlimited. On admission, her blood pressure was 122/82 mm hg and her heart rate ranged from 80 to 100 beats per minute (bpm). Epidural catheter was placed and tested by lidocaine and epinephrine 3ml before starting the patient on an epidural infusion of ropivacaine 0.1% at 10 ml/hour, a local anesthetic, to control her pain. Pt didn't receive, however, any ropivacaine bolus.

2. Case report

A few minutes after the epidural ropivacaine infusion was started, the patient began to complain of palpitation. Episodes of intermittent sinus tachycardia alternating with normal sinus rate were observed on the cardiac monitor. An electrocardiogram showed sinus rhythm with a heart rate that ranged from 86 bpm to 180 bpm with no significant change in the blood pressure (Figure 1). Stat cardiology service was sought for further evaluation and management of acute episodic changes in heart rate and ropivacaine was stopped immediately.

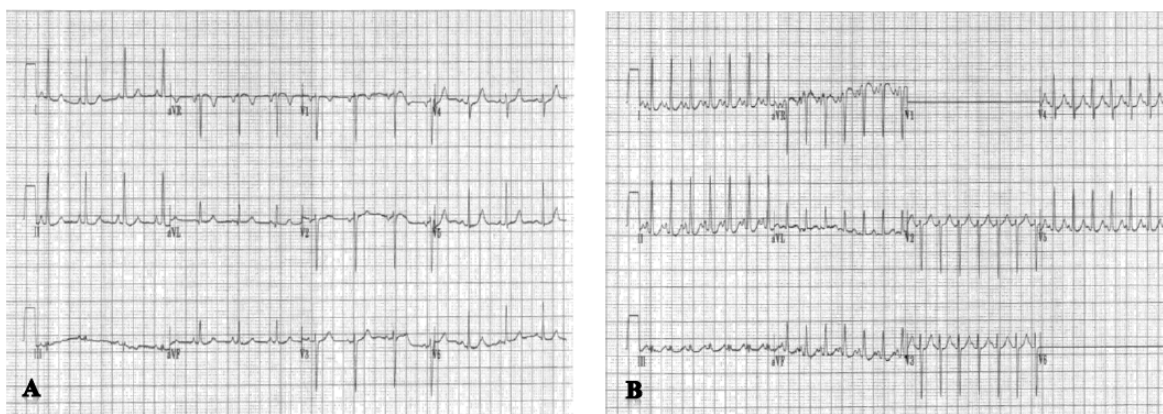


Figure 1. Electrocardiogram shows alternating sinus rate of 83 beats per minute (A) to 167 beats per minute (B)

Laboratory studies demonstrated Potassium 4.2 mmol/L (3.5-5), Sodium 140 mmol/L (136-145), glucose 98 mg/dl (65-115), and Calcium 9.4 mg/dl (8.6-10.2). Physical exam was positive for bilateral lower extremities pitting edema. A previous echocardiogram was done two years prior to this admission to investigate atypical chest pain showed normal valves, normal chambers with estimated left ventricular ejection fraction of 60 %. Two hours after stopping ropivacaine, the patient's heart rate decreased to 130 bpm and eventually returned to normal rate over the following hours.

3. Discussion

Ropivacaine hydrochloride, also known in U.S. as Naropin®, is commonly used in labor pain management through lumbar epidural infusion or intermittent bolus injections. Other uses of ropivacaine vary from surgical anesthesia to postoperative pain management. [1] The relatively low lipophilicity of ropivacaine compared to other local anesthetics correlates with its intermediate depressant effect on mitochondrial ATP-synthesis, which is involved in contractility and resuscitation of cardiomyocytes. Despite the negative chronotropic and inotropic properties of ropivacaine, it's considered the safest long-acting local anesthetic. [1,2]

Ropivacaine is a reversible sodium channel blocker that decrease sodium ion influx and consequently decrease neural depolarization and nerve conduction. [3] Ropivacaine effect on sodium ion influx is mainly responsible for depressing the maximal rate of increase in the cardiac action potential (V_{max}). The exerted effect of ropivacaine on the cardiovascular system is dose dependent and the drug toxicity is determined by the cardiac membrane potential and the rate of stimulation. [3,4] This depressant effect of ropivacaine on the sodium ion influx can lead to a re-entrant phenomenon and ventricular arrhythmia including ventricular tachycardia and ventricular fibrillation and which were also described with a similar local anesthetic, bupivacaine. [5] Sodium channels, when locked in, act in a manner of "fast-in, slow-out" that makes arrhythmia intractable to treatment. [3] Cardiovascular toxicity of Ropivacaine usually follows a two-stage process with initial stimulating phase followed by a depressive global effect at a higher drug concentration. Early

electrical changes usually manifest on electrocardiogram as PR interval and QRS complex prolongation. [6]

Although epidural test dose of epinephrine can be injected to confirm the catheter site. A documented sudden increase in the maternal heart rate of approximately 10 beats per minute within one minute after injection correlates to a positive test and a proper catheter position. [7] In our case however, we report this pattern of dysrhythmia that started with epidural ropivacaine infusion and subsided with cessation of the drugs.

4. Conclusion

Ropivacaine induced arrhythmias include bradycardia and ventricular arrhythmias, albeit rare, have been well documented in the literature. However, alternating normal sinus rhythm with sinus tachycardia was not reported previously. Clinicians should be aware of life-threatening complications of local anesthetic drugs. Prompt diagnosis and intervention can lead to absolute recovery and a favorable prognosis.

Funders

None.

The authors declare that they do not have a conflict of interest.

References

- [1] Guarav Kuthiala and Geeta Chaudhary. Ropivacaine: a review of its pharmacology and clinical use. *Indian J Anaesth* 2011;55(2):104-110.
- [2] Bernhard MG. The cardiotoxicity of local anesthetics: the place of ropivacaine. *Curr Top Med Chem* 2001;1(3):207-214.
- [3] J. H. McClure. Ropivacaine. *British Journal of Anesthesia* 1996;76:300-307.
- [4] Reiz S, Nath S. Cardiotoxicity of local anesthetic agents. *British Journal of Anesthesia* 1986;58:736-746.
- [5] Kasten GW. High serum bupivacaine concentration produce rhythm disturbances similar to torsades de pointes in anesthetized dogs. *Regional Anesthesia* 1986;11:20-25.
- [6] Reiz S, Haggmark S, Johansson G, et al. Cardiotoxicity of ropivacaine – A new amide local anesthetic agent. *Acta Anaesthesiologica Scandinavica* 1989;33:93-98.
- [7] Gaiser RR. The epidural test dose in obstetric anesthesia: it is not obsolete. *J Clin Anesth.* 2003;15(6)474-477.