

# A Case of Necrotic and Ulcerative Skin Lesions

Godefroy Chery\*, Andrea Sitlinger MD, Joanna Kipnes MD

Department of Medicine, Duke University Medical Center, Durham, NC

\*Corresponding author: gc44@dm.duke.edu

**Abstract** A 69 year old Caucasian female smoker with an unremarkable past medical history presenting with diffusing necrotic and ulcerative skin lesions of unknown etiology. After an extensive workup, the diagnosis of calciphylaxis sine calcifications was made following results from laboratory and biopsy results.

**Keywords:** *calciphylaxis sine calcifications, necrotic, ischemic*

**Cite This Article:** Godefroy Chery, Andrea Sitlinger MD, and Joanna Kipnes MD, "A Case of Necrotic and Ulcerative Skin Lesions." *American Journal of Medical Case Reports*, vol. 4, no. 3 (2016): 87-90. doi: 10.12691/ajmcr-4-3-4.

## 1. Presentation

A 69 year old Caucasian female smoker with a past medical history of hypertension, type 2 diabetes mellitus, chronic obstructive pulmonary disease, rheumatoid arthritis, heterogeneous factor V Leiden, presented with decreased perfusion of her right index finger in the setting of multiple worsening necrotic and ulcerative skin lesions on her upper and lower extremities, buttock, lower back and hip [Figure 1a].

The first of these lesions appeared nine months prior to presentation as a nickel-sized erythematous rash on the anterolateral surface of the right lower surface of the tibia. This occurred during a hospitalization at an outside hospital for sepsis with E. Coli bacteremia secondary to a urinary tract infection (UTI). Within a few days, the rashes grew larger and developed into vesicles and then flaccid bullae with leakage of serosanguinous fluid. Located predominantly on her hip, back and lower extremities, these bullae later evolved into painful eschars [Figure 1b].

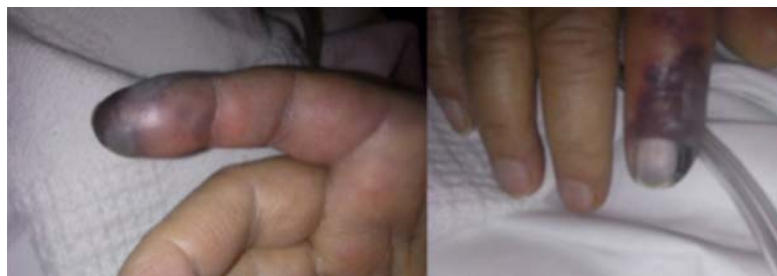

Figure 1a. Ischemia of the right index

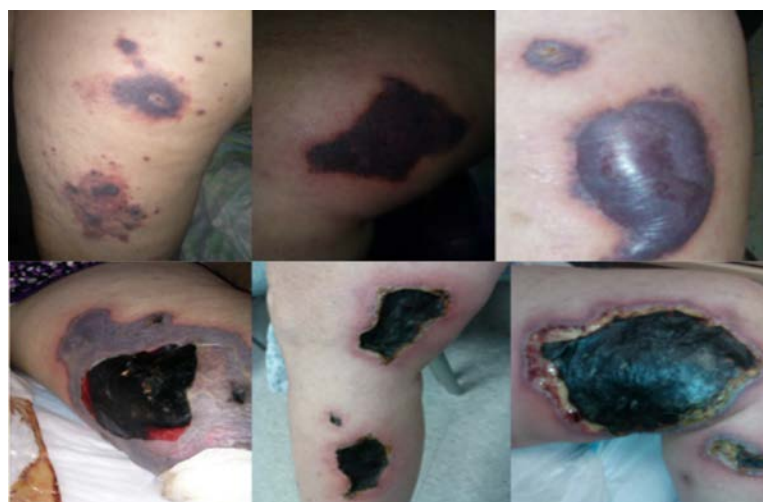
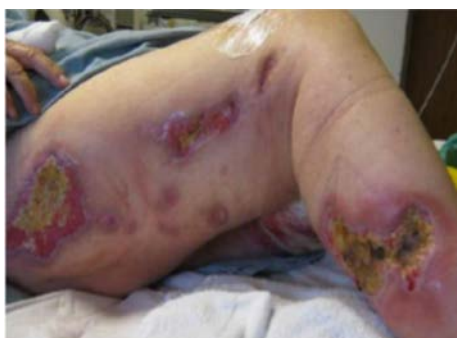
Figure 1 b-c. Erythematous rash evolved into a flaccid bullas and the painful eschars

She reported a low-grade fever with no associated systemic complaints at the onset of those lesions. Her medications then consisted only of occasional acetaminophen as needed for her knee and joint pain. The lesions improved following treatment of her UTI and sepsis.

Six months later, new skin lesions started appearing during a second hospitalization for fever, delirium and a presumed UTI. Intravenous antibiotics as well as high dose steroids were administered with minimal improvement and the patient was later discharged.

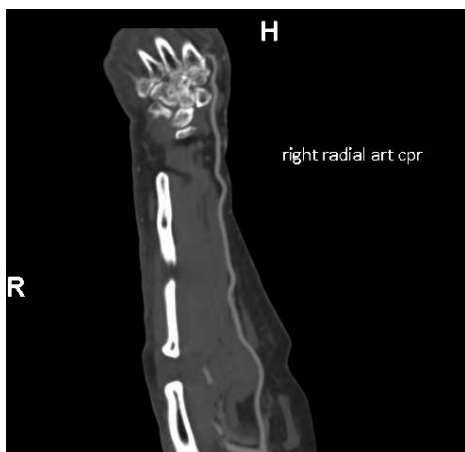
Three months following that second hospitalization, the patient was admitted to our general medicine department with decreased perfusion of her right index finger and fever in the setting of progression of her painful necro-ulcerative cutaneous lesions [Figure 1c, Figure2].



**Figure 2.** Right lateral leg wounds

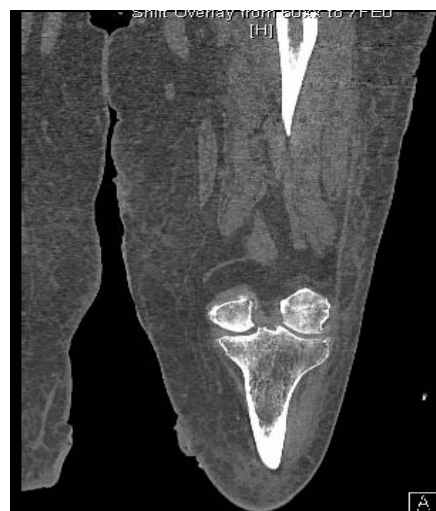## 2. Assessment

The patient had an extensive workup that included an elevated C-reactive protein (CRP) of 4.05 mg/L and erythrocyte sedimentation rate (ESR) of 74 mm/hr, a weakly positive antinuclear antibody ANA (1:60 speckled). Negative studies included: HIV, Hepatitis B, Hepatitis C, CCP, Rheumatoid factor, anticardiolipin, Russel Viper Venom, anti-myeloperoxidase (MPO), anti-proteinase 3 (PR3), cryoglobulins and anti B2 glycoprotein. In addition, serum protein electrophoresis (SPEP) and urine protein electrophoresis (UPEP) showed no monoclonal protein. Coagulation studies and a complete lipid panel (Total cholesterol 80, HDL 32, Triglyceride 99, and LDL 28) were unremarkable.



**Figure 3a.** CT upper extremity angiogram showing normal appearance of medium-sized arteries with no evidence of vasculitis

An initial biopsy of one of the lesions on the patient's left leg revealed focal vascular thrombosis resulting in chronic ischemic changes. A punch biopsy of one of the lesions on her left tibia a week later showed fibrin thrombi in superficial dermal vessels with no active neutrophilic vasculitis. Angiography of both upper and lower extremities showed multiple shallow skin ulcerations with no calcium deposition in the small superficial vessels. [Figure 3a-b].



**Figure 3b.** Angiogram showing multiple shallow skin ulcerations along the medial and lateral aspect of the thigh with no evidence of calcification

Six weeks after her initial presentation at our institution, her skin changes continued to evolve, consistent with infarction of healthy tissue at the margins of several lesions. Worsening ischemia of her right index finger necessitated amputation. Additional evaluation with transthoracic echocardiogram and CT angiography of the right hand was unremarkable. CT of the chest/abdomen/pelvis were unrevealing and a colonoscopy was negative. Mammogram was also unremarkable.

## 3. Diagnosis

The clinicopathological picture of diffuse ischemic skin necrosis associated with a histological pattern of subcutaneous thrombotic vasculopathy, in the absence of the calcium deposition, suggested a calciphylaxis-like diagnosis.

The thrombotic involvement and histologic pattern of the subcutaneous vessels resembled that seen in calciphylaxis. Extensive laboratory work-up was unrevealing, and repeated skin biopsies demonstrated vascular thrombosis limited to the small blood vessels with no calcium deposition or indication of vasculitis. This was further confirmed by angiograms of the involved extremities. In addition, her history of obesity (BMI>30), female sex, brief history of warfarin use during her hospitalization, and diabetes are known risk factors for calciphylaxis [2]. Interestingly, this pattern of thrombosis without calcifications has been observed and reported in classic cases of calciphylaxis. Zembowicz et al reported that 11 out of 15 (73%) patients with classic cases of calciphylaxis had areas showing subcutaneous thrombotic vasculopathy without calcifications [1]. Moreover, her

antibody profile including lupus anticoagulant and anticardiolipin antibodies was unremarkable, and she had no known risk factor for other subcutaneous thrombotic vasculopathy diseases such as septic or cholesterol emboli and cutaneous vasculitis. She did not have end-stage renal disease as would be expected in the majority of patients with calciphylaxis related to chronic renal failure [3,4]. Such a complex clinical/pathological picture indicated that our patient may have suffered from a rare variant of calciphylaxis called calciphylaxis *sine* calcifications, although a rare thrombotic vasculopathy syndrome could not be ruled out definitively.

Other important diagnostic considerations included Buerger's disease due to her extensive smoking (80 pack-years at the time of admission) in the setting of distal extremity ischemia and diffuse skin necrotic lesions, and possibly warfarin skin necrosis, although her symptoms were already present prior to starting warfarin. Other thrombotic vasculopathies such as septic or cholesterol emboli, and cutaneous vasculitis were excluded following the laboratory and biopsy findings.

#### 4. Management

The patient was started on 25mg sodium thiosulfate IV three times per week and twice daily hyperbaric oxygen sessions for empiric treatment for calciphylaxis *sine* calcifications. She also received daily care of her wounds and appropriate pain management with significant improvement in wound appearance. She continued to improve with multiple courses of antibiotics and abstinence from nicotine products. She was later discharged to a local long-term acute care hospital for continued wound care and she remained there for 3 weeks. She later returned to her hometown, a great distance from our health system. Available records showed that she was alive 1 year after the diagnosis. Recent attempts to contact her, 2 years following her diagnosis were unsuccessful and she remains lost to follow-up.

#### 5. Discussion

Calciphylaxis is a rare small vessel disorder resulting from a multitude of predisposing events and involves medial calcification of small vessels and capillaries of subcutaneous tissues [5]. The diagnosis is often aided by the presence of calcification on biopsy in the setting of a suggestive clinical context when all other causes have been ruled out. Although the underlying pathophysiological mechanism of calciphylaxis in patients with renal failure are still emerging, little is known of this disease in patients without renal failure. This is particularly true for calciphylaxis *sine* calcifications, a rare variant of calciphylaxis whereby the clinicopathological is suggestive but calcification is not present on biopsy. This diagnosis was first suggested by Zembowicz et al who noticed that 73% subjects with classic cases of calciphylaxis had no calcification on biopsy. Not surprisingly, this has generated a lot of discussion as more anecdotal reports are emerging in patients with conditions reminiscent of calciphylaxis *sine* calcifications, and of patients who developed calciphylaxis in the absence of mineral abnormalities or renal failure [7].

When suspected, the diagnosis of calciphylaxis *sine* calcifications is made clinically for there is no definitive histologic criteria or diagnostic laboratory test for making the diagnosis. In fact, this diagnosis should be considered after a detailed and thorough work-up and exhausting all options. More work is needed to elucidate the underlying factors contributing to the etiology of this rare variant of calciphylaxis.

The clinical scenario herein is the same as would be expected with classic cases of calciphylaxis. This patient's presenting symptoms of painful systematic, nonhealing ulcers and ischemic necrotic plaques leading to black and/or violaceous eschar-like lesions in the absence of calcification on biopsy, strongly suggests a diagnosis of calciphylaxis *sine* calcifications. The process and chronicity of her clinical manifestations essentially mirror that seen in calciphylaxis.

Other diagnostic considerations included Buerger's disease due her extensive of smoking, warfarin skin necrosis, cutaneous anthrax, septic or cholesterol emboli and cutaneous vasculitis. However, those aforementioned diagnostic considerations couldn't explain all the bizarre and systematic cutaneous manifestations experienced by our patient. In addition, repeated biopsies revealed no vasculitis. Complete laboratory and diagnostic work-ups for malignancies and other diseases were also unremarkable (see diagnosis section). The diagnosis of calciphylaxis *sine* calcifications was made after exhausting all diagnostic possibilities.

Calciphylaxis was first coined by Hans Selye in 1962 to describe a phenomenon observed in rats with induced high levels of calcium and phosphate leading to local calcifications [6]. This phenomenon was later observed in patients with certain abnormalities including hyperparathyroidism, hypervitaminosis D and renal failure leading to precipitous skin necrosis associated with vascular calcifications [5]. Intriguingly, reports of classic cases of calciphylaxis with no calcification on biopsy, as observed in our patients, have emerged recently [1], lending increasing appreciation for the clinicopathological syndrome of calciphylaxis *sine* calcifications.

Unfortunately, there is no definitive treatment for calciphylaxis or its rare variant calciphylaxis *sine* calcifications. This is particularly true in patients without end-stage renal disease and no documented laboratory abnormality. Unfortunately, the treatment is often symptomatic with many patients reported having a poor response to therapy. Thus, following an extensive review of the medical literature, we took a multifaceted approach to her treatment plan that included IV sodium thiosulfate and hyperbaric oxygen sessions to help with tissue injury and wound healing respectively, aggressive wound care and smoking cessation. Following this targeted plan, she improved and was discharged.

To our knowledge, this is the second reported case of calciphylaxis *sine* calcifications where the patient improved significantly after starting therapy (see management). Given the high morbidity and mortality risk often associated with calciphylaxis and subsequently, calciphylaxis *sine* calcifications, early diagnosis and treatment are critical to improving survival. Early recognition may prove beneficial, as those with advanced disease tend to carry a worse prognosis. Herein, our case

report details the clinical characteristics of a calciphylaxis *sine* calcifications case and a targeted treatment plan.

## Conflict of Interest/Acknowledgements

This work is not funded by any party and the author has no relevant disclosure to report herein. Any opinions, findings, and conclusions or recommendations expressed in this material are those of the authors only.

## References

- [1] Zembowicz, Artur, et al. "Subcutaneous thrombotic vasculopathy syndrome: an ominous condition reminiscent of calciphylaxis: calciphylaxis *sine* calcifications?." *The American Journal of Dermatopathology* 33.8 (2011): 796-802.
- [2] Roe, S. Michael, et al. "Calciphylaxis: early recognition and management." *The American Surgeon* 60.2 (1994): 81-86.
- [3] Janigan, David T., et al. "Calcified subcutaneous arterioles with infarcts of the subcutis and skin ("calciphylaxis") in chronic renal failure." *American journal of kidney diseases* 35.4 (2000): 588-597.
- [4] Floege, Jürgen, et al. "The effect of cinacalcet on calcific uremic arteriopathy events in patients receiving hemodialysis: the EVOLVE trial." *Clinical Journal of the American Society of Nephrology* 10.5 (2015): 800-807.
- [5] Weenig, Roger H., et al. "Calciphylaxis: natural history, risk factor analysis, and outcome." *Journal of the American Academy of Dermatology* 56.4 (2007): 569-579.
- [6] Selye, Hans. *Calciphylaxis*. University of Chicago Press, 1962.
- [7] Dominguez, Arturo. "Calciphylaxis: controversies in pathogenesis, diagnosis and treatment." (2015).