

Central Mucoepidermoid Carcinoma of Mandible: A Case Report

Nafise Shamloo^{1,*}, Nasim taghavi¹, Majid nemati², Yaser safi³

¹Oral & Maxillofacial Pathology Department, Shahid Beheshti University of Medical Sciences, Tehran, Iran

²Oral & Maxillofacial Surgery Department, Shahid Beheshti University of Medical Sciences, Tehran, Iran

³Oral & Maxillofacial Radiology Department, Shahid Beheshti University of Medical Sciences, Tehran, Iran

*Corresponding author: n_shamloo@yahoo.com

Received May 11, 2015; Revised May 25, 2015; Accepted June 29, 2015

Abstract Central mucoepidermoid carcinoma (CMC) is an uncommon tumor, comprising 2-3 % of all mucoepidermoid carcinomas reported. The majority of cases occurring in the 4th and 5th decades of life and they are histologically low-grade malignant neoplasm usually affecting the mandible. The case presented is a 41 year old woman with central mucoepidermoid carcinoma at the left posterior of the mandible as a swelling with purulent discharge since last year. Radiographic examination showed a radiolucent lesion with well-defined borders in distal area of r8.

Keywords: mucoepidermoid carcinoma, central, intraosseous, salivary gland neoplasm

Cite This Article: Nafise Shamloo, Nasim taghavi, Majid nemati, and Yaser safi, "Central Mucoepidermoid Carcinoma of Mandible: A Case Report." *American Journal of Medical Case Reports*, vol. 3, no. 8 (2015): 235-238. doi: 10.12691/ajmcr-3-8-4.

1. Introduction

Central mucoepidermoid carcinoma (CMC) is an uncommon tumor, consisting 2-3 % of all mucoepidermoid carcinomas reported. Lepp first reported an intraosseous mucoepidermoid carcinoma (MEC) of the mandible in 1931 [1]. In 1991 the World Health Organization (WHO) suggested that the term "mucoepidermoid tumor" should be changed to mucoepidermoid carcinoma. A systemic review of its histology and degree of differentiation was also done in 1991 [2,3]. The origin of the CMC is controversial and several possibilities have been considered, including: metaplasia of odontogenic cyst epithelium, entrapment of salivary tissue during embryonic development, maxillary sinus epithelium, iatrogenic entrapment of minor salivary glands and odontogenic remnants of the dental lamina [4,5].

CMC has been reported in all ages ranging from 1 to 78 years, with the overwhelming majority occurring in 4th and 5th decades of life. They are histologically low-gradetumors, usually affecting the mandible as an unilocular or multilocular radiographic lesion [4,6].

Here, we report a new case of central mucoepidermoid carcinoma within the mandible in a 41- year female.

2. Case Report

A 41-year-old woman was referred to a private oral surgery office for the diagnosis of mandibular lesion. Chief complaint was swelling and purulent discharge at the

posterior of left mandible since last year. The patient had received antibiotic during last year with diagnosis of infectious process. After antibiotic therapy, the size of the lesion has been decreased.

Her medical history was not significant. She denied smoking and any consumption of drugs or alcohol. Intra-oral examination revealed a lobular, blue purple mass with relatively firm consistency and tenderness, associated with lower lip paresthesia. Extra-oral examination showed no abnormality and face was bilaterally symmetrical. Cervical lymphadenopathy was absent.

Cone Beam Computed Tomography was taken by SCANORA 3D CBCT machine (SOREDEX, Helsinki, Finland) with 7.5x10 cm field of view, 200 microns voxel size, 90 KVP and 8 mA. On axial, cross sectional, panorama and 3D CBCT examination a radiolucent intra osseous lesion with well-defined but noncorticated borders could be detected in distal area of left third mandibular molar. Lesion caused a massive bone destruction in lingual plate of alveolar bone (Figure 1). Thinning of mandibular canal roof was seen in cross sectional views (Figure 1). The lesion did not affect adjacent teeth. A provisional diagnosis of ameloblastoma and keratocystic odontogenic tumor was made. An incisional biopsy was done. The specimen was submitted to oral and maxillofacial pathology service and prepared for histologic examination with hematoxylin and eosin staining. Gross examination revealed one piece of irregular cystic creamy brown elastic tissue, measuring 2x 1.3 x 0.5 cm. Microscopically, sections showed a malignant salivary gland tumor composed of sheets, islands and cystic spaces lined by mucous and epidermoid cells with focally papillary projections in to the cystic

spaces. Area of necrosis, hemorrhage and chronic inflammatory cells inflammation were evident. These findings suggested a diagnosis of intermediate grade of

MEC. Then the patient underwent surgery and the lesion completely excised with wide surgical margins

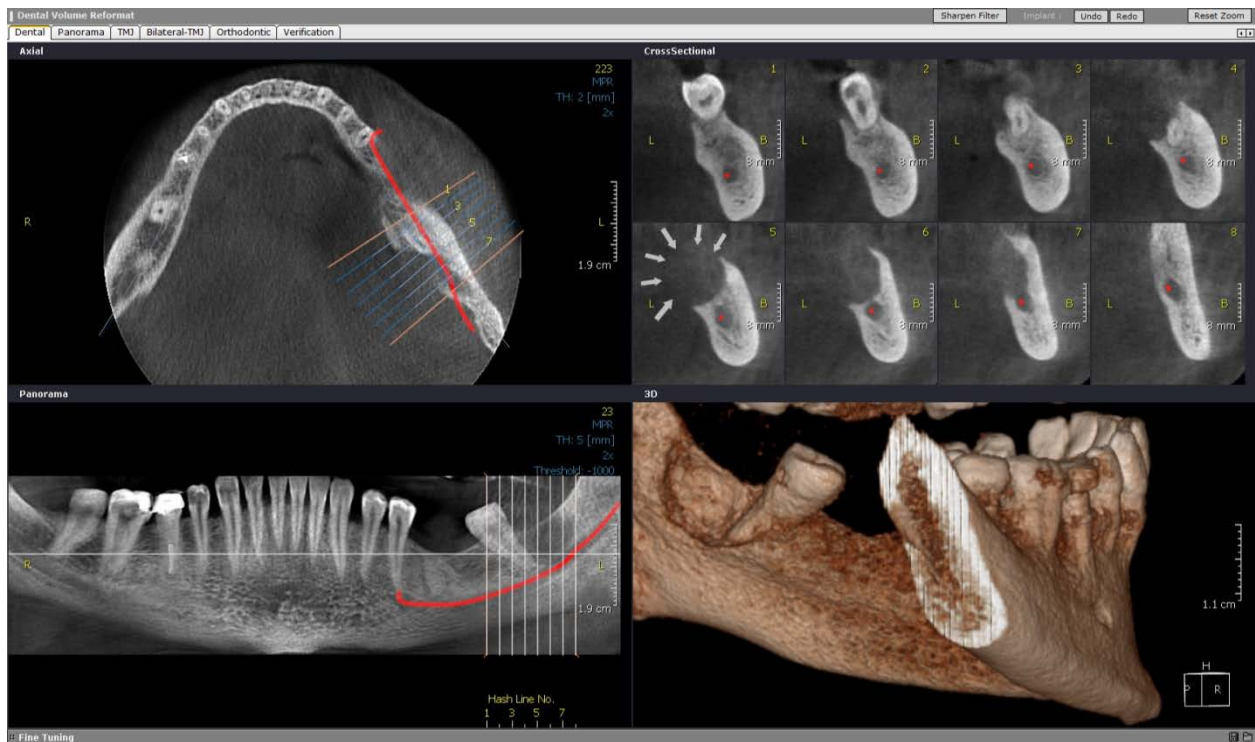


Figure 1. Axial, Cross sectional, Panorama and 3D CBCT images represent a well defined radiolucent lesion (white arrows) with perforation (white arrowheads) in the posterior area of left mandible

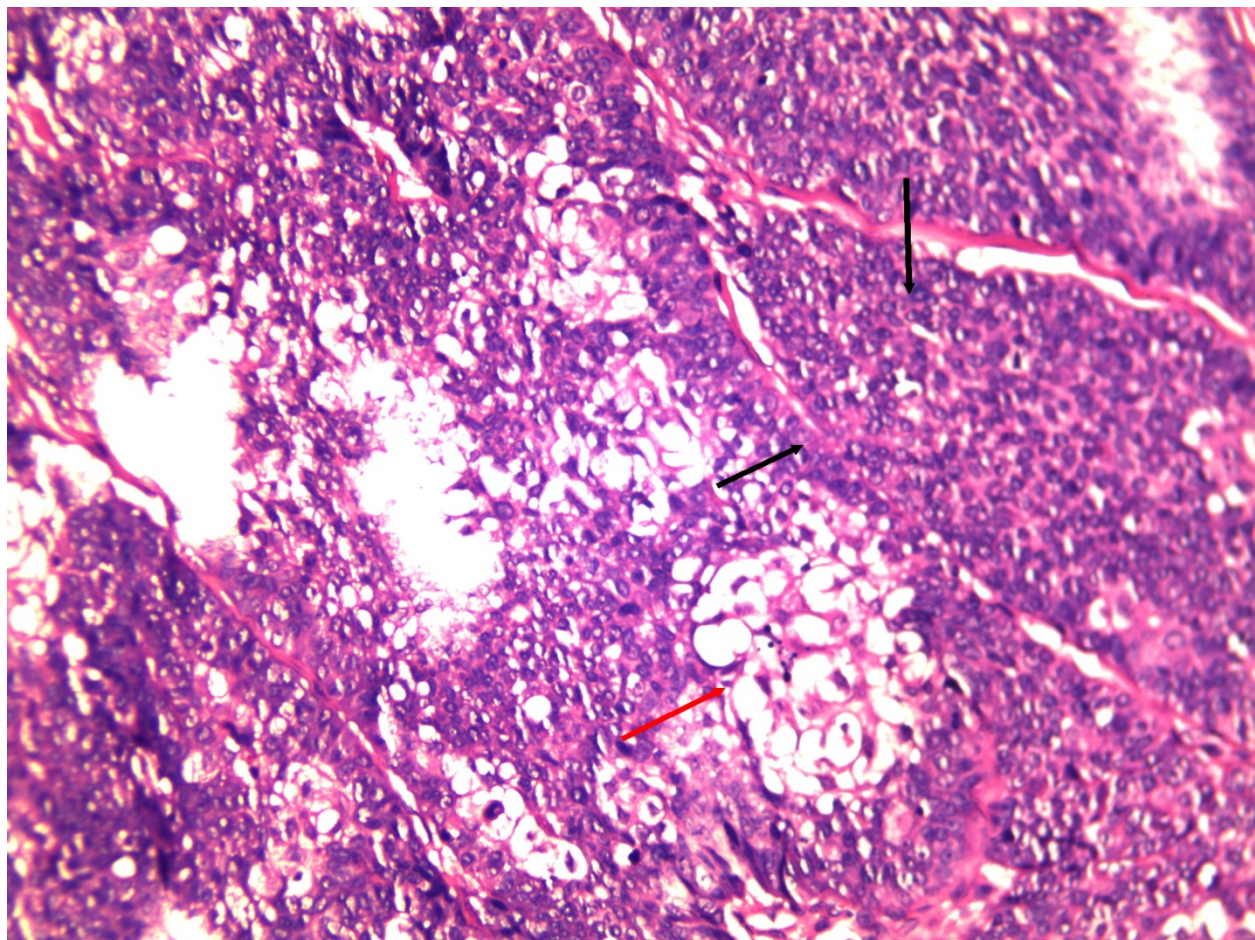


Figure 2. represents sheets of epidermoid cells (Black arrow) and mucous cells (Red arrow) X200

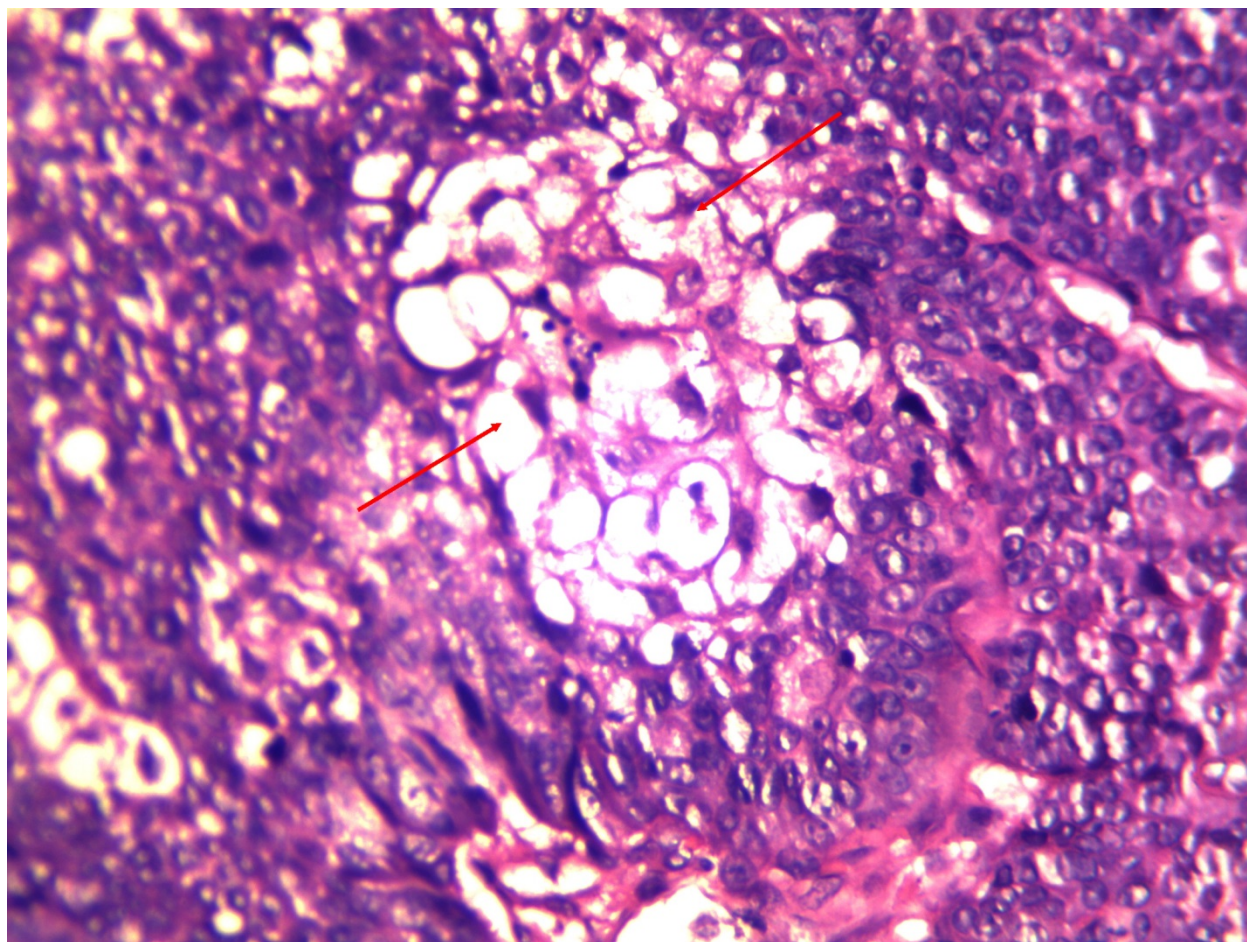


Figure 3. represents an island of mucous cells with clear cytoplasm (Red arrows) surrounded by epidermoid cells x400

3. Discussion

On rare occasion, salivary gland tumors arise centrally within the jaws. CMC is the best recognized intraosseous salivary gland tumor [7] which is predominantly seen in the mandible and affects females twice more than males [8,9], similar to present case.

Eversole et al. found that approximately 50 % of the cases were associated with dental cyst and or impacted teeth [10]. The possibility of the origin of the CMC in our case may be embryonic remnants of the submandibular salivary gland within the mandibular bone which subsequently underwent neoplastic transformation [4].

The main symptoms are swelling, pain, trismus and parasthesia. Tooth mobility occasionally has been noted. Variability of radiographic features of CMC and its resemblance to other odontogenic cysts and tumors, emphasize that CMC should be considered in the differential diagnosis of radiolucent lesions of jaws. Radiographic feature of tumors usually show a well circumscribed uni/multilocular radiolucency [9]. In this case, CBCT images showed a well-defined but noncorticated borders radiolucency.

Criteria for diagnosis of CMC have been discussed by Alexander, Silvergade and Schultz and are as below [11]:

- a) Presence of radiological evidence of bone destruction
- b) Presence of an intact cortical plate
- c) Absence of primary lesion in the salivary gland
- d) Exclusion of a metastasis or an odontogenic tumor
- e) Histologic confirmation

In this case, buccal cortical plate was intact and histologically was confirmed as intermediate MEC. Moreover, we excluded other possibilities such as metastases and odontogenic lesions.

Brookstone et al. in 1992, proposed a staging system based on the condition of the overlying bone. Lesions with intact cortical plates with no evidence of bony expansion offer the best prognosis and indicate stage I. Stage II is surrounded by intact cortical bone that has undergone some degree of expansion. Any instance of cortical perforation, breakdown of the overlying periosteum or nodal spread is best categorized clinically as stage III [12]. The presented case showed lingual cortical perforation which could be imputed as stage III disease. Metastasis has been reported in 9 % of intraosseous mucoepidermoid carcinoma primarily to the regional lymph nodes and infrequently to the ipsilateral clavicle, lung and brain [10,12,13].

Biopsy is necessary for the final diagnosis and treatment plan in all cases of CMCs. In contrast to our case, most of the reported cases are histologically low-grade and usually carry a favorable prognosis [9,10]. As a rule, even being low-grade tumors, CMC should be treated by wide local resection or en bloc resection. CMC must be followed-up for long periods due to the possibility of late local recurrence or regional metastasis [14]. According to different reports the recurrence rate of CMC varies from 13-50 % which depends on the biologic behavior of tumor and surgical methods [9,10].

In conclusion, CMC of the mandible is extremely rare malignant salivary gland neoplasm and the prognosis is

related to histologic grade ,clinical stage and adequate resection of the tumor. Long-term follow-up is mandatory for the success of thee treatment ..

References

- [1] Lin YJ, Chen CH, Wang WC, Chen YK, Lin LM. Primary intraosseous carcinoma of the mandible. *Dentomaxillofac Radiol* 2005; 34: 112-6.
- [2] Kanmani R, Daniel MJ. Intraosseous mucoepidermoid carcinoma of the maxilla: A silent invader. *Indian J Oral Sci* 2014; 5: 39-43.
- [3] Seifert G, Sobin LH, Thackray AC. Histological typing of salivary glands tumors. World health organization international histological classification of tumors. Springer - Verlag, Heidelberg 1991; 2nd edition.
- [4] Tucci R, Matizonkas-Antonio LF, de Carvalhosa AA, Castro PH, Nunes FD, Pinto DD Jr. Central mucoepidermoid carcinoma: report of a case with 11 years' evolution and peculiar macroscopical and clinical characteristics. *Med Oral Patol Oral Cir Bucal* 2009; 14: E283-E286.
- [5] Bouquot JE, Gnepp DR, Dardick I, Hietanen JH. Intraosseous salivary tissue: jawbone examples of choristomas, hamartomas, embryonic rests, and inflammatory entrapment: another histogenetic source for intraosseous adenocarcinoma. *Oral Surg Oral Med Oral Pathol Oral Radiol Endod* 2000; 90: 205-17.
- [6] Simon D, Somanathan T, Ramdas K, Pandey M. Central mucoepidermoid carcinoma of mandible - A case report and review of the literature. *World J Surg Oncol* 2003; 1: 1.
- [7] Suresh D, Raviraj J, Vijaykumar B, Suman SV, Suneel KV, Amrutha K. Central mucoepidermoid carcinoma of the maxilla with unusual ground glass appearance and calcifications: A case report. *Imaging Sci Dent* 2014 ; 44(2): 161-164.
- [8] Pires FR, Paes de Almeida O, Lopes MA, Elias da Cruz Perez D, Kowalski LP. Central Mucoepidermoid carcinoma of the mandible: report of four cases with long term follow up. *Int Oral Maxillofac Surg* 2003; 32: 378-382.
- [9] Munde A, Karle R, Metgud R, Rudgi B M. Central mucoepidermoid carcinoma of the mandible. *Indian J Dent Res* 2010; 21: 609-610.
- [10] Eversole LR, Sabes WR, Rovin S. Aggressive growth and neoplastic potential of odontogenic cysts. *Cancer* 1975; 35: 270-282.
- [11] Alexander RW, Dupuis RH, Holton H. Central mucoepidermoid tumor (carcinoma) of the mandible. *J Oral Surg* 1974; 32(7): 541-557.
- [12] Brookstone MS, Huvos AG. Central salivary gland tumors of the maxilla and mandible: a clinicopathologic study of 11 cases with an analysis of the literature. *J Oral Maxillofac Surg* 1992; 50: 229-236.
- [13] Lebsack JP, Marrogi AJ, Martin SA .Central mucoepidermoid carcinoma of the jaw with distant metastasis: a case report and review of the literature. *J Oral Maxillofac Surg* 1990; 48: 518-522.
- [14] Martinez Madrigal F, Pineda-Daboin K, Casiraghi O, Luna MA. Salivary gland tumors of the mandible. *Ann Diag Pathol* 2000; 4: 347-353.