

# Vascular Leiomyoma of the Nasal Cavity: An Unusual Tumor

Faten Hammedi<sup>1,\*</sup>, Manel Njima<sup>1</sup>, Nouha Ben Abdeljelil<sup>1</sup>, Nawrez Kolsi<sup>2</sup>, Rim Hadhri<sup>1</sup>, Ahmed Zrig<sup>1</sup>, Leila Njim<sup>1</sup>, Adnène Moussa<sup>1</sup>, Abdelfateh Zakhama<sup>1</sup>

<sup>1</sup>Department of Pathology, Fattouma Bourguiba Hospital, Monastir, Tunisia

<sup>2</sup>Department of Otorhinolaryngology, Fattouma Bourguiba Hospital, Monastir, Tunisia

\*Corresponding author: [faten\\_hammedi@yahoo.fr](mailto:faten_hammedi@yahoo.fr)

Received December 08, 2014; Revised December 26, 2014; Accepted January 05, 2015

**Abstract Background:** Angioleiomyoma of the nasal cavity is an extremely rare benign tumor. Since the first case reported by Poch-Viñals R. et al. in 1967, only 23 cases of angioleiomyoma of the nasal cavity have been published in English literature. **Methodology/principal findings:** We report a 42-year-old woman who presented with nasal obstruction and small volume epistaxis episodes. In the physical exam and under nasal endoscopy, we founded a red lesion that measured 1.5 cm. Clinically and in imagery the tumor resembled an inverted papilloma. Pathological study revealed an angioleiomyoma of the nasal cavity. **Conclusion:** Angioleiomyoma was an unusual tumor of the nasal cavity. It is more common in females. Treatment for these tumors is based on local resection, and there are no reports of recurrence after total excision.

**Keywords:** Angioleiomyoma, nasal cavity, sex hormones

**Cite This Article:** Faten Hammedi, Manel Njima, Nouha Ben Abdeljelil, Nawrez Kolsi, Rim Hadhri, Ahmed Zrig, Leila Njim, Adnène Moussa, and Abdelfateh Zakhama, "Vascular Leiomyoma of the Nasal Cavity: An Unusual Tumor." *American Journal of Medical Case Reports*, vol. 3, no. 1 (2015): 10-12. doi: 10.12691/ajmcr-3-1-4.

## 1. Introduction

Leiomyoma is a benign neoplasm composed of smooth muscle cells with a variable amount of fibrous stroma. It is the most common uterine mesenchymal tumor in adults (95%). Nasal cavity is an uncommon localization. They make up less than 1% of all leiomyomas in the human body. Leiomyoma has many variants. They are classified in three groups: leiomyoma, angioleiomyoma and epithelioid leiomyoma [1]. Angioleiomyoma or Vascular leiomyoma accounts for approximately 4% of benign soft tissue tumors. Most angioleiomyomas occur in the extremities, especially the lower extremity, and other sites include the head and the trunk [2]. The tumors are usually located in the subcutis and less often in the deep dermis. Angioleiomyoma of the nasal cavity is extremely rare. The first description of angioleiomyoma in the nasal cavity was given by Poch-Viñals R. et al. in 1967 [3,4]. Only 23 cases have been reported in the nasal cavity. The aims of this paper are to report a new case of an unusual nasal presentation of angioleiomyoma, to discuss its differential diagnosis and to describe its follow-up.

## 2. Case Report

We report a 42-year-old woman who presented, to the Otolaryngology Department of Fattouma Bourguiba Hospital of Monastir, with nasal obstruction and small volume epistaxis episodes. The patient's medical and

family histories were unremarkable. Physical exam and nasal endoscopy, founded a red lesion that measured 1,5 cm. This lesion was covered by a normal mucosa and partially obstructed the nasal cavity. CT scan showed a round hyperechoic and hypervascular nodular lesion in nasal septum, which reacted intensely to contrast injection (Figure 1). The diagnostic of inverted papilloma was suggested. The patient underwent a large excision of the mass. Grossly, the excised specimen measured 1,5 x 1 cm and was encapsulated. It was covered by a normal mucosa. On cut surface, it was yellow-colored. Histopathology demonstrated a proliferation of mature and well differentiated smooth muscle cells with abundant thick-walled vascular channels (Figure 2). Mitotic figures and atypia were absent (Figure 3). No tumor necrosis or hemorrhage was found. Immunohistochemical studies found that the spindle cells expressed smooth muscle actin and desmin (Figure 4). However, tumor cells were negative for CD34, ER, and PR.

## 3. Discussion

Nasal cavity angioleiomyomas are extremely rare. The paucity of smooth muscle in the nasal cavity might explain why the tumors were rare. To date twenty-three cases have been reported in the literature. Of the 24 angioleiomyoma, including our case, 17 tumors occurred in female patients and only 7 in male patients. The overall average age was 53 years (range: 25–88 years). The most affected nasal sites are the nasal septum (n=8), the inferior

turbinate (n=7) and the vestibule (n=3). The other sites are superior and middle turbinate. The most common symptoms are: nasal obstruction (n=16) associated frequently with epistaxis (n=14). The other symptoms are headache (n=5) and facial pain (n=3).

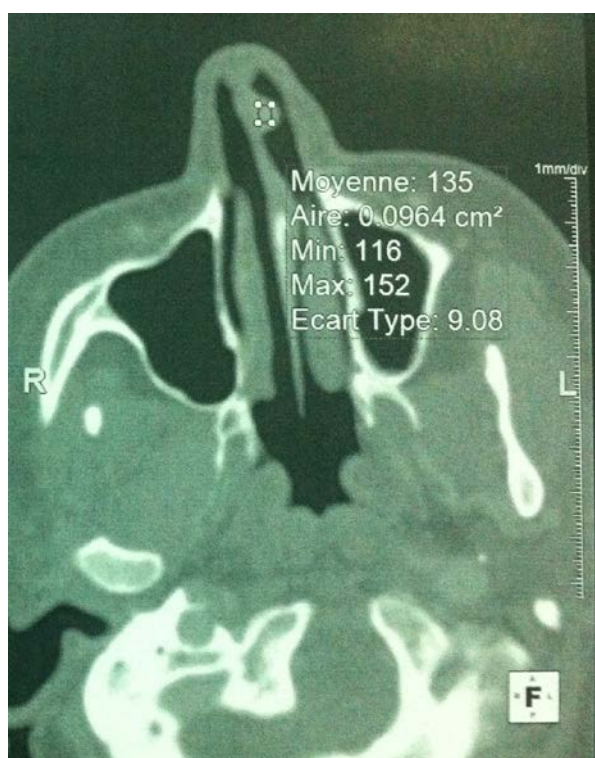Radiologically, the images are not specific [4], but CT and magnetic resonance imaging (MRI) could provide the information about the extent of the lesion.

It usually presents, macroscopically, as a solitary, well circumscribed nodule with sizes ranging from 5 to 20 mm. Microscopically, angioleiomyoma is separated into three subtypes: solid, venous and cavernous. It is characteristically composed of smooth muscle cells which are mature and well differentiated and numerous walled vessels. Mitotic figures are usually absent or very rare.

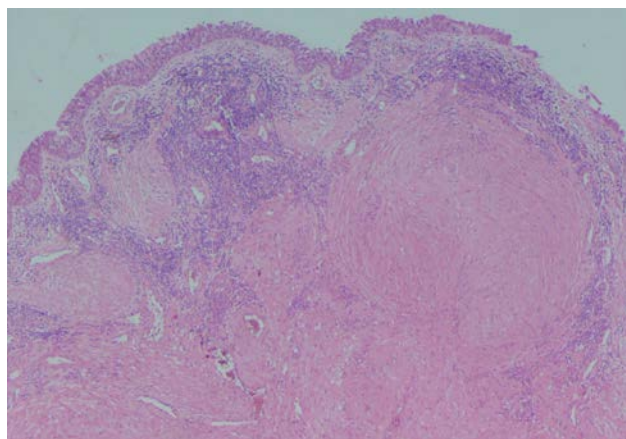
Most angioleiomyoma was diagnosed by microscopy with conventional Hematoxylin and Eosin staining. Differential diagnoses arise rarely with other spindle cell tumors such as angiofibroma, fibroma, angiomyolipoma, and angiosarcoma. Immunohistochemical examination can be helpful in these cases.

The etiology of sinonasal leiomyoma remains uncertain. Nasal cavity contains smooth muscle tissue in the walls of blood vessels and in the hair erector muscles of the anterior vestibule [4,5]. The advanced theories of this neoplasm are that the tumor cells derive from the wall of vessels, from the hair erector muscles or from some aberrant undifferentiated mesenchyma. Some authors documented case of a nasal leiomyoma and angioleiomyoma which express PR [6,7]. They suggest that the growth of this tumor may be hormone-dependent. In our case, the immunohistochemical study demonstrated that the tumor cells were negative for ER, and PR.

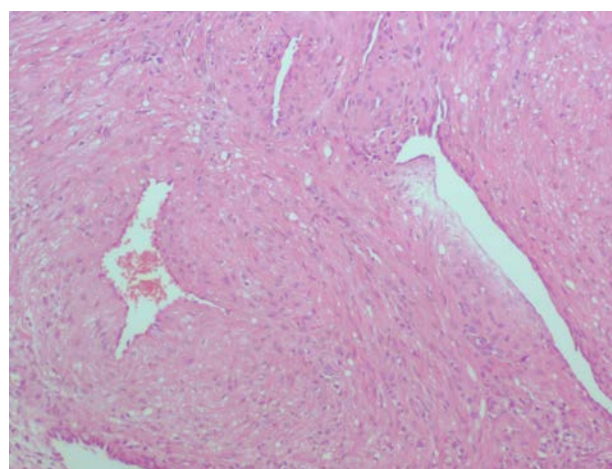
The treatment of choice is local surgical excision [6]. No recurrences were reported in follow-up studies of nasal cavity angioleiomyoma [1,4,6], like our case.



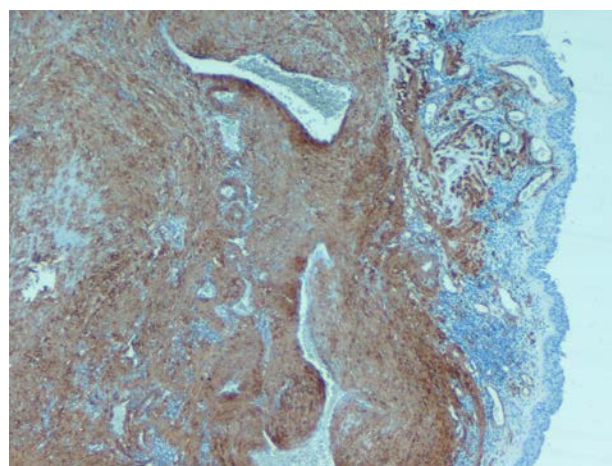
**Figure 1.** Round hyperechoic and hypervascular nodular lesion in the nasal septum, measuring 1.5 cm in diameter



**Figure 2.** The tumor is composed of abundant thick-walled blood vessels blending with proliferative smooth muscle tissue (Hematoxylin-eosin, original magnification x 40)



**Figure 3.** Spindle cells without atypia (Hematoxylin-eosin, original magnification x 100)



**Figure 4.** Spindle cells were immunoreactive for actin (Hematoxylin-eosin, original magnification x 40).

## Conflict of Interest

None.

## References

- [1] Michael RC, Shah S. Angioleiomyoma of the nasal cavity. *Indian J PatholMicrobiol.* 2009 Jul-Sep; 52 (3): 386-8.

- [2] Fletcher C.D.M., Unni K.K., Mertens F. (Eds.): World Health Organization Classification of Tumours. Pathology and Genetics of Tumours of Soft Tissue and Bone. IARC Press: Lyon 2002.
- [3] Poch-Viñals R. Angioleiomyoma of the nasal cavity. *Acta Otorinolaryngol Iber Am.* 1967; 18 (6): 538-46.
- [4] Campelo VE, Neves MC, Nakanishi M, Voegels RL. Nasal cavity vascular leiomyoma: case report and literature review. *Braz J Otorhinolaryngol.* 2008 Jan-Feb; 74 (1): 147-50.
- [5] He J, Zhao LN, Jiang ZN, Zhang SZ. Angioleiomyoma of the nasal cavity: a rare cause of epistaxis. *Otolaryngol Head Neck Surg.* 2009 Nov; 141 (5): 663-4.
- [6] Marioni G, Marchese-Ragona R, Fernandez S, Bruzon J, Marino F, Staffieri A. Progesterone receptor expression in angioleiomyoma of the nasal cavity. *Acta Otolaryngol.* 2002 Jun; 122 (4): 408-12.
- [7] Tseng PY, Lai YS, Chen MK, Shen KH. Progesterone receptor expression in sinonasal leiomyoma: a case report and review of the literature. *Int J Clin Exp Pathol* 2014; 7 (3): 1224-1228.