

# Pleomorphic Adenoma in Retromolar Area: A Rare Case Report and Review of Literature

Ajit Singh Rathore<sup>1,\*</sup>, Shivjot Chhina<sup>2</sup>, Kapil Garg<sup>2</sup>

<sup>1</sup>Department of Oral and Maxillofacial pathology, ITS Dental College, Hospital & Research Centre, Greater Noida, India

<sup>2</sup>Department of Periodontics, ITS Dental College, Hospital & Research Centre, Greater Noida, India

\*Corresponding author: [drathoreajit@yahoo.com](mailto:drathoreajit@yahoo.com)

Received April 18, 2014; Revised May 13, 2014; Accepted May 14, 2014

**Abstract** Pleomorphic adenomas are benign salivary gland tumors which represent about 3-10% of the neoplasms of head & neck region. They are the most common tumors comprising 50% of major & minor salivary gland tumors. The Palate is considered the most common (65%) and retromolar area uncommon (2.5%) intra oral site. A case of retromolar swelling diagnosed as pleomorphic adenoma of minor salivary glands is presented with review of literature of minor salivary gland tumors & pleomorphic adenoma.

**Keywords:** benign, minor salivary gland tumors, pleomorphic adenoma

**Cite This Article:** Ajit Singh Rathore, Shivjot Chhina, and Kapil Garg, "Pleomorphic Adenoma in Retromolar Area: A Rare Case Report and Review of Literature." *American Journal of Medical Case Reports*, vol. 2, no. 4 (2014): 90-93. doi: 10.12691/ajmcr-2-4-6.

## 1. Introduction

Salivary gland neoplasms are rare, comprising 1-4% [1] of all neoplasms and 3-5% [2,3] of all head & neck neoplasm. Minor Salivary gland tumors are infrequent accounting for 10-15% of all salivary neoplasms with a broad range of histopathological types and growth patterns. [4,5].

According to several studies like Auclair et al [6], Isaacson & Shear [7] the ethnicity & geographic location of population possibly affects frequency & distribution of salivary gland tumors. The considerable variability observed across studies is also in relation to different diagnostic criteria's which does not always follow the 1991 WHO classification [8]. The relative frequency of individual tumor types in some surveys is biased in favor of malignant tumor as the data is drawn from major cancer centers [9,10].

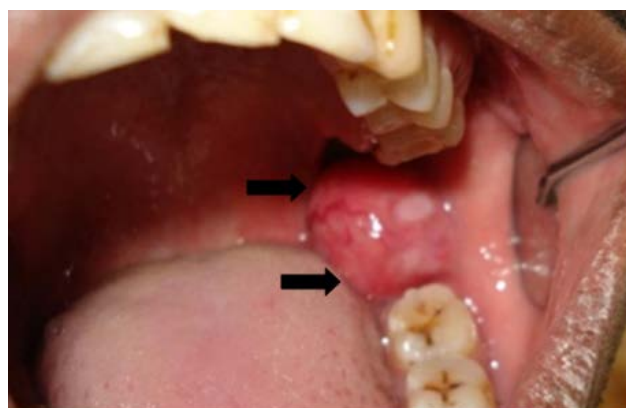
Pleomorphic adenoma is the most common benign salivary gland tumors. Palate is the most common intraoral site (42.8-68.8%) followed by upper lip (10.1%), cheek (5.5%) [2,11,12,13], other rare sites are throat (2.5%) retromolar region (.7%) floor of mouth & alveolar mucosa [12].

A rare case of pleomorphic adenoma of minor salivary gland in retromolar region is described.

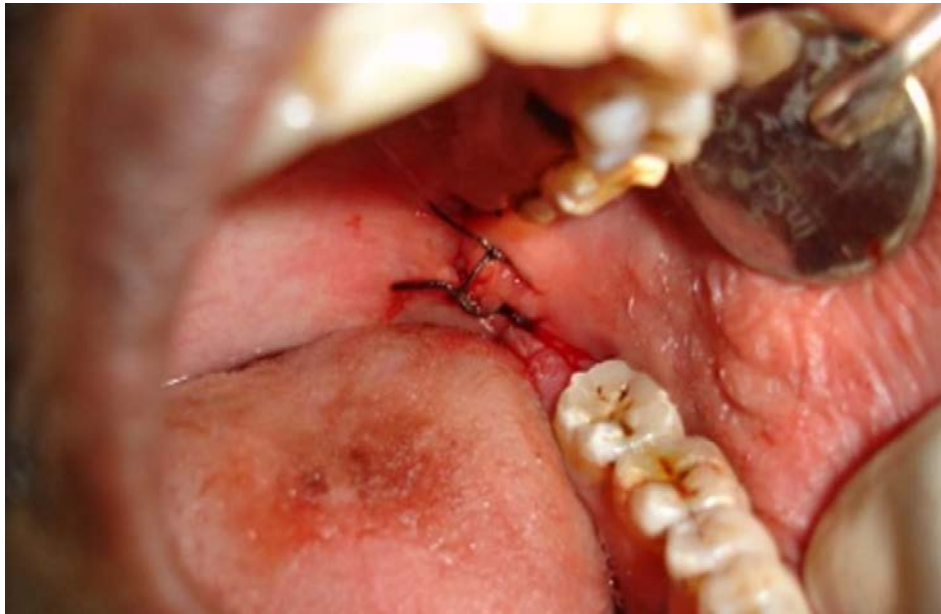## 2. Case Report

A 30 yrs old male patient presented to department of Periodontics with a slowly growing painless swelling in the left mandibular posterior region of two and half year duration. Clinical examination revealed a 3x3 cm, firm,

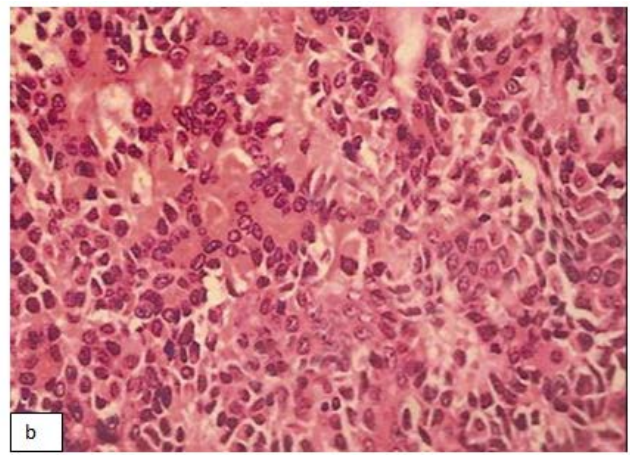
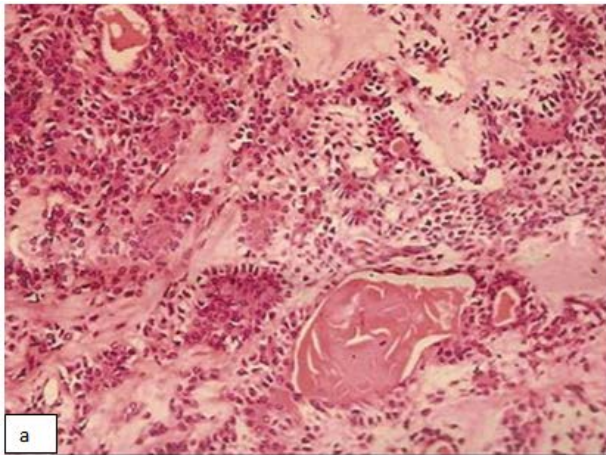
mass in retromolar area (Figure 1). There was no history of trauma, fever, disturbance of salivation or intraoral surgical procedure. The investigations revealed normal values. Panoramic radiograph showed no evidence of osseous involvement or calcification. The lesions was dissected & excised with safety margins under local anesthesia (Figure 2). Microscopically tumor islands were observed composed of epitheloid, plasmacytoid predominantly and spindle type neoplastic myoepithelial cells (Figure 3a). Ducts were seen scattered in stroma and tumor islands, the luminal side is lined with flat or cuboidal shaped cells and outer side with spindle cell type which are one to many in numbers. Outer layer of myoepithelial cells seems to be melting into stroma. Ducts were filled with eosinophilic coagulum. Stroma is mostly hyalinized and few areas appear fibromyxoid. Focal squamous differentiation with keratinization is seen (Figure 3b). Post operative follow up after six months shows uneventful healing (Figure 4).



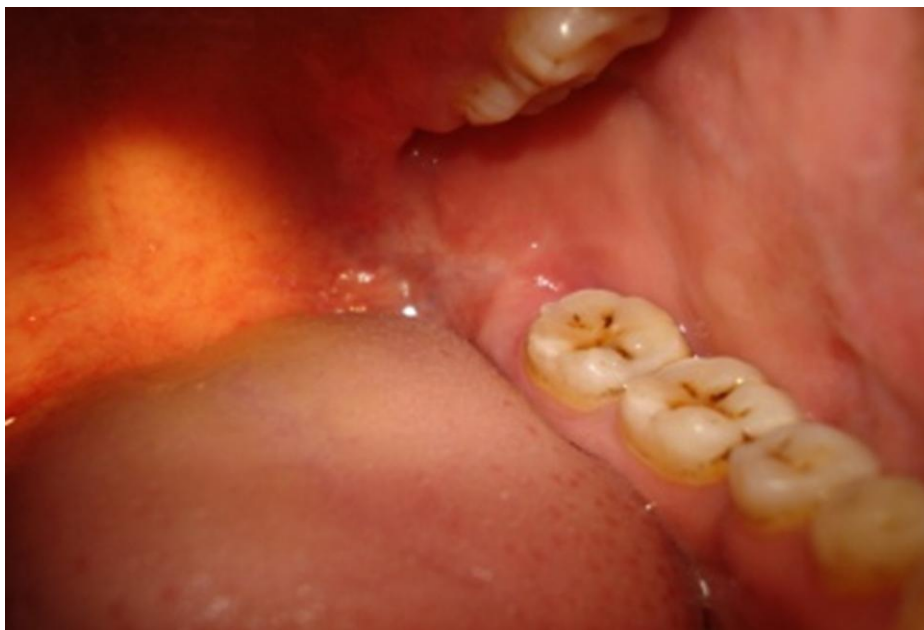**Figure 1.** Gross features of pleomorphic adenoma of retromolar area. Preoperative view showing round nodular growth in retromolar region



**Figure 2.** Postoperative view showing sutures placed after excision



**Figure 3.** Photomicrograph showing ducts with eosinophilic coagulum & surrounded by myoepithelial cells in hyalinised stroma. (a) Focal squamous differentiation with keratinization (H&E, x 100). (b) Tumor islands of myoepithelial cells in sheets and melting in stroma. Plasmacytoid hyaline myoepithelial cells (H&E, x 400)



**Figure 4.** Post-operative view after six month followup showing normal retomolar trigone region

### 3. Discussion

Pleomorphic adenoma is the most common minor salivary gland tumor in most studies [6,7,13,14,15,16,17], with incidence ranging from 33% to 70 % of all tumors [6,7,13,14,15,16,17] & from 70.6% [18] to 100% [10,11,17], of benign tumors. Issacson & Shear [7] reported 70%, Rivera Bastidas [18] about 85%, Japanese study revealed 57-62% [17], these incidences are higher than US [6,15,20] UK[16] & Australia where the percentage range was from 38.1%-54% [6], suggesting a regional variation. Other less common benign tumor percentage varied according to different study background like Waldron et al [20] reported monomorphic 19%, Cystadenoma 9%, Saliadenoma papilleferum 2%. Most studies have shown those minor salivary gland tumors are more common in females than male [7,16,17,21]. The tendency for female predominance has been reported to be especially marked in benign tumors, with male to female ratio of ranging from 1:1:8 [17] to 1:2.4 [18] Mean age of the patients of benign minor salivary gland tumor was around 51.8 yrs (range of 22-86 yrs). Pleomorphic adenoma is most common from 4-6<sup>th</sup> decade with mean age of 43-46 yr [11,12]. Isacson & Shear [7] reported a peak frequency in the third decade, which is in accordance to our case. Though Lucas [22] reported of peak frequency in the 5<sup>th</sup> – 6<sup>th</sup> decade.

Minor salivary gland tumors are located anywhere in the upper aero digestive tract, but the most frequent site is the oral cavity & mainly the palate [23]. In the series of Waldron et al [20], palate (42.5%) was most common. Other studies suggested higher presence of minor salivary gland tumor in palatal region, representing 65-86% of all tumors [4,8,13]. Studies suggesting the percentage of pleomorphic adenoma in retromolar trigone was not found, but percentage of benign tumors in retromolar trigone according to different studies are 5.4% by Waldron et al [20], 11.1%, by Pons-Vicente et al [3], 4.4% by Lopes et al [23], suggesting that retromolar area is an uncommon site for benign minor salivary gland tumors. Most studies indicate for malignant neoplasm in the retromolar trigone, suggesting that our case is rare in location.

Painless intraoral swelling was the most common symptom. Clinically involved cervical nodes or distant spread was not seen. The range of duration of symptoms is usually slow with mean time of 45 month which coincides with our history of pain less swelling for more than 2 yrs. Less common clinical signs & symptoms includes ulceration & ill fitting dentures, change in sensation & difficulty in speech.

Differential diagnosis of the growth in retromolar trigone is commonly mucocele, fibroma, neurilemmoma, malignant salivary gland tumor like mucoepidermoid carcinoma, solitary fibrous tumor which is mistaken for salivary gland tumor or uncommon pleomorphic adenoma as available literature only points to .7% of cases [12].

Pleomorphic adenoma has a tendency for local recurrence & some cases undergo malignant transformation. Treatment of choice for pleomorphic adenoma in minor salivary glands is wide local excision with removal of periosteum or bone if involved. Simple enucleation is believed to lead to a high local recurrence rate & should be avoided (24). Recent date suggest that recurrences is seen cases where surgery could not be performed properly.

### 4. Conclusion

Pleomorphic adenoma of retromolar area is a rare neoplasm however due to high predilection of recurrence and malignant transformations of minor salivary gland tumors, long term follow up is necessary. The present case report & review of literature of minor salivary gland tumors brings to light the wide variation in presentation of minor salivary gland tumors. Thus medical & dental practitioners should take them into account in any differential diagnosis when assessing intraoral pathology.

### Competing Interests

We certify that our manuscript is free of conflict of interest.

### Funding

None.

### Ethical Approval

Not required.

### References

- [1] Matsuba HM, Thawley SE, Simpson JR, Levine LA, Mauney M. adenocystic carcinoma of major and minor salivary gland origin. *Laryngoscope* 1984; 94: 1316-8.
- [2] Dalati T, Hussein RM. Juvenile pleomorphic adenoma of cheek. A case report and review of literature. *Diagn Pathol* 2009, 4: 32.
- [3] Pons-Vicente O, Almendros-Marques N, Berini-Ayres L, Gay-Escoda C. Minor salivary gland tumors: A clinicopathological study of 18 cases. *Med Oral Pathol Oral Cir Bucal* 2008 Sep 1; 13(9): E582-8.
- [4] Speight Pm Barrett AW. Salivary Gland tumors *Oral Dis* 2002 Sep; 8(15): 229-40.
- [5] Yih WY, Kratochvil FJ, Stewart JL. Intraoral minor salivary gland neoplasms: review of 213 cases. *J. Oral Maxillofac Surg.* 2005 June; 63(6): 805-10.
- [6] Auclair PL, Ellis GL, GNEPP DR, Wenig BM, Janney CG. Salivary gland neoplasms: general considerations. In: ELLIS GL, Auclair PL, GNEPP DR, eds: *Surgical Pathology of the salivary glands*, Philadelphia: W.B. Saunders Co. 1991: 135-164.
- [7] Issacson G, Shear M. Intraoral Salivary gland tumors: A retrospective study of 201 cases. *J Oral Pathol* 1983; 12: 57-62.
- [8] Siefert G. World Health Organization International Histological classification of tumors histological typing of salivary gland tumors. 2<sup>nd</sup> edn Berlin: Springer – Verlag 1992: 1-113.
- [9] Jansisyanont P, Blancharet Jr RH, ORD RA. Intraoral Minor salivary gland Neoplasm: a single institutional experience of 80 cases. *Int J oral Maxillofac Surg* 2002; 31: 257-261.
- [10] Tian Z, Li L, Wang L, Hu Y, Li J. Salivary gland neoplasms in oral and maxillofacial regions: A 23 year retrospective study of 6982 cases in eastern Chinese population. *Int J Oral Maxillofac Surg* 2010; 39(3); 235-42.
- [11] Van Heerden WF, Raubenheimer EJ. Intraoral salivary gland neoplasms: a retrospective study of seventy cases in African population. *Oral Surg Oral Med Oral Pathol* 1991; 71: 579-82.
- [12] Wang D et al. Intraoral minor salivary gland tumors in a Chinese population: a retrospective study on 737 cases. *Oral Surg Oral Med Oral Pathol Oral Radiol endod* 2007; 104: 94-100.
- [13] Toida et al. Intraoral minor salivary gland tumors: a clinicopathologic study of 82 cases. *Int J Oral Maxillofac Surg* 2005; 34: 528-32.
- [14] Chaudhry et al. Clinicopathologic and histogenetic study of 189 intraoral minor salivary gland tumors. *J Oral Med* 1984; 39: 58-78.

- [15] Chaudhry AP, Vickers RA, Gorlin RJ. Intraoral minor salivary gland tumors: an analysis of 1,414 cases. *Oral Surg Oral Med Oral Pathol* 1961; 14: 1194-1226.
- [16] Eveson JW, Cawson RA. Tumors of minor (oropharyngeal) salivary glands: a demographic study of 336 cases. *J Oral Pathol* 1985; 14: 500-509.
- [17] Kasuma K et al. Intraoral minor salivary gland tumors: a retrospective study of 129 cases. *Nihon Univ Sch Dent* 1997; 39: 128-132.
- [18] Rivera Bastidas H, Ocanto RA, Acevedo AM. Intraoral minor salivary gland tumors a retrospective study of 62 cases in a Venezuelan population. *J Oral Pathol Med* 1996; 25: 1-4.
- [19] Bardwill JM, Reynolds CT, Ibanez ML, Luna MA. Report of 100 tumors of minor salivary glands. *Am J Surg* 1966; 112: 493-497.
- [20] Waldron CA, Et-Mofty S, Gnepp DR. tumors of the intraoral minor salivary glands : a demographic and histological study of 426 cases. *Oral Surg Oral Med Oral Pathol* 1988; 66: 323-333.
- [21] Van Der Wal JE, Snow GB, Van Der Wal I. histological reclassification of 101 intraoral salivary gland tumors (new WHO classification). *J Clin Pathol* 1992; 45: 834-835.
- [22] Lucas RB. In: Cawson RA, Speigt P, Binnie WH, Wright J, eds: *Pathology of Tumors of Oral tissues* 3<sup>rd</sup> edn. London: Churchill Livingstone 1976.
- [23] Lopes MA, Kowalski LP, Da Cunha Santos G, Paes de Almedda O. A clinicopathologic study of 196 intraoral minor salivary gland tumors. *J Oral Pathol Med*.1999 Jul; 28(6): 264-7.
- [24] Berardi D, Scoccia A, Perfitti G, Berardi S. Recurrence of pleomorphic adenoma of the palate after sixteen years : case report and analysis of literature. *J Biol Regul Homeost Agents*. 2009; 23(4): 225-9.