

Chondroblastoma of the Lower Thoracic Spine. A Case Report and Review of the Literature

Walid Osman¹, Afif Zaoui², Soumaya Ben Abdelkrim^{3,*}, Riadh Ben Hamida¹, Mohamed Ben Ayèche¹

¹Department of orthopaedics, Sahloul University Hospital, Sousse, Tunisia

²Department of psychiatrics, Sahloul University Hospital, Sousse, Tunisia

³Department of Pathology, Farhat Hached University Hospital, Sousse, Tunisia

*Corresponding author: benabdelkrims@voila.fr

Received April 24, 2014; Revised May 07, 2014; Accepted May 07, 2014

Abstract Background: Chondroblastoma of the spine is a very rare condition. To the best of our knowledge, fewer than 30 cases have been reported in the world literature. Material and methods: The authors describe here a rare spinal localization with an uncommon evolution and make a review of the cases of spinal chondroblastoma reported in the literature. Results: We report the case of a patient with chronic back pain and progressive weakness of both lower limbs. Computed tomography scan showed a mass infiltrating the twelfth thoracic vertebra and adjacent structures. The patient underwent surgery and subtotal removal was achieved while a posterior stabilization was performed. Pathological examination revealed a chondroblastoma. During follow-up, MRI examination revealed that the tumor had locally relapsed; nevertheless, the patient was asymptomatic for 13 years after operation. Conclusion: Spinal chondroblastoma has an aggressive behavior with high recurrence and mortality rates.

Keywords: *chondroblastoma, spine origin, diagnosis, histology, outcome*

Cite This Article: Walid Osman, Afif Zaoui, Soumaya Ben Abdelkrim, Riadh Ben Hamida, and Mohamed Ben Ayèche, "Chondroblastoma of the Lower Thoracic Spine. A Case Report and Review of the Literature." *American Journal of Medical Case Reports*, vol. 2, no. 4 (2014): 78-81. doi: 10.12691/ajmcr-2-4-2.

1. Introduction

Chondroblastoma is a benign cartilaginous bone tumor arising most often in the epiphysis of long bones during the second and third decades. The most common sites are the proximal tibia, proximal and distal femur, and proximal humerus [1]. Chondroblastoma of the spine is a very rare condition. To our knowledge, fewer than 30 cases have been reported in the world literature.

2. Case Report

In September 1999, an 18-year-old man presented with a one year history of back pain and gradual progressive weakness of both lower limbs of 6 months duration. On physical examination, he could not flex or extend his back because of significant pain. He had tenderness to palpation over the lower thoracic paravertebral region. A neurological examination revealed a severe paresis of the right lower limb (grade-1 strength, according to the scale of the Medical Research Council, both proximally and distally), and weakness of the left lower limb (grade-3 strength of the iliopsoas and quadriceps muscles and grade 2 strength of the anterior tibial, peroneal, extensor hallucis longus, and triceps surae muscles). Caudad to the tenth thoracic level, the sensibility was diminished for pain, temperature, vibration, and light touch. The

deep tendon reflex of the lower limbs was exaggerated, and a Babinski sign was present bilaterally. Radiographs of the spine showed an ill-defined osteolytic lesion on the left in the twelfth thoracic vertebra with erosion of the pedicle and transverse process and involvement of the left costo-vertebral joint. There was fine calcification over the left paraspinal region (Figure 1). A computed tomography (CT) scan of the thoracic spine revealed a mass infiltrating the twelfth thoracic vertebra with soft tissue extension into the left paraspinal muscles, as well as narrowing of the epidural space. An operation was considered. By a posterior approach, he underwent a decompressive laminectomy of T11, T12 and L1 and a thorough intralesional excision involving the posterior elements and the vertebral body. A spinal stabilization was performed with a posterior fusion from D10 to L2 using 2 plates of Roy-Camille and bone grafting. There was no neurological complication following operation. Pathological diagnosis was benign chondroblastoma (Figure 2). The postoperative course was uneventful and the patient's symptoms resolved. Neurological recovery was prompt within a few days. Instrumentation was removed after 3 years (Figure 3). After an 11-year follow-up, the patient remained free of symptoms. Radiographs of the spine showed a large osteosclerosis of the left half of T12. CT scan demonstrated a heterogeneous well marginated lesion with peripheral partial osteocondensation.

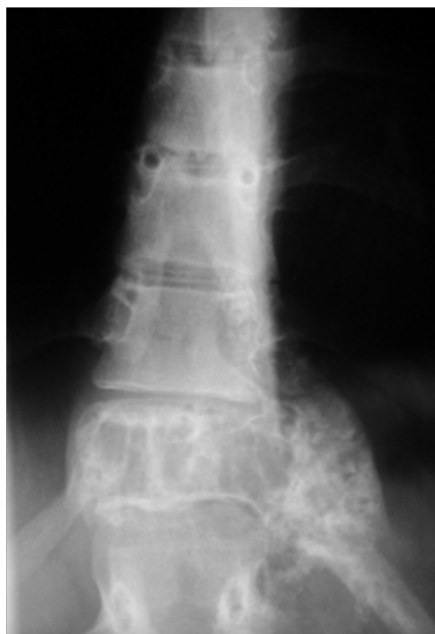

Figure 1. AP X-ray of thoracic spine demonstrated an ill-defined osteolytic lesion on the left in the twelfth thoracic vertebra with erosion of the pedicle and transverse process and involvement of the left costovertebral joint with soft tissue shadow and calcification

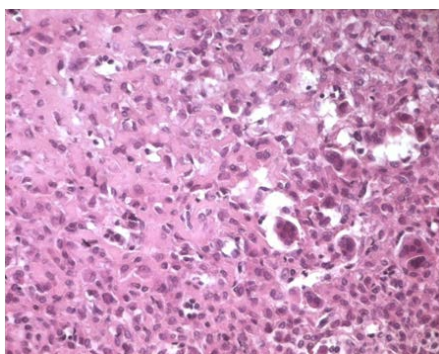


Figure 2. Histological examination revealed that the tumor contains large mononuclear cells mixed with osteoclast-like giant cells growing in a chondroid matrix (hematoxylin and eosin stain, original magnification $\times 100$)

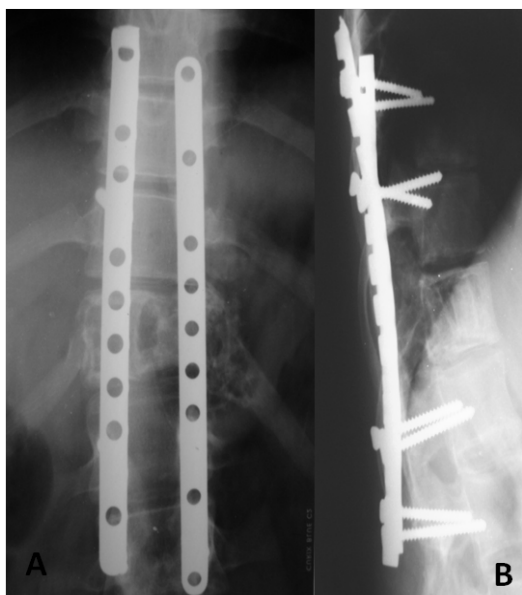


Figure 3. Anteroposterior (A) and Lateral (B) thoracic radiographs obtained 3 year after operation showing fusion of the arthrodesis

Follow-up MRI examination in December 2012 revealed that the tumor had locally relapsed without involvement of the spinal canal with high signal areas of the left half of T12 and enhancement after gadolinium injection (Figure 4). The patient was last examined in March 2011. He was clinically well.

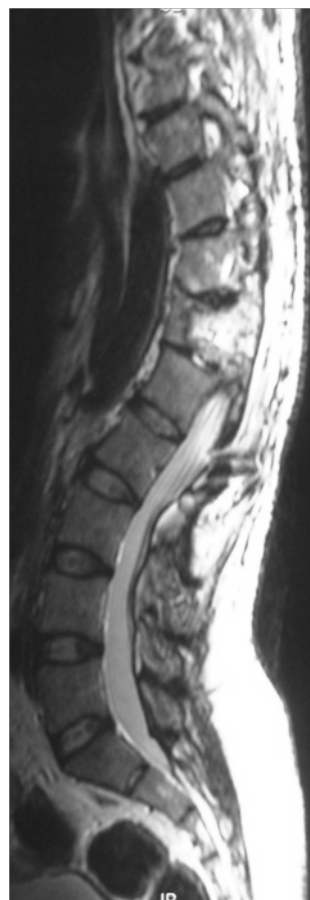

Figure 4. MRI of the thoracic spine: sagittal view (T2-weighted image) illustrating local relapse of the tumor

3. Discussion

Chondroblastoma is a well-known tumor first described by Ewing as a calcifying giant cell tumor in 1928 [1] and shown by Codman to be of cartilaginous origin [2]. It accounts for about 1% of primary bone tumors [3,4] and is considered to be benign with good prognosis in the majority of cases. It most frequently involves the bones around the knee, proximal humerus, and proximal femur [5]. Although chondroblastomas occur most often in the epiphysis of the major tubular bones, this tumor can appear in any secondary ossification center, such as greater trochanter. The vertebra also has a secondary ossification center, but it is an exceedingly rare location. To the best of our knowledge, 28 cases of chondroblastoma occurring in the vertebra were reported in the literature, including 19 case reports [6-24] and one series of 9 cases [18]. These cases are summarized in Table 1.

Most of these cases occurred in the lumbar vertebra. This localization represents 1.4% of all chondroblastomas in the file of the Mayo clinic [18]. The age range of the patients with vertebral chondroblastoma is from 9 to 62 years with a mean age of 29 years, which suggests that

this vertebral localization is clinically apparent a decade later than its appendicular counterpart. The patients in most case reports were predominantly male with a sex ratio of 2.5. Clinical findings of spinal chondroblastoma are usually non specific, including diffuse back pain, neck stiffness or thightness [11], dyspnea due to tracheal compression by the tumor [10]. Depending on the extent of spinal cord compression, a wide variety of neurological symptoms and signs may be noted later including pain radiating into fingers, sciatica, muscle weakness and tetraparesis [12,14,15]. The radiological features of vertebral chondroblastoma are not specific. The lesion in

imaging appears aggressive and expansive, with almost all cases showing destructive bony lesion with a large soft tissue mass and significant spinal cord compression [19]. There are only two reports describing the radiological features of vertebral chondroblastoma [18,19]. In a study of 9 patients with spinal chondroblastoma, Ilaslan and al [18] noted 7 with tumors on axial imaging showing spinal canal invasion and spinal cord compression. The clue to the cartilaginous nature of the lesion lies in the detection of calcification. Ilaslan et al [18] identified calcifications to varying degrees in 7 patients. The body and posterior elements are usually involved.

Table 1. Summary of previous published case reports of vertebral chondroblastoma

Author	No. of cases	Sex/age	Neurolo-gical deficit	location	Extent	Operation	Follow-up
Braczewski et al (1957) [6]	1	M/28	Yes	T3/T4	STE	Laminectomy and debulking	24 months symptom-free
Ehalt et al (1967) [7]	1	M/12	NS	Cervical spine	NS	Surgical treatment	Recurrence
Wisniewski et al (1973) [8]	1	M/17	No	C1, C2	STE	Curettage	NS
Akai et al (1986) [9]	1	M/48	No	S1	STE	Curettage	120 months Recurrence and death from renal failure
Hoeffel et al 1987 [10]	1	M/9	Yes	C7	STE	Repeated surgery	72 months Recurrence and death from tetraplegia
Howe et al (1988) [11]	1	M/16	Yes	C5, C6	ST E	Combined anterior and posterior surgery	No information
Kurth et al (2000) [12]	1	M/62	No	T1, T2	ST E	Repeated surgery	4 recurrences Malignant transformation
Shin et al (2001) [13]	1	F/36	NO	L1	NO	Mass excision	14 months NED
Leung et al (2001) [14]	1	F/54	Yes lower limb weakness	L5	SCE and STE	Intracapsular tumor excision, L5 vertebrectomy	Two recurrences then lost to follow-up
Nishida et al (2001) [15]	1	M/19	Yes tetraparesis	C5, C6, C7	SCE and STE	Thorough curettage. combined anterior and posterior approaches	2 years and 3 months NED Neurologic deficit fully recovered NED
Attar et al (2001) [16]	1	M/48	No	T2	SCE	Thorough curettage. combined anterior and posterior approaches	NS
Shung et al (2003) [17]	1	M/54	Yes Cauda equine syndrome	L5	SCE and STE	Combined anterior and posterior surgery. intralesional excision	Two recurrences Death after 44 months
Ilaslan et al (2003) [18]	9	Mean age 28, 6M & 3F	NS	C2,T5, L1, S1	SCE in 6 cases & STE in all cases	NS	NS
Vialle et al (2005) [19]	2	F/55, F/23	No	L4/L3	NS	Vertebrectomy in two cases	6 years NED 3 years NED
Lee YH et al (2005) [20]	1	M/40	Yes lower extremity weakness	T7	SCE and STE	Combined anterior and posterior surgery, T7 vertebrectomy	NS
Sohn et al (2009) [21]	1	M/21	No	L4	Lung metas-tasis	Total laminectomy of L4, thoracic surgery for pulmonary biopsy	3 years NED
Mohamed et al (2011) [22]	1	M/46	No	T12L1	STE	Total laminectomy T11T12L1	Died one day after operation because of bleeding
Hernández Martínez et al (2011) [23]	1	F/30	No	L4	NO	NS	NS
Kim SA et al (2011) [24]	1	M/25	No	L3	SCE	Total tumor resection	18 months NED

NS: non specified, STE: soft tissue extension, SCE: spinal canal extension, NED: non evidence of disease

Local relapse is not an uncommon feature of vertebral chondroblastoma. There are at least six reported cases showing tumor relapse [7,9,10,12,14,17]. Three of these patients died from their disease [9,10,17]. One death

followed tetraplegia [10], in another case there was recurrence into the pelvis producing obstructive uropathy and death from renal failure [9]. Another patient died from several neurological and medical complications after recurrences [17]. There is one published report of malignant transformation of chondroblastoma. This was a tumor that recurred several times in the upper thoracic spine [12].

The clinical course of our patient was characterized by non-invasive growth of a histologically confirmed chondroblastoma and by asymptomatic tumor progression for 12 years after the operation. Likewise, Ehalt and Ratzenhofer [7] described a 12-year-old boy with a chondroblastoma in the cervical spine; that tumor progressed after surgery. Despite the tumor showed evidence of progression, the patient was asymptomatic for 15 years after the operation.

Considering the reported cases and the clinical course of our patient, it must be assumed that there is a more frequent relapse and mortality in spinal chondroblastomas than in chondroblastomas at extraspinal sites. Some authors suggest that the higher rate of relapse is related to aggressive behavior of the tumor, which is similar to chondroblastomas of type II and III [12]. This may be related to the frequent extension to adjacent soft tissue and to spinal canal, which precludes complete tumor resection [14]. Therefore, complete excision is generally recommended as the primary treatment of choice for vertebral chondroblastoma [14,17,19]. However, frequent involvement of the spinal canal and paraspinal muscles makes it difficult to completely remove the tumor without neurological deficit. Radiotherapy is useful for cases that recur or inoperable cases [14]. Since there is a high recurrence rate and difficulty to achieve a complete resection, patients with vertebral chondroblastoma have to be closely followed on a long term basis.

4. Conclusion

This is a rare case report of chondroblastoma of the lower thoracic spine. The clinical profile of this patient and the evidence from the literature review suggest that spinal chondroblastoma has an aggressive behavior with high recurrence and mortality rates. Preoperative assessment by CT scan and MRI and primary en bloc excision may be the only chance to eradicate this tumor. Spinal fusion and long posterior instrumentation are necessary at this junctional level. Long-term clinical follow-up is recommended because of higher recurrence rate and neurological complications.

References

- [1] Ewing, J., (1928) the classification and treatment of bone sarcoma. Report of International Conference on Cancer (Bristol), J Write, 1928, 265-267.
- [2] Codman, E.A., "Epiphyseal chondromatous giant cell tumors of the humerus". Surg Gynecol Obstet, 52, 543-548, 1931.
- [3] Dahlin, D.C., Ivin, J.C., "Benign chondroblastoma: a study of 125 cases". Cancer, 30(2), 401-413, Aug 1972.
- [4] Kurt, A.M., Unni, K.K., Sim, F.H., McLeod, R.A., "Chondroblastoma of bone". Hum Pathol, 20, 965-976, Oct 1989.
- [5] Huvos, A.G., Marcove, R.C., "Chondroblastoma of bone: a critical review". Clin Orthop, 95, 300-312, 1973.
- [6] Buraczewski, J., Lysakowska, J., Rudowski, W., "Chondroblastoma (Codman's tumour) of the thoracic spine". J Bone Joint Surg Br, 39-B(4), 705-710, 1957.
- [7] Ehalt, W., Ratzenhofer, M., "On the case history of a benign chondroblastoma". Z Orthop Ihre Grenzgeb, 102(4), 625-629, 1967.
- [8] Wisniewski, M., Toker, C., Anderson, P.J., Huang, Y.P., Malis, L.L., "Chondroblastoma of the cervical spine. Case report". J Neurosurg, 38(6), 763-766, 1973.
- [9] Akai, M., Tateishi, A., Machinami, R., Iwano, K., Asao, T., "Chondroblastoma of the sacrum. A case report". Acta Orthop Scand, 57(4), 378-381, 1986.
- [10] Hoeffel, J.C., Brasse, F., Schmitt, M., Plenat, F., Vignaud, J.M., Czorny, A., Montaut, J., Marchal, A.L., "About one case of vertebral chondroblastoma". Pediatr Radiol, 17(5), 392-396, 1987.
- [11] Howe, J.W., Baumgard, S., Yochum, T.R., Sladich, M.A., "Case report 449: Chondroblastoma involving C5 and C6". Skeletal Radiol, 17(1), 52-55, 1988.
- [12] Kurth, A.A., Warzecha, J., Rittmeister, M., Schmitt, E., Hovy, L., "Recurrent chondroblastoma of the upper thoracic spine. A case report and review of the literature". Arch Orthop Trauma Surg, 120(9), 544-547, 2000.
- [13] Shin, B.J., Yun, T.K., Lim, K.C., Lee, J.C., Kim, K.J., Kim, D.W., Kim, Y.I., "Chondroblastoma of the first lumbar vertebra: a case report". J Korean Soc Spine Surg, 8, 90-95, 2001.
- [14] Leung, L.Y., Shu, S.J., Chan, M.K., Chan, C.H., "Chondroblastoma of the lumbar vertebra". Skeletal Radiol, 30(12), 710-713, Dec 2001.
- [15] Nishida, J., Kato, S., Murakami, H., Ehara, S., Satoh, T., Okada, K., Shimamura, T., "Tetraparesis caused by chondroblastoma of the cervical spine: a case report". Spine (Phila Pa 1976), 28(9), E173-178, May 2003.
- [16] Attar, A., Ugur, H.C., Caglar, Y.S., Erdogan, A., Ozdemir, N., "Chondroblastoma of the thoracic vertebra". J Clin Neurosci, 8(1), 59-60, Jan 2001.
- [17] Shung, O.M., Yip, S.F., Ngan, K.C., Ng, W.F., "Chondroblastoma of the lumbar spine with cauda equina syndrome". Spinal Cord, 41(6), 359-364, Jun 2003.
- [18] Ilasslan, H., Sundaram, M., Unni, K.K., "Vertebral chondroblastoma". Skeletal Radiol, 32(2), 66-71, Feb 2003.
- [19] Vialle, R., Feydy, A., Rillardon, L., Tohme-Noun, C., Anract, P., Colombat, M., De Pinieux, G., Drapé, J.L., Guigui, P., "Chondroblastoma of the lumbar spine. Report of two cases and review of the literature". J Neurosurg Spine, 2(5), 596-600, May 2005.
- [20] Lee, Y.H., Shin, D.A., Kim, K.N., Yoon, H., "A case of thoracic vertebral chondroblastoma, treated with 3-D Image Resection and Reconstruction". J Korean Neurosurg Soc 37, 154-156, 2005.
- [21] Sohn, S.H., Koh, S.A., Kim, D.G., Park, S.W., Lee, K.H., Kim, M.K., Choi, J.H., Hyun, M.S., "A case of spine origin chondroblastoma metastasis to lung". Cancer Res Treat, 41(4), 241-244, Dec 2009.
- [22] Mohamed, B., Madiha, M., Ridha, S., Abdelaziz, Z., Khelil, E., Mondher, K., Mongi, Z., "Aggressive spinal chondroblastoma". Tunis Med, 88(2), 134-136, Feb 2010.
- [23] Hernández Martínez, S.J., Campa Núñez, H., Ornelas Cortinas, G., Garza Garza, R., "Chondroblastoma of the fourth lumbar vertebra diagnosed by aspiration biopsy: case report and review of the literature". Acta Cytol, 55(5), 473-477, 2011.
- [24] Kim, S.A., Cho, K.J., Park, Y.K., Lee, J.S., Kwon, H.J., Chung, H., Kim, M.J., "Chondroblastoma of the lumbar spine. A case report and review of the literature". Korean Journal of Pathology, 45, 532-536, 2011.