

# The Challenges of Treating Malpositioned Teeth in Complete and Partial Occlusal Rehabilitations

Wedad A Mashali<sup>1,\*</sup>, Sharifah Wafi<sup>2</sup>, Mona Al Homoud<sup>2</sup>

<sup>1</sup>Ministry Of Health, Primary Health Center, Jazan, Saudi Arabia

<sup>2</sup>Ministry Of Health, Primary Health Center, Abha, Saudi Arabia

\*Corresponding author: [drwedad\\_mesh@yahoo.com](mailto:drwedad_mesh@yahoo.com)

Received March 20, 2024; Revised April 22, 2024; Accepted April 29, 2024

**Abstract** In a properly functioning natural human permanent dentition, the importance of each individual tooth falling appropriate to its pre designed position is responsible for normal functioning without causing aberrant problems. Malpositioned tooth (MT) alters the physiological balance of natural dentition which renders the natural ability of self cleansing incompetent, besides creating conducive environment for plaque accumulation and initiating periodontal diseases. MT are conservatively corrected by orthodontic tooth movements but due to long term treatment and expenses, many patients do not prefer such correction. In such cases, alternative correction is by prosthodontic means which has its own limitations. In many other cases there is a compromise in treatment planning, since the inclusion of MT does not allow clinician to implement ideal treatment plan. This article in the form of case report presents one such case where multiple MT were accommodated in the treatment plan where both fixed partial and removable partial dentures were designed. The patient was treated in phases and had to undergo many restorative, endodontic and surgical procedures as part of pre prosthetic mouth preparations. The patient was satisfied with the outcome of the treatment plan.

**Keywords:** orthodontics, fixed partial denture, cast partial denture, abutment tooth, metal ceramic restoration

**Cite This Article:** Wedad A Mashali, Sharifah Wafi, and Mona Al Homoud, "The Challenges of Treating Malpositioned Teeth in Complete and Partial Occlusal Rehabilitations." *American Journal of Medical Case Reports*, vol. 12, no. 5 (2024): 73-77. doi: 10.12691/ajmcr-12-5-2.

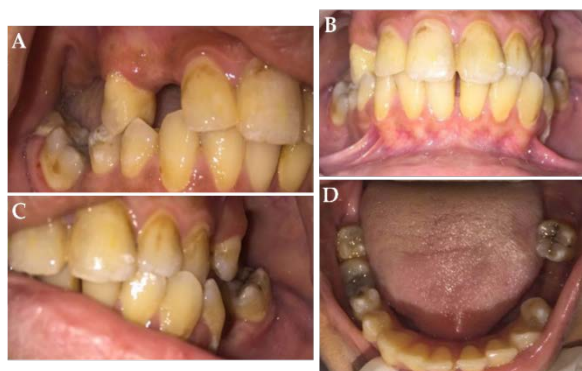
## 1. Introduction

Natural permanent teeth undergo their initial development within the alveolar bone and once calcification of various tissues is under process or complete, the teeth begin to assume their functional positions in the oral cavity, till they come in contact with their respective opposite and adjacent tooth/teeth. There are several influences that can prevent a tooth to assume its functional position which are broadly categorized as local and systemic [1]. Most of the times it is the local causes that alter tooth positions thereby rendering them to be termed as a malpositioned tooth (MT). Once a tooth is malpositioned it inevitably leads to malocclusion, sooner or later, which is considered by some to be the third most significant problem that affects the oral cavity [2]. While malpositioned deciduous teeth may precede permanent teeth, the malpositioned permanent tooth may occur independently of that. Preventive orthodontic and pedodontic care ensures avoiding or reducing malocclusion in permanent/mixed dentitions [3]. According to the basis of developing malocclusion, the forces exerted by the muscles surrounding the erupting teeth plays one of the most significant and major roles in determining whether the tooth will assume proper or

improper position [2]. Retention of deciduous teeth, gross decay of deciduous/permanent teeth, early loss of natural teeth are some of the wide clinical scenarios which can lead to malpositioning of the tooth. Losing natural tooth without replacing it produces sluggish changes in occlusion in various forms (migration, supra eruption) that alters the position of erupting teeth [4]. A malpositioned tooth creates imbalance in the entire natural dentition and primarily affects the self cleansing ability of natural tooth contours and contacts. Altering the height of contour to either favorable or unfavorable may result in either increased or decreased plaque accumulation which in turn may lead to caries and periodontal diseases [5,6]. However, malpositioned teeth may also serve a lifetime without causing any problem in the oral cavity except being unaesthetic. Malpositioning may also lead natural teeth more vulnerable to tooth wear or attrition especially if the individual has underlying parafunctional habits [7]. Studies have shown that patients with malpositioned teeth had oral hygiene that was considered deficient from normal standards [2,5]. Tooth malpositioning may take shape in any form but commonly they are seen as diastema, rotations, crowding, proclination/retroclination, tipping, mesial/distal migration. As the tooth changes axially, its relation with surrounding bone crest also changes making it less or more vulnerable to periodontal disease [8].

Treating a malpositioned tooth/ teeth is easily accomplished at a young age through dentofacial orthopedic and orthodontic interventions but correction of such teeth at a later age becomes more challenging. In such cases, choosing correct approach is significantly associated with treatment success [9]. Some approaches may give desired results for the clinicians but may be time consuming and/or economically non viable for the patient (as in orthodontic correction) while in other cases it may be just the opposite. Patients approaching restoring natural teeth underestimate the needs and demand for prosthodontic services which are difficult to measure in such cases [10]. At the same time all dental treatment are highly individualistic and not necessarily related to patients ability to masticate or not [11]. A patient may estimate that only prosthodontic care is required while overlooking the need for preprosthetic preparations [12]. In addition to the routine prosthodontic care other procedures including surgeries (crown lengthening, pulpectomy) may be necessary to manage malpositioned tooth to accomplish occlusal rehabilitations [13]. Conservatively, MT can be corrected by orthodontic procedures utilizing a removable or fixed appliance. The treatment may range from a period of 6 months to 24 months depending upon the nature, position and number of teeth [14,15]. These teeth may be corrected utilizing prosthodontic correcting options like cast post core, but has limitations in term of severity of malpositioning. Once MT is accompanied by rotation, prosthodontic correction becomes more difficult. Some drawbacks of prosthodontic corrections includes the changes that are induced in the quality and quantity of plaque accumulation by a prosthesis especially a removable partial prosthesis [16].

This article in the form of a case report presents a case of occlusal rehabilitation with presence of multiple Malpositioned teeth in the mandibular arch that influenced the choice of treatment between a fixed partial and a removable partial denture. The occlusion was finally completely rehabilitated with a combination of fixed and removable prosthodontics.

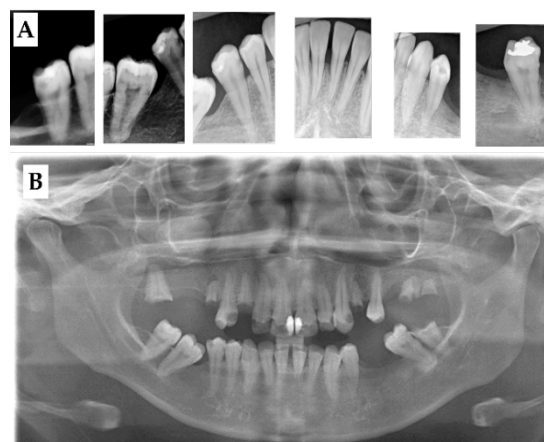


**Figure 1.** (A) Intra oral view showing right premolar only tooth maintaining vertical dimensions (B) Frontal view showing decreased overjet and left canine in a cross bite (C) Close up of left canine in cross bite (D) Occlusal view showing malpositioned teeth in mandibular arch

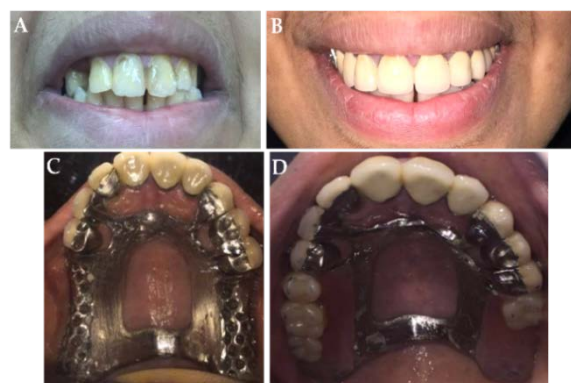## 2. Case Report

An elderly female patient aged 43 years old, with no present or past medical history reported to the department

of prosthodontics with chief complaint of inability to mastication and poor appearance due to loss and discoloration of the natural teeth. The patient's related past medical, social, drug and dental history did not reveal any significant influence that would have impacted the current treatment planning. The patient's extra oral facial features were within standard normal limits. Intra oral examination before final treatment planning was Kennedy class 3 modification 2 in maxillary arch and Kennedy class 3 modification 1 in mandibular arch. The entire natural dentition was poorly maintained with high level of plaque accumulation. On the right side the vertical dimensions were maintained by a sole maxillary first premolar (Figure 1A), with anterior teeth showing decreased overjet (Figure 1B), with left maxillary canine in a crossbite with opposing canine (Figure 1C). The mandibular anterior showing mild spacing and malpositioning (rotation) and migration in the posterior segment (Figure 1D). a detailed radiographic investigation included the full complement of intra oral peri apical view and orthopantomograph (Figure 2 A, B), which revealed multiple teeth having caries lesions that extended to the pulp, the periodontal status of anterior teeth which had undergone spacing and the malpositioned teeth in both arches. In total 11 teeth in mandibular arch and 6 in the maxillary arch were not properly inclined before treatment planning (Figure 2B).



**Figure 2.** (A) Intra oral peri apical radiographs of anterior and posterior mandibular teeth showing occlusal caries and spacing between teeth (B) Orthopantomograph at the time of diagnosis showing grossly decayed teeth and edentulous areas

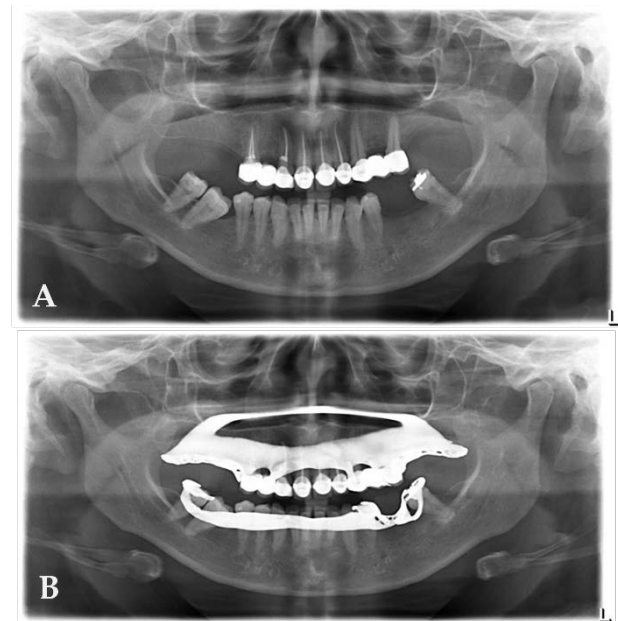


**Figure 3.** (A) Intra oral view showing incisal plane after correction (B) Maxillary arch restored with single metal ceramic crowns and two three unit fixed partial dentures on either side (C) Maxillary cast partial denture framework trial (D) Occlusal view of maxillary arch showing fixed and removable partial dentures

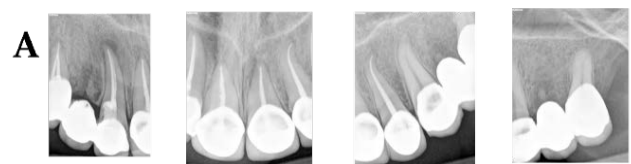
To plan the treatment, various phases were organized and a multidisciplinary approach was planned that included 4 major dental specialist's headed by prosthodontist [17]. The patient had no emergency phase therefore no treatment was considered to be necessary. In the second phase the patient was first educated and motivated before undergoing oral prophylaxis and excavation of decay from all the teeth. A preliminary diagnostic impression was made using irreversible hydrocolloid (Jeltrate Alginate, Fast Set; Dentsply Intl, York, Pa) and casts were poured (Elite Model; Zhermack, Badia Polesine, Rovigo, Italy), which were then mounted on a semi adjustable articulator (Artex; Girrbaach Dental) using relevant face bow (Artex Rotofix-Facebow; Girrbaach Dental, Pforzheim, Germany). The articulator was then programmed using centric records and taking averages. Treatment plan consisted of various treatment options that ranged from single implant supported crowns to fixed partial dentures and cast partial denture. Pre prosthetic mouth preparation that was decided was extraction of 6 maxillary and 1 mandibular root stumps, endodontic treatment of maxillary anterior teeth (11,21,22), restoration of mandibular posteriors (37,45,46,47) followed by two fixed partial dentures in maxillary arch, single crowns of maxillary anteriors and finally a cast partial denture of mandibular arch (Figure 2B). One of the maxillary anterior tooth had persistent infection after performing disinfection of the root canal. The tooth was treated as per recommended protocol of teeth that show persistent infection without the need of surgical intervention [18]. The patient was provided with option of metal ceramic restorations only since both cast partial dentures had to be supported on the occlusal surfaces for which base metal alloys is the material of choice. The treatment was initiated by correcting the incisal plane of maxillary arch utilizing enameloplasty (Figure 3A). After routine clinical and laboratory procedures for fixed partial denture the metal ceramic crowns were cemented with zinc phosphate cement in maxillary teeth including the surveyed crowns of the three unit bridges (Figure 3B). Once individual crowns and bridges were cemented, the framework for cast partial denture was tried in the patients mouth (Figure 3C) to make sure that occlusal rests fit into their respective seats withing the underlying fixed partial dentures. Once denture base was processed to the framework, the insertion of maxillary and mandibular cast partial dentures completed the overall treatment (Figure 3D). Post operatively the fit of both fixed partial dentures and cast partial dentures was verified using orthopantomographs (Figure 4 A, B). The overall fit of the cast partial denture was achieved to be that of passive one in both maxillary and mandibular arches. Active fit is prone to create wedging stresses on the abutment tooth endangering their periodontal health [19].

The patient was recalled for each specialty treatment as per the recommended protocols. For prosthodontic recall following treatment completion, the patient was recalled initially after 7 days, 1 month, 3 months and yearly. On one year follow up, the patients fixed partial denture health was confirmed by removing the cast partial denture and taking intra oral periapical radiographs (Figure 5). The periodontal health of all teth was considered to be

healthy except one tooth where lateral forces had caused widening of lamina dura and was corrected through occlusal correction. The patient was overall totally satisfied with the outcome of the entire occlusal rehabilitation especially the maxillary arch.



**Figure 4.** (A) Orthopantomograph after cementing fixed partial denture in maxillary arch in place (B) Orthopantomograph after placing both mandibular and maxillary cast partial dentures



**Figure 5.** One year follow up intra oral peri apical radiographs showing well accepted prosthodontic rehabilitation

### 3. Discussion

A clinical case report of an adult female who had neglected her dental health and had a very high DMF (decayed, missing, filled) index but was successfully restored with a blend of preprosthetic (extraction, crown lengthening, endodontic treatment, restorations) and prosthodontic (fixed partial and removable partial) treatment options. The unique feature of this case report is the emphasis on the presence of so many malpositioned teeth that had resulted mainly due to neglect and their respective influence on the final outcome of the entire treatment. Malpositioned teeth are conservatively corrected by orthodontic treatment which requires a long time to complete [20]. The outcome of the present treatment could have been better if the patient would have agreed for the orthodontic correction. Orthodontic referral was taken from the concerned department which presented the patient with a choice of waiting time for more than 5 years due to which the patient mainly refused orthodontic intervention. Patients economical condition did not permit her to seek such treatment in the private sector, therefore the treatment planning had to accommodate these factors

and a non orthodontic rehabilitation was designed for the patient. Orthodontic correction of a natural tooth does not result in sacrificing crown root ratio [21], which is one of its biggest advantage in terms of maintaining pericemental area of the tooth which in turn are important factors for prosthodontic treatment options. MT have direct influence on temporomandibular joint by altering mandibular movement patterns and may even result a normal functional movement to change into a parafunctional movement. An example of such was observed in this case who had maxillary left canine in a cross bite relationship. This resulted in anterior guidance not being functional on one side and thus altering the influence of teeth on the movement of the mandible. The mandible would get locked by the canine when moved in the opposite side and thereby influencing the muscles that move the condyles. MP teeth thus can contribute to the development of temporomandibular joint disorders if they interfere in normal functioning of the mandible especially functional movements which are frequently performed like during mastication [22,23]. Another significant finding that was observed in the occlusion of this patient was reduced overjet, which also does not allow proper functioning of mandibular protrusion. Although decreased overjet produced immediate disclusion of posterior teeth, they also restrict the freedom from centric thereby impairing occlusion in the long term. On the contrary excessive overjet has been shown to impair phonetics (labial related sounds) while at the same time resulting in more chances of creating posterior interferences [24]. One of the significant yet unrecognized aspects of treatment presented in this case was the correction of incisal guidance through the use of enameloplasty. Although the cross bite canine limited retrusion movements, it was observed upon protrusion that only one central incisor was in contact with opposing tooth and this was due to supraeruption of that tooth. So correction of incisal plane was considered necessary to bring the effects of anterior guidance in protecting the posterior occlusion [25]. In occlusal rehabilitations, authors have stated the natural tooth structure must be removed in cases where normal and proper occlusal function has a chance [26].

Metal occlusals were selected for all the fixed partial dentures except single crowns in the maxillary anterior region. These were considered since the cast partial denture components had to be in contact with the fixed partial denture. These components included the minor connectors, occlusal rests, indirect retainer rests and proximal plates. Since removable partial denture is prone to micromovement within the mouth, small movements can lead to fracture of ceramic on the fixed partial denture which would have then created a post operative complication [27]. Dental ceramic being brittle in nature is bound to fracture when forces are in tensile rather than in compression. Biocompatibility of material largely is influenced by its composition and interaction in oral cavity [28]. The metal used was base metal alloy which is considered to be biocompatible. However, one must note that in case when one uses a combination of fixed partial and cast partial denture, the two base metal alloys used in either of them differs with nickel based alloys used for fixed partial denture and cobalt based alloys for cast partial denture [29]. Metal ceramic restorations are

generally successful in such cases since they fulfill successfully the biological and mechanical concerns without compromising esthetic fulfilments [30]. It must also be noted that interaction between different metals must be considered and patients reaction to the components of the alloys should be noted. In cases where cast partial dentures are supported by fixed partial dentures the choice of selecting intra versus extra coronal attachment as a retainer depends on overall design considerations and the abutment tooth morphology [31]. A healthy periodontium that is free from inflammatory components and microbes that cause such reactions is the basis of successful prosthetic treatments irrespective of the material/ technique or design. Teeth that have underlying periodontal inflammation respond unfavorably to even mild stress [32].

## 4. Conclusion

MT do influence the designing of simple to complex occlusal rehabilitations while influencing the outcome of treatment employed. Orthodontic correction of malpositioned teeth needs to be delivered in quick time so that patients will benefit from such pre prosthetic treatments. Whenever included in treatment plan, certain MT may change the case from simple to complex because of their difficulty to be accommodated in line with other remaining natural teeth.

## ACKNOWLEDGEMENT

The authors would like to thank the staff of the production laboratory and staff of other departments for extending their kind cooperation during the course of treatment of this case.

## Conflict of Interest

None

## References

- [1] Bello FC. Malocclusão e o serviço público: um estudo em Belo Horizonte [monografia]. Belo Horizonte (MG): Universidade Federal de Minas Gerais; 2004.
- [2] Gusmão ES, Queiroz RD, Coelho RD, et al. Association between malpositioned teeth and periodontal disease. *Dental Press Journal Of Orthodontics*. 2011; 16: 87-94.
- [3] Al-Ani AH, Antoun JS, Thomson WM, et al. Hypodontia: an update on its etiology, classification, and clinical management. *BioMed Research International*. 2017; 9378325.
- [4] Darraj A, Mattoo KA. Full Mouth Rehabilitation Involving Occlusal Plane Correction-Case Report. *JMSCR* 2017; 5(9): 28204-208.
- [5] Alsulaimani L, Alqami H, Akel M, et al. The orthodontics-periodontics challenges in integrated treatment: a comprehensive review. *Cureus*. 2023; 15(5).
- [6] Bernhardt O, Krey KF, Daboul A, et al. New insights in the link between malocclusion and periodontal disease. *Journal of clinical periodontology*. 2019; 46(2): 144-59.
- [7] Mattoo KA, Kumar L, Sarvar S. Full mouth rehabilitation in an occupationally stressed bureaucrat. *JMSCR* 2019; 7(10): 536-540.
- [8] Feng X, Oba T, Oba Y, Moriyama K. An interdisciplinary approach for improved functional and esthetic results in a

- periodontally compromised adult patient. *Angle Orthod.* 2005; 25(6): 1061-70.
- [9] Yadav L, Mattoo KA, Kapoor A, Shuja S. Factors associated with post core correction of malpositioned teeth. *International Journal of Research in Medical Sciences and Technology* 2015; 1(2): 5-7.
- [10] Mattoo K, Rathi N, Goswami R. Differences in mental attitude towards extensive dental treatments between two siblings suffering from Amelogenesis Imperfecta –Two case reports and literature review. *International Journal of Dental Sciences and Research* 2014; 2(6): 123-127.
- [11] Seibert JS, Cohen DW. Periodontal considerations in preparation for fixed and removable prosthodontics. *Dental Clinics of North America.* 1987; 31(3): 529-55.
- [12] Ephros H, Klein R, Sallustio A. Preprosthetic surgery. *Oral and Maxillofacial Surgery Clinics.* 2015; 27(3): 459-72.
- [13] Darraj A, Mattoo KA, Nazish M. Scheduling multiple surgical procedures in immunocompromised rheumatoid patient on immune suppressant regimen. *JMSCR* 2017; 5 (08): 26828-833.
- [14] Durbin DS, Sadowsky C. Changes in tooth contacts following orthodontic treatment. *American Journal Of Orthodontics And Dentofacial Orthopedics.* 1986; 90(5): 375-82.
- [15] Turbill EA, Richmond S, Wright JL. The time - factor in orthodontics: What influences the duration of treatments in National Health Service practices?. *Community dentistry and oral epidemiology.* 2001; 29(1): 62-72.
- [16] Sivach A, Mattoo K. Simplifying designing of a cast partial denture in Kennedy class I partial edentulous situation to enhance its self-cleansing ability. *WebmedCentral Dentistry* 2014; 5(9): WMC004708.
- [17] Rathi N, Mattoo K, Goswami R. Synchronizing a multi-disciplinary team to rehabilitate an aesthetically handicapped patient suffering from developmental abnormality of amelogenesis imperfecta. *WebmedCentral Rehabilitation* 2014; 5(9): WMC004690.
- [18] Alghamdi NS, Alamoudi RA, Baba SM, et al. A Scanning Electron Microscopy Study Comparing 3 Obturation Techniques to Seal Dentin to Root Canal Bioceramic Sealer in 30 Freshly Extracted Mandibular Second Premolars. *Medical Science Monitor.* 2023; 29: e940599-1.
- [19] Mattoo KA, Kumar S. Multiple post core crowns – A clinical report. *Clinical Dentistry* 2011; 5: 31-34.
- [20] Kokich V. Esthetics and anterior tooth position: an orthodontic perspective Part II: Vertical position. *Journal of Esthetic and Restorative Dentistry.* 1993; 5(4): 174-8.
- [21] Avila G, Galindo - Moreno P, Soehren S, et al. A novel decision - making process for tooth retention or extraction. *Journal of periodontology.* 2009; 80(3): 476-91.
- [22] Darraj A, Mattoo KA, Gupta I. Full mouth rehabilitation of a rheumatoid arthritis patient – The Muzyanas Challenge. *Annals of International Medical and Dental Research* 2017; 3(6): DE09-DE13.
- [23] Hollender LG, Truelove EL. Relationship between orthodontic treatment, condylar position, and internal derangement in the temporomandibular joint. *American Journal of Orthodontics and Dentofacial Orthopedics.* 1992 ;101(1): 48-53.
- [24] Gohal MRA, Mattoo KA, Nazish A, et al. Corrective Prosthodontics – Curating Semi Functional Anterior Guidance in Full Mouth Rehabilitation: Case Report. *JMSCR* 2017; 5(08): 26777-781.
- [25] Anyanechi CE, Saheeb BD. Retrospective analysis of malpositioned mandibular third molars in elderly patients. *Iraqi Dental Journal.* 2019; 41(2): 1-7.
- [26] Lakshya K, Aditya K, et al. Full mouth rehabilitation involving multiple cast post core as foundation restorations – Case report. *International Journal of Medical Research and Pharmaceutical Sciences* 2018; 5(7): 11-15.
- [27] Rosentritt M, Behr M, Gebhard R, Handel G. Influence of stress simulation parameters on the fracture strength of all-ceramic fixed-partial dentures. *Dental Materials.* 2006; 22(2): 176-82.
- [28] Mattoo KA, Garg R, Gupta A, Jain N. Toxicology and biocompatibility of dental materials: A review. *Res J Pharm Biol Chem Sci,* 2012; 3(4): 1091-99.
- [29] Jei JB, Mohan J. Comparative evaluation of marginal accuracy of a cast fixed partial denture compared to soldered fixed partial denture made of two different base metal alloys and casting techniques: an in vitro study. *The Journal of Indian Prosthodontic Society.* 2014; 14: 104-9.
- [30] Mattoo KA, Sarvar S. Full mouth rehabilitation comprising metal collar restorations - case report. *International Journal of Medical Research and Pharmaceutical Sciences* 2017; 4(9): 43-47.
- [31] Mattoo K, Singh M, Singh SP. Precision retained partial denture - A proxy treatment option for full mouth rehabilitation. *Medico Research Chronicles* 2014; 1(2): 144-149.
- [32] Abullais SS, Patel SI, Asiri EA, et al. Comparative Evaluation of 3 Commercial Mouthwash Formulations on Clinical Parameters of Chronic Gingivitis. *Medical Science Monitor.* 2022; 28.

