

# Rare Case of Secondary Evans Syndrome in Setting of Triple Positive Anti-Phospholipid Antibodies

Anahat Kaur MD<sup>1</sup>, Bhanujit Dwivedi MBBS<sup>2,\*</sup>, Tejasvi Dwivedi MBBS<sup>3</sup>, Rubina Sharma MD<sup>4</sup>, Angad Singh MD<sup>5</sup>

<sup>1</sup>Department of Hematology and Oncology, Albert Einstein College of Medicine, Jacobi Medical Center, Bronx, NY, USA

<sup>2</sup>Maulana Azad Medical College, New Delhi, India

<sup>3</sup>All India Institute of Medical Sciences, Raipur, India

<sup>4</sup>PGIMER, Chandigarh, India

<sup>5</sup>HCA Midwest Healthcare, Kansas City, KS, USA

\*Corresponding author: [bhanujit.dwivedi@gmail.com](mailto:bhanujit.dwivedi@gmail.com)

Received June 26, 2023; Revised July 28, 2023; Accepted August 04, 2023

**Abstract** Evans syndrome is a rare autoimmune disorder characterized by the simultaneous or sequential presence of autoimmune hemolytic anemia (AIHA) and immune thrombocytopenia (ITP). Secondary Evans syndrome refers to cases in which these autoimmune manifestations occur in the setting of an underlying condition or trigger. We report the case of a 36 year old male with no significant past medical history who presented with symptoms of easy bruising, and mucocutaneous bleeding. Laboratory investigations revealed severe thrombocytopenia and hemolytic anemia, consistent with the diagnosis of Evans syndrome. Further evaluation demonstrated the presence of triple positive anti-phospholipid antibodies, including lupus anticoagulant, anticardiolipin antibodies, and anti-beta-2 glycoprotein antibodies. Patient was initially treated with steroids and IVIG but had refractory ITP for several weeks requiring rituximab (four weekly doses) and fostamatinib before eventual improvement and stabilization of platelet count. Given the rarity of secondary Evans syndrome with positive anti-phospholipid antibodies, there is a lack of robust evidence-based treatment guidelines. Our case highlights the complexity and challenges encountered in managing this condition.

**Keywords:** Secondary Evans, Anti-phospholipid antibodies, Refractory ITP

**Cite This Article:** Anahat Kaur MD, Bhanujit Dwivedi MBBS, Tejasvi Dwivedi MBBS, Rubina Sharma MD, and Angad Singh MD, "Rare Case of Secondary Evans Syndrome in Setting of Triple Positive Anti-Phospholipid Antibodies." American Journal of Medical Case Reports, vol. 11, no. 7 (2023): 123-125. doi: 10.12691/ajmcr-11-7-3

## 1. Introduction

Evans syndrome is an autoimmune disorder involving presence of two or more immune mediated cytopenias, either simultaneously, or one after another. The most frequent combination is that of Autoimmune haemolytic anaemia (AIHA) and Immune thrombocytopenia (ITP). Autoimmune neutropenia is the third most common component.

Evans syndrome may be incited by an underlying disease process in which case it is termed secondary Evans. The precipitating factors include viral infections like HIV, CMV, HCV, COVID-19 etc; drug reactions, other Autoimmune diseases, immunodeficiencies and lymphoproliferative disorders. The remaining cases without a clear trigger are known as idiopathic/ Primary Evans Syndrome.

Compared to isolated AIHA, Evans syndrome is more difficult to manage, with higher rate of relapse after treatment and higher mortality.

Here, we present a case report of secondary Evans

syndrome in a patient with triple positive anti-phospholipid antibodies, highlighting the complexity and challenges in managing this condition.

## 2. Case Presentation

We report the case of a 36 year old male with no significant past medical history who was initially admitted with one month of spontaneous bruising, bleeding and severe thrombocytopenia (platelet count 1000/mcL). Patient was also noted to have mild anemia ( Hg ~ 10 gm/dl) with normal white blood cell count and differential. Peripheral blood smear review did not show any schistocytes but was significant for obvious spherocytes. Direct antiglobulin test was positive for IgG (pan agglutinin), absolute reticulocyte count was elevated at  $118 \times 10^9/L$  and LDH was high at 274 U/L. Patient was given the working diagnosis of Evans Syndrome with combination of Immune Thrombocytopenia (ITP) and Auto-Immune Hemolytic Anemia (AIHA). On further testing, he was surprisingly noted to have elevated activated partial thromboplastin time (43.2 seconds) with

normal PT/INR (prothrombin time/International Normalized ratio) and strongly positive antiphospholipid antibodies: Anticardiolipin IgG (moderately elevated titer of 54.2) and Anti-beta-2 glycoprotein IgG (elevated titer 88.8). The Diluted Russell viper venom time (DRVVT) test and Silica clotting time test are used for detection of Lupus anticoagulant; both yielded a positive result in our patient. Patient denied any prior history of thrombosis. Based on these lab results, the patient was diagnosed with Evans syndrome which was felt to be secondary to anti-phospholipid antibodies.

During the hospital admission, the patient received platelet transfusion, two doses of IVIG and was started on steroids with improvement in platelet count to 30,000/mcL after five days. He was discharged on prednisone 100 mg daily and was also started on weekly rituximab 375 mg/m<sup>2</sup> IV for four doses in the outpatient setting due to concern for inadequate platelet response. After the second dose of rituximab, he was readmitted with refractory ITP (platelets 3000/mcL). IVIG was re-dosed with improvement in platelets to 80,000/mcL and steroid taper was started due to established steroid refractoriness. After completion of four weekly doses of rituximab, the patient's platelet count remained stable for a few weeks but then started to trend down again. The

patient was not interested in undergoing surgical intervention for splenectomy. Decision was made to hold off on thrombopoietin (TPO) agonist therapy due to increased risk of thrombosis in a patient with ITP and suspected anti-phospholipid syndrome (APS). A bone marrow biopsy was performed which ruled out acute leukemia, high-grade myelodysplasia or carcinoma. Flow cytometry revealed 0.3% monotypic B-cells (positive for kappa, CD19; negative CD20, CD10, CD5) with unclear clinical significance. He was started on fostamatinib for relapsed steroid refractory ITP. He received this medication for a short duration of 10 days, at which point a repeat lab check noted improvement in platelet count to 168,000/mcL. This improvement was felt to be most likely secondary to previous treatment with rituximab and ongoing low dose prednisone. Although the patient received several days for fostamatinib, it is less likely that brief exposure would have translated into a significant improvement in the platelet count. Fostamatinib was subsequently discontinued and the patient's platelet count remained >30,000/mcL even after completion of steroid taper. Evidence of hemolysis was not noted on any labs done after the patient's initial hospital admission.

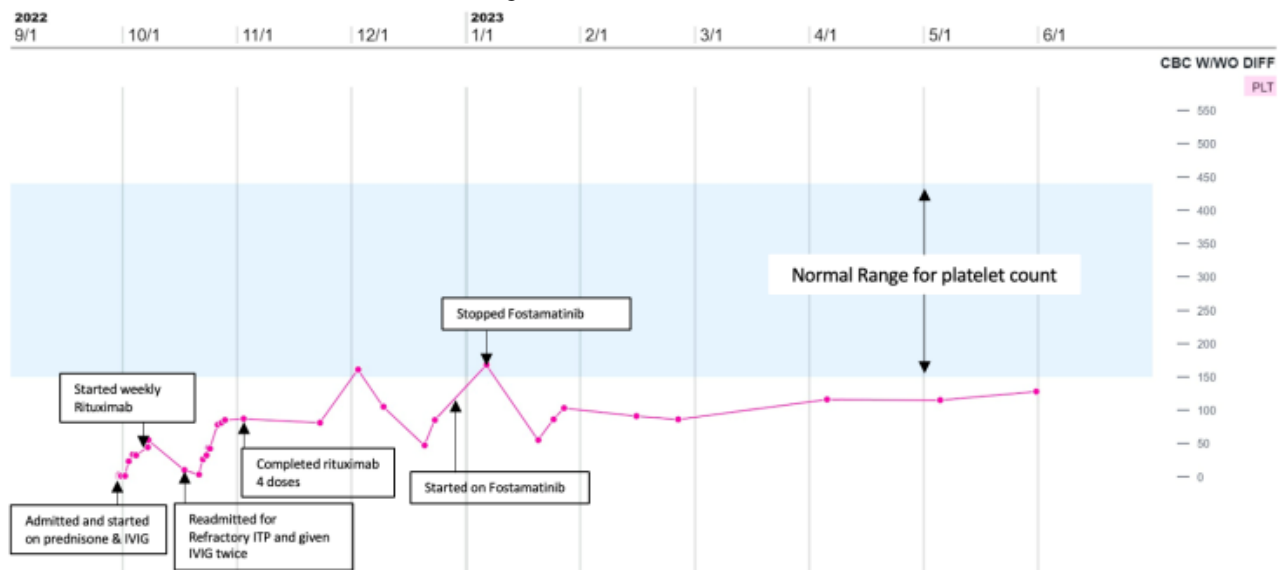


Figure 1. Platelet count trend throughout patient’s clinical course

	Lab value at time of initial diagnosis	Lab value at five month follow up
Hemoglobin	10 gm/dl	14 gm/dl
White blood cell	8,800/mcl	7,400/mcl
Platelets	1,000/mcl	86,000/mcl
Absolute reticulocyte count	118 x 10 <sup>9</sup> /L	80 x 10 <sup>9</sup> /L
Lactate dehydrogenase	274 U/L	199 U/L

Table 1. Comparison of patient’s lab values at time of diagnosis and at five month follow up

### 3. Discussion

In our case, the patient presented with symptoms of easy bruising, and mucocutaneous bleeding. Laboratory investigations revealed hemolytic anemia and thrombocytopenia, consistent with the diagnosis of Evans syndrome. Further evaluation demonstrated the presence of triple positive anti-phospholipid antibodies, including lupus anticoagulant, anticardiolipin antibodies, and anti beta-2 glycoprotein antibodies. This combination of findings suggested the presence of secondary Evans syndrome with possible underlying APS.

Anti-phospholipid syndrome (APS) is an autoimmune disorder characterized by the presence of anti-phospholipid antibodies, such as lupus anticoagulant, anticardiolipin antibodies, and anti-beta-2 glycoprotein antibodies [1]. APS is known to cause thrombotic events and can lead to complications during pregnancy. However, the association between APS and the development of Evans syndrome is rare and poorly understood.

The pathogenesis of secondary Evans syndrome in the context of APS is thought to involve a complex interplay between immune dysregulation, antibody-mediated destruction of red blood cells and platelets, and thrombotic events. The exact mechanisms underlying the development of Evans syndrome in APS are not well elucidated, and further research is needed to understand this association [2].

Management of secondary Evans syndrome with triple positive anti-phospholipid antibodies requires a multidisciplinary approach. Treatment strategies often involve a combination of immunosuppressive agents, such as corticosteroids, rituximab, and splenectomy if pharmacologic treatment is unsuccessful [3].

One of the options for treatment of refractory ITP is mycophenolate which has also been used in patients with autoimmune hemolytic anemia. In the article by Al-Samkari and Kuter, the authors noted a response rate of 40 to 50% and good durability [4]. Other potential medical therapies include azathioprine, cyclophosphamide, cyclosporine and danazol [4].

Fostamatinib is also approved for treatment of relapsed/refractory ITP. It works as an inhibitor of the spleen tyrosine kinase. In murine models of ITP and AIHA, pretreatment with fostamatinib prevented the development of thrombocytopenia and anemia. Importantly, fostamatinib has also been shown to inhibit platelet activation while not affecting hemostasis specific signaling i.e. platelet aggregation [5].

However, the optimal treatment regimen for secondary Evans syndrome in the setting of positive anti-phospholipid antibodies remains uncertain due to the limited number of reported cases and lack of standardized guidelines [6].

The management of thrombotic events in APS-related

Evans syndrome is particularly challenging, as the use of immunosuppressive agents and thrombopoietin (TPO) agonists can potentially exacerbate the prothrombotic state. Balancing the need for immunosuppression to control the autoimmune manifestations and requirement of TPO agonists to prevent spontaneous life-threatening hemorrhage while minimizing the risk of thrombosis requires careful consideration and individualized treatment plans [7].

Given the rarity of secondary Evans syndrome with triple positive anti-phospholipid antibodies, there is a lack of robust evidence-based guidelines for its management. Case reports and small case series serve as important sources of information to guide clinical decision-making in such scenarios. Collaborative efforts and sharing of clinical experiences are crucial to further our understanding of this rare condition and to develop more effective treatment strategies.

In conclusion, we present a case of secondary Evans syndrome in a patient with triple positive anti-phospholipid antibodies. The association between APS and the development of Evans syndrome is rare and poorly understood. The complex interplay between immune dysregulation, antibody-mediated destruction of red blood cells and platelets, and thrombotic events in APS likely contributes to the pathogenesis of secondary Evans syndrome. Further research is warranted to better understand the underlying mechanisms and to establish evidence-based treatment guidelines for this challenging condition.

### References

- [1] Giannakopoulos B, Krilis SA. The pathogenesis of the antiphospholipid syndrome. *N Engl J Med.* 2013;368(11):1033-1044.
- [2] Cervera R, Piette JC, Font J, et al. Antiphospholipid syndrome: clinical and immunologic manifestations and patterns of disease expression in a cohort of 1,000 patients. *Arthritis Rheum.* 2002;46(4):1019-1027.
- [3] Patel BP, Jakob J. A Rare Case of Simultaneous Evans Syndrome and Primary Antiphospholipid Syndrome. *Cureus.* 2020 Feb 1;12(2):e6845.
- [4] Al-Samkari H, Kuter DJ. Immune Thrombocytopenia in Adults: Modern Approaches to Diagnosis and Treatment. *Semin Thromb Hemost.* 2020 Apr;46(3):275-288.
- [5] Cooper N, Ghanima W, Hill QA, Nicolson PL, Markovtsov V, Kessler C. Recent advances in understanding spleen tyrosine kinase (SYK) in human biology and disease, with a focus on fostamatinib. *Platelets.* 2023 Dec;34(1):2131751.
- [6] Provan D, Stasi R, Newland AC, et al. International consensus report on the investigation and management of primary immune thrombocytopenia. *Blood.* 2010;115(2):168-186.
- [7] Fattizzo B, Cecchi N, Bortolotti M, Giordano G, Patriarca A, Glenthøj A, Cantoni S, Capecci M, Chen F, Mingot-Castellano ME, Napolitano M, Frederiksen H, González-Lopez TJ, Barcellini W. Thrombopoietin receptor agonists in adult Evans syndrome: an international multicenter experience. *Blood.* 2022 Aug 18;140(7):789-792.

