

# Importance of a Total Body Skin Examination by Exposing a Patient for the Diagnosis of Tick-mediated Infectious Disease

Youichi Yanagawa\*, Ken-ichi Muramatsu, Yoichiro Maekawa, Soichiro Ota, Ikuto Takeuchi

Department of Acute Critical Care Medicine, Shizuoka Hospital, Juntendo University

\*Corresponding author: [yyanaga@juntendo.ac.jp](mailto:yyanaga@juntendo.ac.jp)

Received November 21, 2022; Revised January 02, 2023; Accepted January 12, 2023

**Abstract** An 81-year-old man was found unconscious in a bathtub by his wife after having taken a long bath. He was rescued by his wife and son, and they dressed him while calling for an ambulance. On arrival, he was in a shock state with convulsion. After exposing him, he was found to have multiple macular skin rashes with eschar with a red halo on his lower right abdomen. He was treated with anticonvulsant and massive infusion. He had had right lower abdominal skin lesions for more than two weeks, general fatigue and skin rash for one week, and a fever for four days before the arrival. A biochemical analysis of his blood on arrival indicated inflammation, hepatic, renal disturbance, and coagulopathy. As he had the triad of tick-mediated infectious diseases, he received minocycline. His general condition improved, and he regained his consciousness on day 6. On day 9, we obtained positive results for scrub typhus. Finally, he was discharged home. Physicians should perform a full body skin examination of patients with a coma or fever in order not to miss fatal diseases.

**Keywords:** scrub typhus, full body skin examination, eschar with red halo

**Cite This Article:** Youichi Yanagawa, Ken-ichi Muramatsu, Yoichiro Maekawa, Soichiro Ota, and Ikuto Takeuchi, "Importance of a Total Body Skin Examination by Exposing a Patient for the Diagnosis of Tick-mediated Infectious Disease." *American Journal of Medical Case Reports*, vol. 11, no. 1 (2023): 10-13. doi: 10.12691/ajmcr-11-1-3.

## 1. Introduction

A full body skin examination (FBSE) is routinely performed by a trained healthcare professional to search for any unusual or suspicious lesions or conditions on the skin surface in patients with trauma, burn, or a high risk of skin cancer. [1-4] Internal diseases can also manifest as a myriad of skin dermatoses, ranging from single disorders, such as calciphylaxis, cryoglobulinemia, amyopathic dermatomyositis, and Raynaud phenomenon, to spectrum disorders, such as neutrophilic dermatoses and morphea. [5,6,7] Often, the skin manifestations of systemic disease are vague and nonspecific. Systemic manifestations can also be vague and nonspecific, such as the toxic erythema, which might follow a viral infection or drug eruption, although some skin manifestations are highly specific and define the illness, such as smallpox, varicella, measles, rubella, and Reiter disease. [8]

Ticks are blood-sucking arthropods that attach to the skin through oral devices, causing diverse initial cutaneous manifestations, and may also transmit serious infectious diseases, such as Japanese spotted fever, scrub typhus (ST), or severe fever with thrombocytopenia syndrome in Japan.<sup>9</sup> ST, also known as tsutsugamushi disease, was initially endemic to the Asia-Pacific region

but has now spread worldwide due to globalization, with 1 million cases reported each year. [10] The causative pathogen is *Orientia tsutsugamushi*, a Gram-negative obligate intracellular rickettsial bacterium that is transmitted to warm-blooded animals by bites of *Leptotrombidium* mite larvae (chiggers). [10] ST is initially characterized by an eschar with a red halo lacking subjective symptoms as the primary lesion, which may appear two to three days before the sudden onset of flu-like symptoms, such as a fever with chills, headache, backache, myalgia, profuse sweating, vomiting, and enlarged lymph nodes. [11] A macular or maculopapular skin rash as the secondary lesions can develop within three to eight days after the onset of the fever. ST can still be easily misdiagnosed, however, and without accurate and timely antibiotic treatment, fatality can reach 30%.<sup>10</sup> Thus, a rapid and accurate diagnostic method is vital to tackle the ST epidemic.

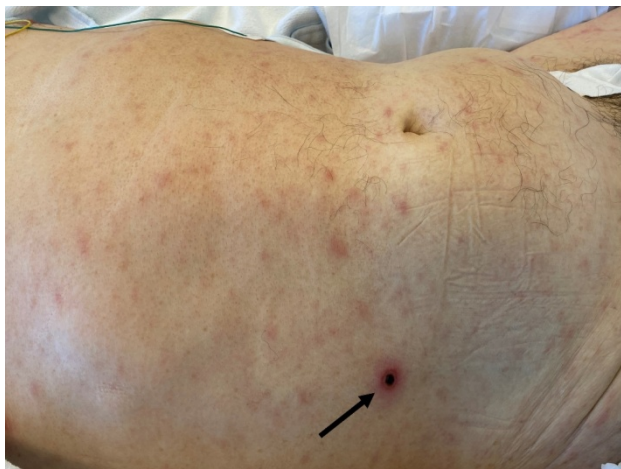We herein report a successful case of treating ST following an initial ocular inspection using a FBSE, even though the case was misdiagnosed as one of near drowning.

## 2. Case Report

An 81-year-old healthy Japanese man, who lived in Eastern Shizuoka, Japan, was found unconscious in a

bath tub by his wife after having taken a long bath. He was rescued by his wife and son, and they dressed him while calling for an ambulance. When emergency medical technicians checked him, he was in a deep coma state with shock. The initial report to our hospital for the accommodation request described an unconscious male patient with drowning.

During the 60 minutes of transportation, he showed generalized convulsion, and on arrival, he continued to show convulsion. After exposing him, he was found to have multiple macular skin rashes with eschar with a red halo on his lower right abdomen (Figure 1). His blood pressure and percutaneous saturated oxygen were unmeasurable, and his heart rate was 140 beats per minute. He was treated with anticonvulsant and massive infusion after securing a venous route.



**Figure 1.** A full body skin examination performed on arrival (After exposing the patient, he was found to have multiple macular skin rashes with an eschar with a red halo in his lower right abdomen (arrow))

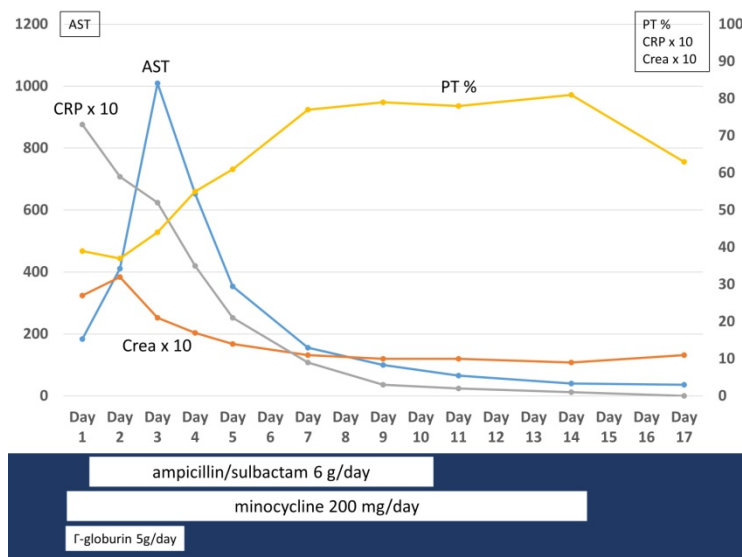
The results of a venous blood gas analysis were as follows: pH, 7.32; PCO<sub>2</sub>, 43 mmHg; PO<sub>2</sub>, 17 mmHg; HCO<sub>3</sub><sup>-</sup>, 21 mmol/L; base excess, -3.6 mmol/L; lactate, 5.6, mmol/L. An electrocardiogram and cardiac echo study were negative. After the arrival of his family, we obtained his history. He had hypertension. In addition, he

had had right lower abdominal skin lesions without subjective symptoms, resulting in him not bothering to check with a doctor, for over two weeks before his arrival at our hospital. He had also had general fatigue and a skin rash for one week before the arrival. He had visited a local near hospital due to a fever four days before the arrival, where he underwent a polymerase chain reaction (PCR) examination for COVID-19, but the result was negative. His skin was not checked there. His hobby was going for walks, and he often entered grassy areas. According conferring with his family, they informed us that the patient did not wish to receive lifesaving treatment. Accordingly, we did not perform these measures.

Whole-body computed tomography showed swelling of the mediastinal lymph nodes and mild-grade consolidation in the bilateral dorsal lungs. The results of a biochemical analysis of the blood on arrival are shown in Table 1.

**Table 1.**

Examination item	Level	unit
Total protein	6.6	g/dL
Albumin	2.4	g/dL
Total bilirubin	0.7	mg/dL
Aspartate aminotransferase	184	IU/L
Alanine aminotransferase	92	IU/L
Creatine kinase	277	IU/L
Blood urea nitrogen	49.8	mg/dL
Creatinine	2.73	mg/dL
Sodium	130	mEq/L
Potassium	5.6	mEq/L
Uric acid	11.5	mg/dL
Brain natriuretic peptide	145.3	pg/mL
C reactive protein	7.37	mg/dL
White blood cell count	6,200	/μL
Neutrophil	74	%
Lymphocyte	20	%
Hemoglobin	11.9	g/dL
Platelets	17	× 10 <sup>4</sup> /μL
Prothrombin time-international normalized ratio	1.73	
Activated partial thromboplastin time	47.4	Second
Fibrinogen	228	mg/dL
Fibrin degradation product	30.2	μg/mL



**Figure 2.** Time course of the treatment and the main results of the biochemical analysis of blood. C His respiration, circulation, renal function, and coagulopathy improved after our treatments. His liver function temporarily deteriorated but then also improved

In brief, these findings indicated inflammation, hepatic and renal disturbance, and coagulopathy.

As he had the triad of tick-mediated infectious diseases after the initial FBSE, he received minocycline and  $\gamma$ -globulin, followed by ampicillin/sulbactam for suspicious aspiration and noradrenalin and hydrocortisone for septic shock. On day 2, his skin rash and eschar as well as blood samples were provided to a public health center to check for tick-mediated infectious diseases.

The time course of treatment and main results of the biochemical analysis of the blood after admission are shown in [Figure 2](#).

His respiration, circulation, renal function, and coagulopathy improved after these treatments. His liver function temporarily deteriorated but then also improved. Head magnetic resonance imaging on day 4 for the evaluation of his prolonged unconscious state showed findings suggestive of several septic thromboses in his brain. On day 6, he regained consciousness and could stand near his bedside with assistance. On day 9, the public health center reported positive results for ST by PCR. After rehabilitation, he was discharged home with minor recent memory disturbance.

### 3. Discussion

The present study demonstrates the usefulness of an FBSE for diagnosing tick-mediated infectious diseases and the survival outcome with early appropriate treatments, even in the present case, which had an acute physiology and chronic health evaluation II score of 34 points and a mortality risk of 73%. [12] The early diagnosis and treatment are essential for managing fatal tick-mediated infectious diseases. Important diagnostic clues of a specific skin lesion (eschar with a red halo) might be found at the head, back, axillar, or inguinal areas, so an FBSE is recommended by The Japanese Association for Infectious Diseases (<https://www.kansensho.or.jp/ref/d41.html>).

Aside from ST, skin lesions can be an important clue for determining the cause of fatal internal diseases, infectious diseases, or indirect signs of septicemia, including specific skin lesions that can be clues to the clinical diagnosis of internal diseases [13,14]; specific skin lesion that can be clues to the clinical diagnosis of infectious virus diseases [15,16]; skin lesions itself as the main focus of fatal infectious disease [17]; signs of disseminated intravascular coagulation and coagulopathy [18]; signs of direct vascular invasion and occlusion by bacteria or fungi [19,20]; signs of immune vasculitis and immune complex formation due to a medication, infection, malignancy, underlying inflammatory disease, or primary systemic vasculitis [20]; signs of emboli from endocarditis [20]; and signs of the effects of toxins [21]. To diagnose a disease correctly, not only a visual inspection of the skin lesions but also a histological analysis and a biochemical analysis (including PCR and/or culture) may be required, similar to the present case.

Complaining of skin lesions is common among patients who visit an emergency room [22]. However, a misdiagnosis or overlooking important cutaneous manifestations due to a fatal internal disease can result in a fatal outcome. [14] Accordingly, physicians should

perform an FBSE when treating patients with a fever or coma, similar to the present case.

### 4. Conclusion

The present study demonstrated the usefulness of an FBSE for diagnosing fatal tick-mediated infectious diseases. Physician should perform an FBSE for patients with a coma or fever in order not to miss fatal diseases.

### Acknowledgements

This work was supported in part by a Grant-in-Aid for Special Research in Subsidies for ordinary expenses of private schools from The Promotion and Mutual Aid Corporation for Private Schools of Japan.

### References

- [1] Kelleher DC, Waterhouse LJ, Parsons SE, Fritzeen JL, Burd RS, Carter EA. Factors associated with patient exposure and environmental control during pediatric trauma resuscitation. *J Trauma Acute Care Surg.* 2013 Feb; 74(2): 622-7.
- [2] Tran DP, Arnold DH, Thompson CM, Richmond NJ, Gondek S, Kidd RS. Evaluating Discrepancies in Percent Total Body Surface Area Burn Assessments Between Prehospital Providers and Burn Center Physicians. *J Burn Care Res.* 2022 Jan 5; 43(1): 225-231.
- [3] Hoorens I, Vossaert K, Pil L, Boone B, De Schepper S, Ongenaet K, Annemans L, Chevolet I, Brochez L. Total-Body Examination vs Lesion-Directed Skin Cancer Screening. *JAMA Dermatol.* 2016 Jan; 152(1): 27-34.
- [4] Bajaj S, Wolner ZJ, Dusza SW, Braun RP, Marghoob AA, DeFazio J. Total Body Skin Examination Practices: A Survey Study Amongst Dermatologists at High-Risk Skin Cancer Clinics. *Dermatol Pract Concept.* 2019 Apr 30; 9(2): 132-138.
- [5] Franks AG Jr. Skin manifestations of internal disease. *Review Med Clin North Am.* 2009 Nov; 93(6): 1265-82.
- [6] Lee A. Skin manifestations of systemic disease. *Aust Fam Physician.* 2009 Jul; 38(7): 498-505.
- [7] Leal JM, de Souza GH, Marsillac PF, Gripp AC. Skin manifestations associated with systemic diseases - Part II. *An Bras Dermatol.* 2021 Nov-Dec; 96(6): 672-687.
- [8] Cahill J, Sinclair R. Cutaneous manifestations of systemic disease. *Aust Fam Physician.* 2005 May; 34(5): 335-40.
- [9] Haddad V Jr, Haddad MR, Santos M, Cardoso JLC. Skin manifestations of tick bites in humans. *An Bras Dermatol.* 2018 Mar; 93(2): 251-255.
- [10] Liao CC, Tsai CH, Lo HR, Lin PR, Lin CC, Chao YC. Development of a Scrub Typhus Diagnostic Platform Incorporating Cell-Surface Display Technology. *Front Immunol.* 2021 Oct 11; 12: 761136.
- [11] Jordan DA, Miller CF, Kubos KL, Rogers MC. Evaluation of sepsis in a critically ill surgical population. *Crit Care Med.* 1987 Oct; 15(10): 897-904.
- [12] Kaplan RP. Specific cutaneous manifestations of internal malignancy. *Adv Dermatol.* 1986; 1: 3-42.
- [13] Shepard Z, Rios M, Solis J, Wand T, Henao-Martínez AF, Franco-Paredes C, Suarez JA. Common Dermatologic Conditions in Returning Travelers. *Curr Trop Med Rep.* 2021 Jun; 8(2): 104-111.
- [14] Meyer H, Ehmann R, Smith GL. Smallpox in the Post-Eradication Era. *Viruses.* 2020 Jan 24; 12(2): 138.
- [15] Ramdass P, Mullick S, Farber HF. Viral Skin Diseases. *Prim Care.* 2015 Dec; 42(4): 517-67.
- [16] Erickson BA, Flynn KJ. Management of Necrotizing Soft Tissue Infections (Fournier's Gangrene) and Surgical Reconstruction of Debridement Wound Defects. *Urol Clin North Am.* 2022 Aug; 49(3): 467-478.

- [17] Singh P, Schwartz RA. Disseminated intravascular coagulation: A devastating systemic disorder of special concern with COVID-19. *Dermatol Ther*. 2020 Nov; 33(6): e14053.
- [18] Tomasini C. Septic vasculitis and vasculopathy in some infectious emergencies: the perspective of the histopathologist. *G Ital Dermatol Venereol*. 2015 Feb; 150(1): 73-85.
- [19] Kingston ME, Mackey D. Skin clues in the diagnosis of life-threatening infections. *Rev Infect Dis*. 1986 Jan-Feb; 8(1): 1-11.
- [20] Davey MG, Birrane J, Brennan M, Breen DP, Laing ME. Clindamycin induced toxic epidermal necrolysis versus Staphylococcal scalded skin syndrome: a case report. *Oxf Med Case Reports*. 2020 May 6; 2020(3): omaa020.
- [21] Skuhala T, Trkulja V, Rimac M, Dragobratović A, Desnica B. Analysis of Types of Skin Lesions and Diseases in Everyday Infectious Disease Practice-How Experienced Are We? *Life (Basel)*. 2022 Jun 29; 12(7): 978.
- [22] Takeuchi I, Kondo A, Nagasawa H, Jitsuiki K, Ohsaka H, Ishikawa K, Omori K, Yanagawa Y. A Fatal Case of Japanese Spotted Fever. *Sch J Med Case Rep* 2017; 5(11): 801-804.



© The Author(s) 2023. This article is an open access article distributed under the terms and conditions of the Creative Commons Attribution (CC BY) license (<http://creativecommons.org/licenses/by/4.0/>).