

# Patient with Systemic Lupus Erythematosus who Presented with Area Postrema Syndrome after COVID-19 Vaccination

Carlos Romero-Gómez<sup>1,\*</sup>, Pablo López-Quirantes<sup>1</sup>,  
José Antonio Reyes-Bueno<sup>2</sup>, Ricardo Gómez-Huelgas<sup>1</sup>

<sup>1</sup>Medicina Interna, Hospital Regional Universitario, Málaga, Spain

<sup>2</sup>Neurología, Hospital Regional Universitario, Málaga, Spain

\*Corresponding author: [carlosrg1968@gmail.com](mailto:carlosrg1968@gmail.com)

Received February 10, 2022; Revised March 13, 2022; Accepted March 20, 2022

**Abstract** Area postrema syndrome is a disorder that is included within the neuromyelitis optica spectrum (NMOSD), a group of severe inflammatory disorders of the central nervous system that primarily affect the optic nerve and spinal cord. The cause of NMOSD is unknown, but it has been linked to infections, vaccines and associated with autoimmune diseases. We present the case of a patient with a history of systemic lupus erythematosus who presented with area postrema syndrome after vaccination with COVID-19.

**Keywords:** *postrema area syndrome, neuromyelitis optica, systemic lupus erythematosus, covid-19 vaccination*

**Cite This Article:** Carlos Romero-Gómez, Pablo López-Quirantes, José Antonio Reyes-Bueno, and Ricardo Gómez-Huelgas, "Patient with Systemic Lupus Erythematosus who Presented with Area Postrema Syndrome after COVID-19 Vaccination." *American Journal of Medical Case Reports*, vol. 10, no. 3 (2022): 72-76. doi: 10.12691/ajmcr-10-3-8.

## 1. Introduction

Neuromyelitis optica (NMO) and NMO spectrum disorders (NMOSD) are a group of severe inflammatory diseases of the central nervous system (CNS) that mainly affect the optic nerve and spinal cord. The detection of a highly specific serum immunoglobulin G autoantibody (NMO-IgG) distinguishes NMO from other demyelinating diseases. [1,2] One disease encompassed under NMOSD is area postrema syndrome (APS), characterized by hyperemesis and hiccups that are difficult to control. [3]

The cause of NMO is unknown, but it has been linked to infections and vaccinations and associated with autoimmune diseases such as systemic lupus erythematosus (SLE), Sjögren's syndrome, or myasthenia gravis. [3]

We present the case of a patient with a medical history of SLE who presented with NMOSD in the form of APS after COVID-19 vaccination.

## 2. Presentation of the Case

The patient is a 52-year-old woman with a medical history of SLE who was admitted from another hospital with persistent hyperemesis and hiccups.

The patient had no toxic habits, had a single pregnancy with no incidents in 1997, and took oral contraception until March 2021.

In 1991, she was diagnosed with SLE, presenting with diffuse proliferative nephritis, arthritis, alopecia, Raynaud's phenomenon, antinuclear antibodies (ANA), low complement levels, and anti-dsDNA. She was treated with glucocorticoids and intravenous (IV) cyclophosphamide. In 1998, she presented with polymyositis with no associated skin involvement. It was controlled with prednisone. In 1999, she presented with hiccups and hyperemesis that required hospitalization. No abnormalities were detected on a head CT scan. She had ANA at a titer of 1/320 and a negative anti-dsDNA test. It resolved in two weeks with symptomatic treatment. In 2001, she presented with vasculitis with digital ischemia. She was treated with IV cyclophosphamide and a hyperbaric chamber. Since then, she has been treated with prednisone (doses between 7.5 and 15 mg) with symptoms of asthenia and arthralgia. She had previously been treated with mycophenolate, azathioprine, methotrexate, and antimalarials, but they had been suspended because of inefficacy. She had never had any surgical operations, had anxiety disorder and primary hypothyroidism, had no history of drug allergies, and continued treatment with lorazepam, prednisone 15 mg, esomeprazole, and levothyroxine.

In April 2020, she was vaccinated against COVID-19 with Moderna (first dose). One week later, she presented with headache and fever that lasted for 24 hours. The next day, then without fever or headache, she started having hiccups and hyperemesis. She was treated at home with metoclopramide and chlorpromazine with no

improvement. Two weeks later, she was admitted to another hospital. A complete blood count, gastroscopy, chest CT scan, and head MRI scan were performed, which showed no significant abnormalities. During hospitalization, she received chlorpromazine, baclofen, metoclopramide and dexamethasone.

Given the persistence of symptoms, it was decided to admit her to our hospital. She manifested persistent hiccups and intolerance of intake, vomiting everything she ingested. She had not had headache or fever again and denied abdominal pain. Since one week before, she had lumbar pain that required opioids. An MRI scan of the lumbar spine showed no abnormalities.

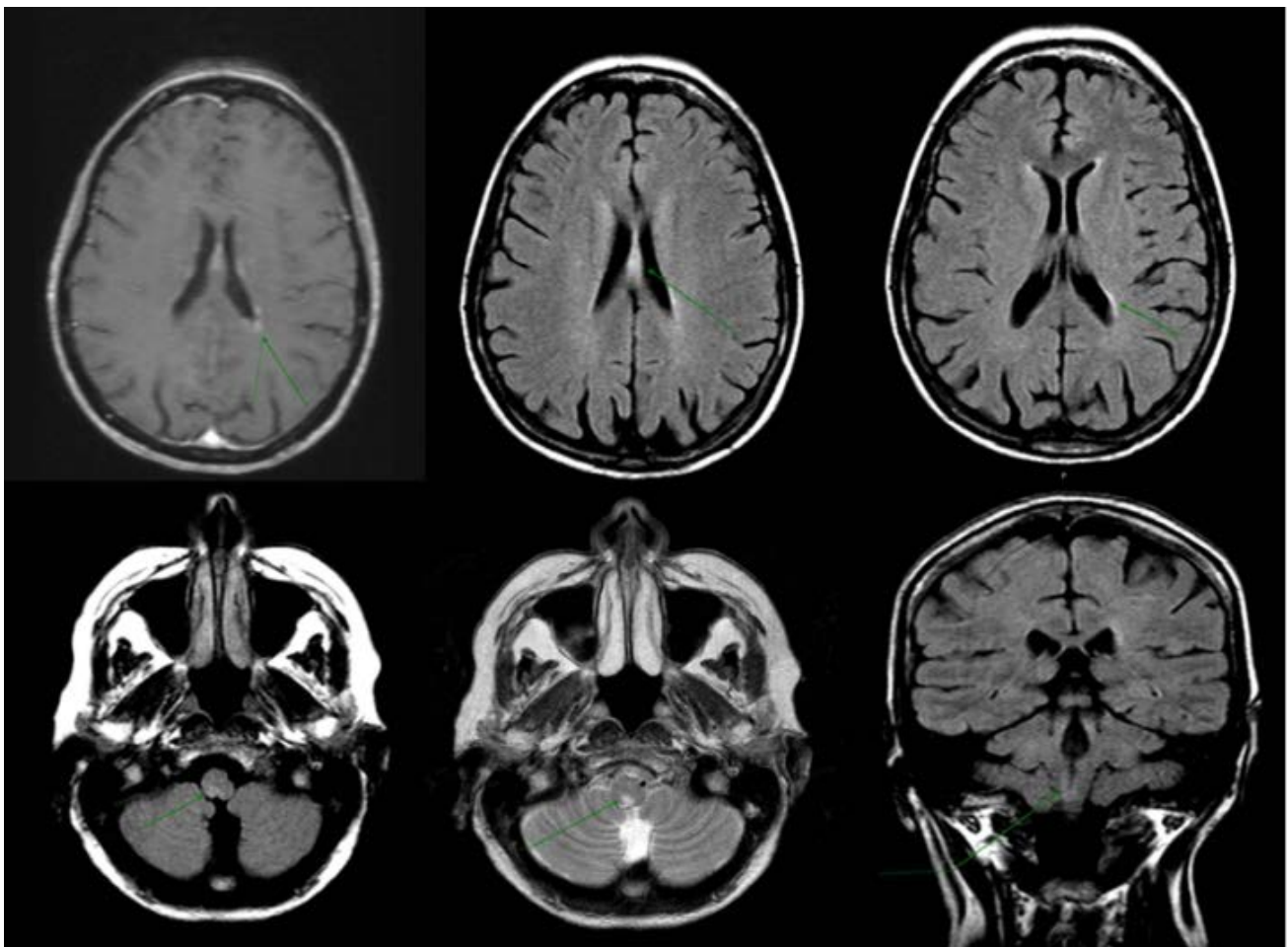
A physical examination found she was afebrile, had blood pressure 85/50 mmHg, and continuously had hiccups and gagging. No abnormalities were observed in the skin or mucosa. She did not have goiter or breast masses. The cardiac and respiratory auscultations and abdominal and limb examinations were normal. She did not present with meningeal or focal signs.

As to additional tests, the complete blood count and chest x-ray did not provide any orientation regarding a possible cause of her symptoms. Serology hepatitis B and C virus and human immunodeficiency virus tests were negative. A lumbar puncture found clear cerebrospinal fluid (CSF), pressure of 12 cmH<sub>2</sub>O, mild pleocytosis, and

high CSF protein levels (leukocytes 20 cells/ $\mu$ L, protein 65 mg/L). A head MRI scan (Figure 1) showed abnormalities of inflammatory origin in the supra- and infratentorial periventricular matter. The Neurology Department was consulted and ordered blood and CSF neuromyelitis optica (NMO-IgG) and myelin oligodendrocyte glycoprotein (MOG-IgG) antibody tests. Both samples were positive for NMO-IgG.

Treatment was given with methylprednisolone boli (250 mg for three days) followed by oral prednisone (40 mg) combined with mycophenolate mofetil. The patient progressively improved, allowing for restarting food intake, suspending symptomatic treatment, and withdrawing parenteral nutrition.

In October 2021, after discussing risks and benefits with the patient, a third Moderna COVID-19 vaccine dose and a flu vaccine were administered. Ten days later, she started having nausea and vomiting. Another head MRI scan showed FLAIR signal abnormalities in the septum pellucidum and posterior margin of the bulb (area postrema)—less marked than the previous scan—related to focal points of gliosis. On this occasion, treatment was given with methylprednisolone (1000 mg for five days) with rituximab (1000 mg, second dose at 14 days). Her later progress was favorable and since then, she has remained asymptomatic.



**Figure 1.** MRI scan of the head: lesions in the periventricular white matter with endymal, supratentorial, and infratentorial involvement

### 3. Discussion and Review of the Literature

NMO is an aggressive inflammatory disorder characterized by recurrent optic neuritis (ON) and myelitis flare-ups. The more inclusive term of NMO spectrum disorder (NMOSD) has been proposed to encompass cases with partial forms and those that involve additional CNS structures [1].

NMO is more common in women than men (9:1) and generally has its onset at an older age than multiple sclerosis (MS), although it can appear at any age, including in children and the elderly [1,2].

In the initial phases, it can be difficult to distinguish between NMO and MS, given that both present with ON, myelitis, and inflammatory demyelinating lesions. At present, NMO is recognized as a distinct, recurrent demyelinating disease with clinical, neuroimaging, and laboratory findings that distinguish it from MS. [1] In patients with NMO, ON flare-ups can be bilateral and cause severe vision loss, which is uncommon in MS. Furthermore, myelitis can be severe and transverse—also rare in MS—and almost always extends longitudinally, affecting three or more contiguous spinal segments. Also unlike MS, NMO symptoms are usually not progressive, but its prognosis is worse than MS.

The area postrema (AP) is a spongy area of the medulla oblongata at the bottom of the fourth ventricle near the median aperture. It has chemoreceptors that can trigger vomiting. Neuroinflammatory involvement of the AP causes clinical symptoms of nausea, vomiting, and hiccups that are difficult to control. This is known as area postrema syndrome (APS) and is a disorder that falls under the umbrella of NMOSD. [4] It is also a highly specific NMO disorder that is hardly related to other demyelinating diseases. APS occurs in 17% to 43% of NMOSD [3] and has a poor prognosis. [4]

Serum NMO-IgG antibody determination in patients with NMO allows for distinguishing NMO from other demyelinating diseases. NMO-IgG is highly specific to NMO and is found in 80% of patients. It is more sensitive in blood than CSF. [5] NMO-IgG has pathogenic power and binds to aquaporin-4, a water channel protein that regulates CNS homeostasis and is largely expressed in specific areas of the brain, including the ependymal surfaces of the ventricles, the corpus callosum, the corticospinal tract, and the periaqueductal region. Among the few patients with clinical symptoms of NMOSD in whom NMO-IgG is not detected, some are positive for IgG antibodies to myelin oligodendrocyte glycoprotein (MOG-IgG). [6]

There is an association with autoimmune diseases such as SLE, Sjögren's syndrome, or thyroiditis in 10% to 40% of patients. [1] In patients with autoimmune diseases who present with symptoms compatible with NMO, the presence of NMO-IgG indicates coexistence of both diseases instead of a neurological manifestation of the rheumatic disease. [5] Serum ANA are detected in 50% of patients with NMO [1].

Despite no clear evidence of a causal relationship between vaccination and onset or recurrence of MS except for a temporal association, this link is often cited in the literature. Various reports have raised the concern that vaccines can trigger or exacerbate demyelinating diseases. The most common form of demyelinating disease

related to vaccination is disseminated encephalomyelitis. However, more and more post-vaccination cases of MS and NMO have been reported. [7]

Severe acute respiratory syndrome coronavirus 2 (SARS-CoV-2) is a highly transmissible pathogenic coronavirus that arose at the end of 2019 and caused a pandemic of acute respiratory disease called coronavirus disease 2019 (COVID-19) that threatens human health. [8] Vaccination is the most effective method for long-term COVID-19 control and prevention. Many vaccine platforms are being developed for vaccination against SARS-CoV-2. Strategies include recombinant vector, DNA, mRNA in lipid nanoparticles, inactivated virus, live attenuated virus, and protein subunit vaccines.

Although vaccines against SARS-CoV-2 are generally well-tolerated, they can cause severe side effects in some patients. The neurological side effects of vaccines against SARS-CoV-2 tend to be mild, last for a short period of time, are self-limited, and can be managed on an outpatient basis. The most common neurological side effects of the SARS-CoV-2 vaccine are headache, Guillain-Barré Syndrome (GBS), cerebral venous sinus thrombosis (CVST), and transverse myelitis. [9,10]

The relationship between vaccination and demyelinating diseases, and NMO in particular, is rare and not fully understood. It is generally attributed to the body's exaggerated autoimmune response to the vaccine's antigen. The most common demyelinating disease that occurs after vaccination is acute disseminated encephalomyelitis; it has mostly been observed in children. [11] As of 2014, only seven cases of vaccination-associated NMOSD had been reported; it is most commonly linked to Gardasil vaccination against human papillomavirus.

Regarding onset of NMO following COVID-19 vaccination, we have only found five other cases in the literature (Table 1). [10,12,13,14,15] The most common presentation is transverse myelitis. Only one other APS case has been reported apart. The vaccines linked to onset of NMO are of different types and mechanisms. This, together with the very few published cases, make it difficult to ensure the relationship is anything more than temporal.

Eighty to ninety percent of patients with NMO have recurrent episodes of ON and myelitis instead of a monophasic course. Relapse occurs within the first year in 60% and within three years in 90% of patients. NMOSD prognosis is generally poor regarding sequelae. Only 22% of patients fully recover and 6% do not recover. The main prognostic factor is presence of myelitis. Mortality is related to neurogenic respiratory failure. [2]

Recommended treatment in the acute phase is glucocorticoid bolus, commonly methylprednisolone 1 g/day for five days, followed by a gradual reduction with prednisone. Plasmapheresis (5-7 changes of 1.5 plasma volumes/session) has been recommended for acute episodes that do not respond to steroids; it seems to have greater efficacy in the most severe cases. [16] Given the unfavorable natural course of untreated NMO, maintenance treatment is recommended. The most commonly used drugs are azathioprine or mycophenolate associated with prednisone or rituximab, an anti-CD20 monoclonal antibody (2 g IV every six months) [5,6]. In observational studies, treatment with azathioprine appears less effective than mycophenolate or rituximab [5]. Other monoclonal antibodies that have

demonstrated efficacy are inebilizumab, a monoclonal antibody against CD19; [12,17] tocilizumab [18] and satralizumab, anti-IL-6 receptor antibodies [19]; and eculizumab, a terminal complement inhibitor [2,20].

**Table 1. Review of cases of neuromyelitis following COVID-19 vaccination**

Sex/age	Syndrome	AB	Vaccine/ Dose-days#	Treatment	Author
M/64	Myelitis	NMO-IgG	Pfizer 1°- 18 days	MPiv	Khayat [10] (pat.4)*
M/34	Confusional state	NMO-IgG	Sputnik 2°- 21 days	Plex	Badrawi [12]
W?	Area postrema syndrome	NMO-IgG	Inactivated 1°-3 days	MPiv	Chen [13]
W/46	Myelitis	Neg.	Moderna 1°-2 days	MPiv	Fujikawa [14]
M/45	Myelitis	Neg.	Astra 1°-11 days	MPiv	Pagenkopf [15]
W/52	Area postrema syndrome	NMO-IgG	Moderna 1°-7 days	MPiv+ MPM+Rit	Romero**

AB= antibody related; # Vaccine doses and days of clinical onset after administration

NMOSD = neuromyelitis optica spectrum disorder; M = Man; W = Woman; S = Syndrome; MPiv = methylprednisolone boli; Plex = plasmapheresis; MPM = Mycophenolate Mofetil; Rit= Rituximab.

\*Patient number 4 in the series

\*\*Case described in this publication

Our patient had the peculiarity of two possible triggers: SLE and COVID-19 vaccination. She had a similar episode 20 years before that was concordant with APS that was self-limited, though cannot be known if it was NMOSD given its tendency towards recurrence and the fact that it was self-limiting without treatment. The two episodes that occurred after COVID-19 vaccination did have a temporal relationship.

## 4. Conclusion

APS is a form of NMOSD characterized by persistent hiccups and vomiting. It is a demyelinating disease with clinical, radiological, and immunological pathophysiology that differs from MS. Most cases are associated with NMO-IgG, an autoantibody related to its highly specific pathogen; patients with MOG-IgG are less common. Although its cause is unknown, it has been associated with autoimmune diseases and vaccination. Some cases associated with COVID-19 vaccination have been described, but given the small number of reports and the massive vaccination of the population, it cannot be assured it is not a casual coincidence. The case presented herein has the particularity of being the first published case in a patient with SLE who had already presented with symptoms several years before and in which there is a temporal link with the second and third COVID-19 vaccine doses.

## Acknowledgements

Our appreciation goes to Dr. Carlos de la Cruz and Dr. Felipe Rubio, who contributed to shed light on this case. Thanks to the radiologist, Dr. Fatima Nagib, for the review of the images.

## References

- Wingerchuk DM, Lennon VA, Lucchinetti CF, Pittock SJ, Weinshenker BG. The spectrum of neuromyelitis optica. *Lancet Neurol.* 2007; 6(9): 805-815.
- Patterson SL, Goglin SE. Neuromyelitis Optica. *Rheum Dis Clin North Am.* 2017; 43(4): 579-591.
- Wingerchuk DM, Banwell B, Bennett JL, et al. International consensus diagnostic criteria for neuromyelitis optica spectrum disorders. *Neurology.* 2015; 85(2): 177-189.
- Camara-Lemarroy CR, Burton JM. Area postrema syndrome: A short history of a pearl in demyelinating diseases. *Mult Scler.* 2019; 25(3): 325-329.
- Flanagan EP. Neuromyelitis Optica Spectrum Disorder and Other Non-Multiple Sclerosis Central Nervous System Inflammatory Diseases. *Contin (Minneap Minn).* 2019; 25(3): 815-844.
- Chan KH, Lee CY. Treatment of neuromyelitis optica spectrum disorders. *Int J Mol Sci.* 2021; 22(16): 1-27.
- Kumar N, Graven K, Joseph NI, et al. Case Report: Postvaccination Anti-Myelin Oligodendrocyte Glycoprotein Neuromyelitis Optica Spectrum Disorder: A Case Report and Literature Review of Postvaccination Demyelination. *Int J MS Care.* 2020; 22(2): 85-90.
- Hu B, Guo H, Zhou P, Shi ZL. Characteristics of SARS-CoV-2 and COVID-19. *Nat Rev Microbiol.* 2021; 19(3): 141-154.
- Finsterer J. Neurological side effects of SARS-CoV-2 vaccinations. *Acta Neurol Scand.* 2022; 145(1): 5-9.
- Khayat-Khoei M, Bhattacharyya S, Katz J, et al. COVID-19 mRNA vaccination leading to CNS inflammation: a case series. *J Neurol.* 2021; (0123456789).
- Karussis D, Petrou P. The spectrum of post-vaccination inflammatory CNS demyelinating syndromes. *Autoimmun Rev.* 2014; 13(3): 215-224.
- Badrawi N, Kumar N, Albastaki U. Post COVID-19 vaccination neuromyelitis optica spectrum disorder: Case report & MRI findings. *Radiol case reports.* 2021; 16(12): 3864-3867.
- Chen S, Fan XR, He S, Zhang JW, Li SJ. Watch out for neuromyelitis optica spectrum disorder after inactivated virus vaccination for COVID-19. *Neurol Sci.* 2021; 42(9): 3537-3539.
- Fujikawa P, Shah FA, Braford M, Patel K, Madey J. Neuromyelitis Optica in a Healthy Female After Severe Acute Respiratory Syndrome Coronavirus 2 mRNA-1273 Vaccine. *Cureus.* 2021; 13(9):e17961.

- [15] Pagenkopf C, Südmeyer M. A case of longitudinally extensive transverse myelitis following vaccination against Covid-19. *J Neuroimmunol.* 2021; 358(January): 577606.
- [16] Songthammawat T, Srisupa-Olan T, Siritho S, et al. A pilot study comparing treatments for severe attacks of neuromyelitis optica spectrum disorders: Intravenous methylprednisolone (IVMP) with add-on plasma exchange (PLEX) versus simultaneous ivmp and PLEX. *Mult Scler Relat Disord.* 2020; 38: 101506.
- [17] Cree BAC, Bennett JL, Kim HJ, et al. Inebilizumab for the treatment of neuromyelitis optica spectrum disorder (N-Momentum): a double-blind, randomised placebo-controlled phase 2/3 trial. *Lancet (London, England).* 2019; 394 (10206): 1352-1363.
- [18] Araki M. Efficacy of the anti – IL-6 receptor antibody tocilizumab in neuromyelitis optica. *Neurology.* 2014; 82(15): 1302-1306.
- [19] Yamamura T, Kleiter I, Fujihara K, et al. Trial of Satralizumab in Neuromyelitis Optica Spectrum Disorder. *N Engl J Med.* 2019; 381(22): 2114-2124.
- [20] Pittock SJ, Berthele A, Fujihara K, et al. Eculizumab in Aquaporin-4-Positive Neuromyelitis Optica Spectrum Disorder. *N Engl J Med.* 2019; 381(7): 614-625.



© The Author(s) 2022. This article is an open access article distributed under the terms and conditions of the Creative Commons Attribution (CC BY) license (<http://creativecommons.org/licenses/by/4.0/>).