

Combination of Ultrasound-Guided Serratus Anterior Plane Block and Rectus Sheath Block Provide Analgesia for Open Hepatectomy: A Report on 3 Cases

Siyou Tan, Wenyan Chen, Yongping Liu, Lai Wei*

Department of Anesthesiology, Hunan Provincial People's Hospital
(The First Affiliated Hospital of Hunan Normal University), Changsha, China

*Corresponding author: 448027999@qq.com

Received February 08, 2022; Revised March 10, 2022; Accepted March 17, 2022

Abstract Perioperative analgesia in open hepatectomy is challenging because a large subcostal arc incision is often required. Extensive dissection of muscles and nerves is associated with severe intraoperative hemodynamic fluctuations and postoperative pain. Serratus anterior plane block (SAPB) and rectus sheath block (RSB) are commonly used for anesthesia and postoperative analgesia in patients undergoing chest wall surgery and abdominal surgery, respectively. In this case-series report, we present our experience with three patients in whom open hepatectomy and early extubation were performed successfully under a combination of ultrasound-Guided SAPB and RSB. Three patients were scheduled for open hepatectomy, all of them were diagnosed with severe hepatitis B cirrhosis. After due deliberation and with the consent of patients and their family, ultrasound-guided right SAPB and bilateral RSB were performed with the patient in the supine position. A total of 0.7mL/kg of 0.25% ropivacaine was used for nerve block. Sensory loss to pinprick from T5 to T10 was achieved in all three patients 20 min after administration of blocks. The operation went smoothly for all the patients. All three patients experienced quiet recovery and early extubation, and none of them complained of discomfort in the surgical site in the first 12 h after surgery. Here we present three cases of a combination of ultrasound-guided SAPB and RSB that may be an attractive option for anesthetic management of open hepatectomy in clinical practice.

Keywords: *serratus anterior plane block, rectus sheath block, analgesia, hepatectomy*

Cite This Article: Siyou Tan, Wenyan Chen, Yongping Liu, and Lai Wei, "Combination of Ultrasound-Guided Serratus Anterior Plane Block and Rectus Sheath Block Provide Analgesia for Open Hepatectomy: A Report on 3 Cases." *American Journal of Medical Case Reports*, vol. 10, no. 3 (2022): 68-71. doi: 10.12691/ajmcr-10-3-7.

1. Introduction

Enhanced recovery following open liver resection surgery benefits from optimal multimodal analgesia involving less invasive techniques allowing early mobilization, patient comfort, and less incidence of postoperative complications. Epidural analgesia remains the gold standard technique for postoperative analgesia for major open abdominal surgery, however, it is not systematically used in hepatectomy because it may cause epidural hematoma and pronounced hemodynamic fluctuation in cirrhosis patients with coagulation dysfunction [1]. Serratus anterior plane block (SAPB) is a relatively new compartment block described in the anesthesia literature for the treatment of thoracic wall pain [2]. Rectus sheath block (RSB) has been proven to reduce the pain from midline abdominal incision and laparoscopic surgery [3]. Traditionally, SAPB uses the fourth and fifth intercostal sites in the midaxillary line as puncture points to block the lateral cutaneous branches of the intercostal nerve in order to relieve pain in the chest

wall [4]. However, SAPB is rarely used for subcostal margin incision analgesia, and there have been few literature reports on the perioperative analgesia of lower SAPB combined with RSB in open liver resection. We report herewith a novel combination of lower SAPB (the sixth to eighth intercostal sites as puncture points) and RSB successfully used for three patients under open hepatectomy. The reporting of these cases was approved by the Ethics Committee at Hunan Provincial People's Hospital (The First Affiliated Hospital of Hunan Normal University). Written informed consent was obtained from all three patients.

2. Case Descriptions

2.1. Case 1

The first patient was a 56-year-old female (weight 59 kg, ASA status III) who was admitted due to right upper abdominal pain for 3 days. After admission, abdominal ultrasonography showed multiple cystic solid mixed echogenic nodules in the liver, which was diagnosed as a

hepatic occupation (cystadenoma). The patient was scheduled for a left hemi hepatectomy. With the consent of the patient and her family, ultrasound-guided SAPB and RSB were performed by an experienced anesthesiologist. Twenty minutes after the block, the patient reported a right-sided T5 to T10 dermatomal sensory loss to pinprick, and the loss of sensation in the plane of the xiphoid process and the edge of rib arch reached the parasternal line and the axillary line on both sides.

2.2. Case 2

The second patient was a 68-year-old male (weight 44 kg, ASA status III). He was admitted to the hospital due to dull pain in the upper abdomen for more than 1 month. After admission, enhanced CT showed a lamellar low-density lesion in the left liver with a high possibility of cholangiocarcinoma, and an open left hepatectomy was scheduled. Twenty minutes after ultrasound-guided SAPB and RSB were performed by the same anesthesiologist, the patient reported a right-sided T5 to T10 dermatomal sensory deficit to pinprick, and the loss of sensation in the plane of the xiphoid process and the edge of rib arch reached the parasternal line and the axillary line on both sides too. Informed consent of the patient and family was obtained before the procedure.

2.3. Case 3

Case 3 was a 49-year-old male (weight 86 kg, ASA status III). Ten months ago, he was diagnosed with a space-occupying lesion in the liver during a routine physical examination. In this admission, the patient was scheduled to undergo open resection of the middle lobe of the liver. Twenty minutes following the SAPB and RSB, he reported a right-sided T5 to T11 dermatomal sensory deficit to pinprick, and the loss of sensation in the plane of the xiphoid process and the edge of rib arch reached the parasternal line and the axillary line on both sides. Informed consent of the patient and family was obtained before the procedure.

3. Ultrasound-guided SAPB and RSB

In each case, patients were routinely monitored by electrocardiogram, invasive arterial blood pressure, pulse oximeter, BIS, and Vigileo. Followed by induction of general anesthesia, right SAPB, and bilateral RSB were performed in the supine position. Hydromorphone (0.005mg/kg) was administered intravenously 10 minutes prior to the blocks for patient comfort during puncture, oxygen was administered by facemask. For the SAPB, we chose a lower puncture site. The purpose of this modification is to diffuse the local anesthetic as far down as possible into the lateral cutaneous branch of the intercostal nerve (mainly T6-T11). A high-frequency 6 to 15 MHz linear probe was used to identify the right serratus anterior plane superficial to the seventh and eighth ribs in the midaxillary line. A 22-gauge, 120 mm needle (stimuplex® aB. Braun, Melsung, Germany) was introduced from caudad to cephalad, in-plane, until the tip lied adjacent to the seventh rib (Figure 1A) [4], and 0.25 % ropivacaine (0.4 mL/kg) was then injected between the external intercostal and the serratus anterior muscles (Figure 1B). For the RSB, the ultrasound probe was positioned transversely on the rectus abdominis muscle, below the costal margin. Guided by real-time ultrasound, the needle was inserted in-plane until its tip was positioned in the plane between the deep side of the rectus muscle and the posterior rectus sheath (Figure 1C) [5], then a total volume of 0.15 mL/kg 0.25% ropivacaine was injected with repeated aspiration (Figure 1D). The identical technique was repeated on the opposite side. The needle-tip placement and spread of local anesthetic in SAPB and RSB were visualized via ultrasound and demonstrated graphically. Surgical procedures for all cases were successful. Postoperatively intravenous patient-controlled analgesia (PCA) with 2µg/kg sufentanil, oxycodone hydrochloride 0.2mg/kg, and 8mg ondansetron was applied. The setting parameters of the analgesia pump include: 2 mL/h continuous infusion volume, 0.5ml bolus doses (15min blocking time), and the maximum infusion volume of 5mL/h.

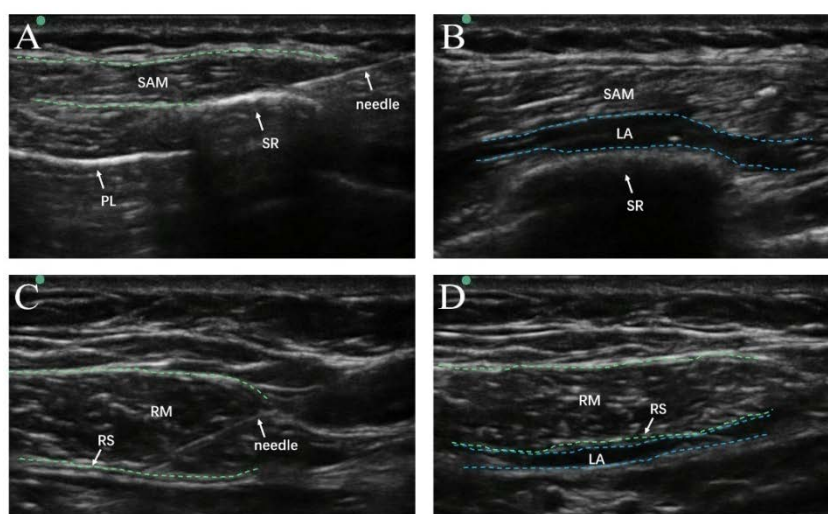


Figure 1. Ultrasound-guided SAPB and RSB. (A) Ultrasound-guided SAPB. (B) A local anesthetic was injected between the external intercostal and the SAM. (C) Ultrasound-guided RSB. (D) A local anesthetic was injected between the deep side of the RM and the posterior RS. SAPB, serratus anterior plane block; RSB, rectus abdominis sheath block; SAM, serratus anterior muscles; RM, rectus muscle; RS, rectus sheath; PL, pleural line; SR, the seventh ribs; LA, local anesthetic

Table 1. Assessment of sensory block achieved in right thoracoabdominal wall

	20min after block		At the end of the operation	
	Sensory loss to pinprick	Sensory loss to ice	Sensory loss to pinprick	Sensory loss to ice
Case 1	T5-T10	T5-T11	T5-T10	T5-T10
Case 2	T5-T10	T6-T10	T6-T10	T6-T10
Case 3	T5-T11	T5-T11	T6-T10	T5-T10

Table 2. Intraoperative conditions

	Blood pressure (mmHg)	Heart rate (bpm)	SpO ₂ (%)	Duration of operation (min)	Blood loss (ml)	Time for recovery from anesthesia (min)
Case 1	131-165/68-90	84-98	95-100	445	500	20
Case 2	145-163/58-89	71-89	97-100	315	350	15
Case 3	127-130/51-85	64-93	98-100	475	600	18

Table 3. Intraoperative usage of propofol and opioids

	Propofol dosage (mg/kg·h)	Remifentanyl dosage (ug/kg·h)	Sufentanil dosage (ug/kg·h)
Case 1	2.5	5.2	0.12
Case 2	2.0	4.8	0.17
Case 3	2.3	5.3	0.13

4. Results

Twenty minutes after the blocks, Sensory loss to pinprick from T5 to T10 in the right thoracoabdominal wall was achieved in all three patients (Table 1). The duration of surgery was 180, 200, and 160 minutes, respectively. Surgery for all patients was successful and extubation procedures for them all were done early, quietly, and smoothly, details of the procedures and parameters are summarized in Table 2. Propofol and opioid usage were shown in Table 3. Analgesics used in PCIA were 2µg/kg sufentanil, oxycodone hydrochloride 0.2mg/kg, and 8mg ondansetron diluted to a final volume of 100ml in normal saline. Parameters of the analgesic pump included 2 ml/h continuous infusion volume, 0.5ml bolus dose, 15min lockout time, and 5ml/h maximum infusion volume. In the first 12 hours in the ward, none of the three patients reported static pain in the incision area, and the visual analog scale scores were all 0–2.

5. Discussion

Considering the complexity of the surgery, such as the scope and site of liver resection and the basic conditions of patients, laparotomy is one of the main treatment methods for hepatolithiasis and primary liver cancer when laparoscopic hepatectomy is not suitable for implementation. Open hepatectomy is usually performed by an inverted L-shaped incision in the upper abdomen, that is, opening from the lower middle of the xiphoid process, extending right horizontally along the right costal arch to the vicinity of the 10th rib at the level of T9. The incision results in a wide range of tissue, muscle, and nerve dissociation, which is often accompanied by severe postoperative pain, The pain reaction leads to a limited respiratory movement, increases the incidence of pulmonary infection and respiratory insufficiency, and affects the patient's mental and psychological state and sleep quality, thus increasing the length of hospital stay. Due to the

higher demand for intraoperative and postoperative analgesia, patients are often given a larger dose of intravenous analgesics. As the incidence of complications related to the use of opioids, such as nausea, vomiting, and itching of the skin also increases, it is of great importance to seek perfect perioperative analgesia techniques and protocol. In this study, all three patients in this case series were high-risk cases for neuraxial anesthesia. Under SAPB and RSB, all of whom experienced quiet recovery and early extubation (20min, 15min, 18min, respectively). After recovery from anesthesia, the patients were evaluated three times every 30 minutes, and the VAS score was 0/10 in all these three evaluations. Based on the pain evaluation results of postoperative patients, it was found that SAPB combined with bilateral RSB could meet the analgesic needs of subcostal margin arc incision in open hepatectomy, showing good perioperative analgesic effect.

SAPB was proposed by Blanco et al. [6] in 2013. The autopsy showed that by injecting dye into the serratus anterior plane of the fourth and fifth intercostal intercostals in the midaxillary line, the diffusion plane could be observed to reach T2-T10, thus realizing the block of the lateral cutaneous branch of the intercostal nerve [2]. Based on the classical serratus anterior block, moving the block point downward could make the local anesthetic mainly diffuse to the lower intercostal nerve (T8~T9) [7]. However, the serratus anterior block mainly blocks the lateral cutaneous branch of the anterior spinal nerve, and it is difficult to cover the median incision innervated by the anterior cutaneous branch, so the block effect is not complete. Therefore, we remedied the insufficiency of the right SAPB by combining it with bilateral RSB. In all three patients, hemodynamic fluctuations were found to be relatively stable during severe stimulation procedures such as skin incisions and traction after both nerve blocks were performed. In addition, perioperative intravenous use of opioids such as sufentanil and remifentanyl was relatively low, demonstrating that the combination of the two nerve block analgesia regimens was effective.

Some limitations need to be acknowledged. The SAPB combined with bilateral RSB was mainly used for the

analgesia of incision pain but has a weak analgesic effect on visceral pain. In this study, all three patients did not experience obvious visceral pain in the recovery room and postoperative follow-up, which may be related to the use of oxycodone in PCA used for postoperative intravenous analgesia. Further studies are needed to compare the effects of the SAPB and RSB, and other analgesic methods, such as paravertebral block, quadratus lumborum block, and intravenous analgesia on perioperative incision pain and visceral pain. In addition, the 0.25% concentration of ropivacaine was used for both nerve block techniques in this study, and the analgesic effect of multiple concentrations was not explored. The conclusions of this study need to be further confirmed in larger sample sizes and multi-center clinical trials.

In this preliminary experience, the technique was easily and quickly performed, providing adequate pain control during both intra- and postoperative periods. The case series suggest that the combination of lower SAPB and RSB can effectively provide perioperative analgesia for subcostal incisions during liver resection and maybe alternative abdominal analgesia for patients with coagulopathy or difficulty tolerating epidural puncture procedures. In conclusion, the combination of lower SAPB and RSB may represent a valuable and less invasive option for intra-postoperative analgesia for open hepatectomy surgery, future clinical studies are necessary to elucidate its role in major abdominal surgery.

Abbreviations

SAPB, serratus anterior plane block; RSB, rectus sheath block; SAM, serratus anterior muscles; RM, rectus muscle; RS, rectus sheath; PL, pleural line; SR, the seventh ribs; LA, local anesthetic; ASA, American Society of Anesthesiologist; EEG: electroencephalogram; BIS: bispectral index of EEG; PCIA: Patient-controlled intravenous analgesia

Availability of Data and Materials

The datasets of the current study are available from the corresponding author on reasonable request.

Funding

This study was funded by grants from the Education Department of Hunan Province (No. 16C0971 to LW).

Acknowledgments

We appreciate the efforts of all healthcare providers and the patients and families for their participation in this study. We also acknowledge the Department of Anesthesiology

team in Hunan Provincial People's Hospital (The First Affiliated Hospital of Hunan Normal University) for supporting the research.

Authors Contributions

LW raised the initial idea and supervised all the perioperative management and patient care. ST performed the peripheral nerve blocks and was a major contributor in writing the manuscript. ST, WC, and YL recorded and collected all information during and after the surgeries and follow-up. All authors read and approved the final manuscript.

Ethics Approach and Consent to Participate

Written informed consent was obtained from the patient. The consent form will be provided upon request.

Consent for Publication

All patients consented to the educational publication of this case report and any accompanying images and written informed consent were obtained from the patients.

Competing Interests

The authors declare that they have no competing interests.

References

- [1] Fujio A, Miyagi S, Tokodai K, et al. Effects of a new perioperative enhanced recovery after surgery protocol in hepatectomy for hepatocellular carcinoma [J]. *Surg Today*, 2019.
- [2] Biswas A, Castanov V, Li Z, et al. Serratus Plane Block: A Cadaveric Study to Evaluate Optimal Injectate Spread [J]. *Reg Anesth Pain Med*, 2018, 43(8): 854-858.
- [3] Landmann A, Visoiu M, Malek MM. Development of a novel technique for bilateral rectus sheath nerve blocks under laparoscopic-guidance [J]. *J Pediatr Surg*, 2017, 52(6): 966-969.
- [4] Okmen K, Metin Okmen B. Evaluation of the effect of serratus anterior plane block for pain treatment after video-assisted thoracoscopic surgery [J]. *Anaesth Crit Care Pain Med*, 2018, 37(4): 349-353.
- [5] Jeong HW, Kim CS, Choi KT, et al. Preoperative versus Postoperative Rectus Sheath Block for Acute Postoperative Pain Relief after Laparoscopic Cholecystectomy: A Randomized Controlled Study [J]. *J Clin Med*, 2019, 8(7).
- [6] Blanco R, Parras T, McDonnell JG, et al. Serratus plane block: a novel ultrasound-guided thoracic wall nerve block [J]. *Anaesthesia*, 2013, 68(11): 1107-13.
- [7] Elsharkawy H, Maniker R, Bolash R, et al. Rhomboid Intercostal and Subserratus Plane Block: A Cadaveric and Clinical Evaluation [J]. *Reg Anesth Pain Med*, 2018, 43(7): 745-751.

