

# Severe Ulcerative Colitis-like Pattern of Segmental Colitis Associated with Diverticulosis Complicated with a Colo-umbilical Fistula: Case Report

Luis M. Nieto<sup>1,\*</sup>, Sharon Narvaez<sup>2</sup>, Sanskriti Sharma<sup>1</sup>, Luther Burse<sup>3</sup>

<sup>1</sup>Department of Internal Medicine, WellStar Atlanta Medical Center, Atlanta, Georgia, USA

<sup>2</sup>Facultad de Ciencias Medicas, Universidad de Guayaquil, Ecuador

<sup>3</sup>Gastroenterology consultant, WellStar Atlanta Medical Center, Atlanta, Georgia, USA

\*Corresponding author: [dr\\_luismiguelnieto@hotmail.com](mailto:dr_luismiguelnieto@hotmail.com)

Received December 12, 2021; Revised January 17, 2022; Accepted January 25, 2022

**Abstract** A 49-year-old African American male with history of diverticulitis presented to the ED with abdominal pain and feculent discharge from the umbilicus. CT scan of the abdomen showed a fistulous tract from the sigmoid colon to the umbilicus. Labs revealed a markedly elevated fecal calprotectin level and colonoscopy demonstrated friable-appearing mucosa of the sigmoid colon. Segmental colitis associated with diverticulosis (SCAD) refers to a chronic, localized, nongranulomatous inflammation, usually in the sigmoid colon. SCAD spares the rectum and the proximal colon endoscopically and histologically. We present a case of diverticular disease associated with an unusual fistula and features of SCAD.

**Keywords:** *diverticulosis, diverticulitis, fistula, Segmental Colitis*

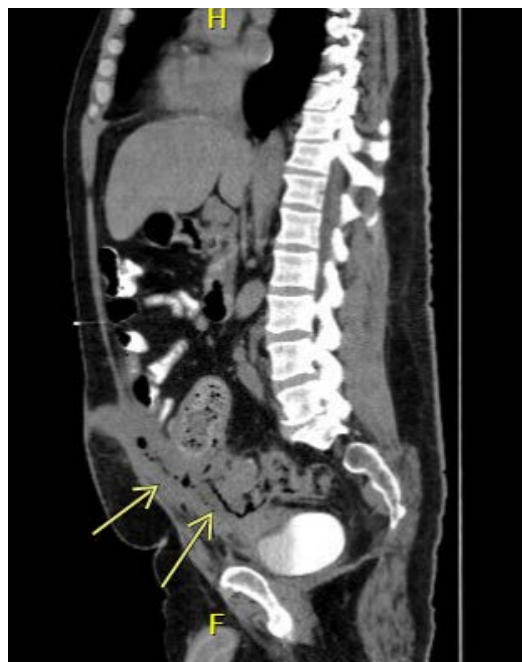**Cite This Article:** Luis M. Nieto, Sharon Narvaez, Sanskriti Sharma, and Luther Burse, “Severe Ulcerative Colitis-like Pattern of Segmental Colitis Associated with Diverticulosis Complicated with a Colo-umbilical Fistula: Case Report.” *American Journal of Medical Case Reports*, vol. 10, no. 2 (2022): 39-45. doi: 10.12691/ajmcr-10-2-5.

## 1. Introduction

Colonic diverticulosis is a common disease in the Western region, being a more frequent finding in older populations but also reported in young patients [1,2]. The inflammatory presentation of colonic diverticulosis is mainly classified in diverticulitis and segmental colitis associated with diverticulosis (SCAD) [3,4]. Patients with diverticular disease can develop SCAD, mostly in the sigmoid colon without involvement of rectum and right colon; endoscopically and histologically can mimic inflammatory bowel disease (IBD) presentations [5].

## 2. Case Presentation

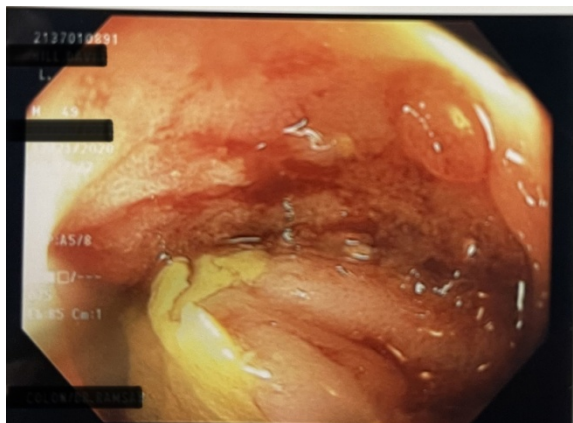
A 49-year-old African American male with history of diverticulosis and recurrent episodes of diverticulitis presented to the ED with two days of abdominal pain and feculent discharge from the umbilicus. Past medical history included uncontrolled Type 2 diabetes mellitus, uncontrolled hypertension, bipolar disorder, and chronic opiate use for back pain. CT scan of the abdomen and pelvis with IV and oral contrast showed a soft tissue density tract containing air and feculent material extending from the sigmoid colon to the umbilicus (Figure 1).



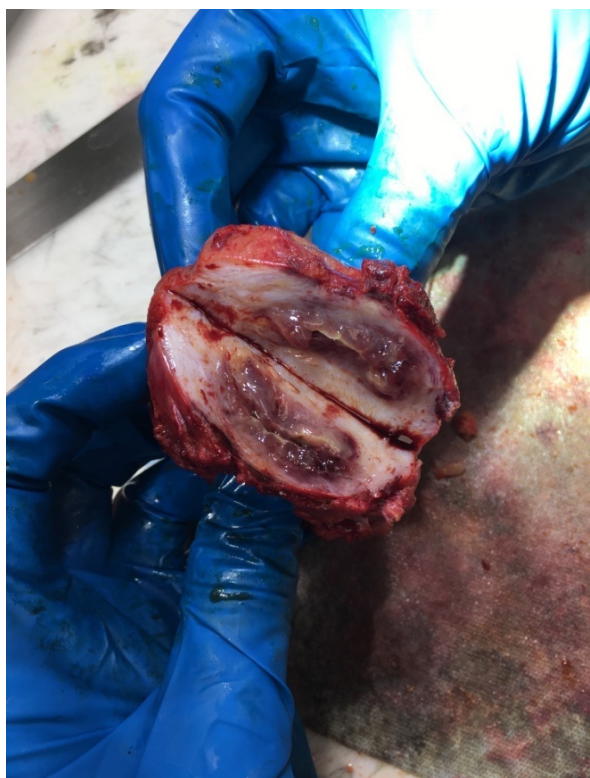**Figure 1.** CT abdomen and pelvis with oral and IV contrast. Sinus tract from the sigmoid to the umbilicus

The radiologist interpreted the findings as a colocutaneous fistula to the umbilicus. Labs revealed a markedly elevated fecal calprotectin level of 2,370 (<50) mcg/g and

an elevated ASCA IgA of 40.9 units (<20.0 units). The patient received two weeks of cefepime and metronidazole for his complicated diverticulitis and four weeks of total parenteral nutrition for his fistula management and sustained hypoalbuminemia (lowest albumin level 2.5 [3.5-5.7] g/dL). Colonoscopy demonstrated normal rectal mucosa and friable-appearing mucosa at the level of sigmoid colon, with an area of stricture that prevented the advancement of the colonoscope (Figure 2).



**Figure 2.** Colonoscopy with friable-appearing mucosa at the level of the sigmoid and an area with diverticular sparing



**Figure 3.** Macroscopic sample of colo-cutaneous fistulectomy

The patient eventually required colo-cutaneous fistulectomy (Figure 3) and creation of a colostomy to restore oral feeding and improve nutritional status. Biopsy of the sigmoid colon showed mixed inflammation, presence of Paneth cell metaplasia, crypt distortion, and cryptitis extending through the fistulous tract. These results were interpreted by two pathologists as most consistent with ulcerative colitis. Eight weeks after surgery, follow-up flexible sigmoidoscopy and endoscopy through the

colostomy showed some areas with mild erythema in the rectum and a completely normal endoscopic appearance in the distal ileum, cecum, right colon, and transverse colon. Random biopsies in the rectum showed mild nonspecific chronic inflammation.

### 3. Discussion

The presence of symptomatic diverticula in the colon can have a variety of presentations, like diverticulitis, diverticular bleeding, and less frequent segmental colitis. Most of the diverticulitis presentations are uncomplicated but a small percentage can complicate with abscess, obstruction, perforation, or fistula formation [6]. One of the reasons for surgical treatment in diverticular disease is fistula formation, being the most frequent, colovesical (48%) and colovaginal fistulas (44%). A smaller number of fistulas correspond to coloenteric (2%), colouterine (2%) and colocutaneous (4-5%); fistulization from the colon to the umbilicus is even rarer [7,8].

SCAD is a rare inflammatory condition with a prevalence of 0.3 to 1.3 % in patients with diverticulosis, being higher in men with a mean age of 63.6 as Mann et al found in their metanalysis of 486 cases [9]. The most common clinical manifestations are chronic diarrhea, left lower quadrant abdominal pain and rectal bleeding [10,11]. CT scan can exhibit colonic wall thickening and sometimes evidence of pericolonic fat stranding. Fecal calprotectin may be elevated specially when the inflammation is severe, helping to distinguish from functional syndromes as diverticular disease and irritable bowel syndrome, but not useful to differentiates from IBD that also elevates it.

The diagnosis of SCAD is made with the evidence of endoscopic features and inflammatory changes on biopsy. The inflammatory localization is in the interdiverticular mucosa of the sigmoid colon that can extend to the descending colon but spares the right colon and rectum [12]. Tursi et al organized SCAD endoscopically in 4 different patterns [11]: Type A (crescentic fold pattern), showing red circular lesions localized in the upper part of the colonic mucosal fold. Type B (mild to moderate ulcerative colitis-like pattern), comprising the submucosal vascular loss, hyperemic edematous mucosa and diffuse erosions. Type C (Crohn's Disease colitis-like pattern), displaying a normal colonic mucosa with aphthous ulcers. Type D (Severe ulcerative colitis-like pattern) similar to type B but more severe with intense hyperemia and colonic lumen caliber reduction. Unfortunately, at this time the literature has not provided an optimal treatment or response to some therapeutic alternatives based on this classification but has been shown correlation with the severity of symptoms.

Histologically, SCAD shows a normal mucosa in rectal biopsies and a variety of chronic inflammatory changes in the sigmoid colon, depending of the type of endoscopic finding. The crescentic fold pattern has acute-on-chronic inflammation with lymphocytic and neutrophilic infiltration. Crohn's disease colitis-like pattern shows full mucosa thickness, micro-fissures, epithelioid granulomas and lymphoplasmacytic inflammation. Ulcerative colitis-like pattern, depending on the severity of inflammation (Type

B or D) may have a lamina propria with eosinophilic expansion, basal plasmacytosis and lymphoid aggregates, crypt architecture distortion, neutrophilic or granulomatous cryptitis, crypt abscesses and Paneth cell metaplasia [11,12,13,14]. Per macroscopic and pathology findings our patient showed Type D pattern.

The initial treatment of SCAD includes high-fiber diet and antibiotics; if the patient does not respond to them, 5-aminosalicylic acid or sulfasalazine is added [15]. Oral steroids or topical enema can also be considered when patients fail the initial management. Segmental colonic resection is an individualized therapeutic option, usually reserved for patient refractory to steroid or tapering difficulties but in some cases the surgery is performed early to control severe symptoms. In our patient, the decision to do surgery in a few weeks after use of antibiotic therapy was due to the evident obstruction and development of a fistula.

Our patient's case highlights the difficulties of distinguishing SCAD from both inflammatory bowel disease and active diverticular disease. When patients present with florid inflammatory changes can mimic IBD cases especially if develop complications such as bowel obstruction or fistula formation, pathology reports can make its diagnosis challenging if the clinician lack of strong suspicious. Our case is unique because the development of a spontaneous colo-umbilical fistula in undiagnosed SCAD, placed him in a rare diverticular disease presentation not reported before to our knowledge.

## Acknowledgements

Our case report did not receive any funding/financial support.

## Conflict of Interest

The authors declare that there is no conflict of interest in this work.

## References

- [1] Parks TG. Natural history of diverticular disease of the colon. *Clin Gastroenterol.* 1974; 4:53-69.
- [2] Minardi, Andrew J., Jr, Johnson LW, Schon JK, Zibari GB, McDonald JC. Diverticulitis in the young patient. *Am Surg.* 2001; 67(5): 458-61.
- [3] Tursi A. New physiopathological and therapeutic approaches to diverticular disease of the colon. *Expert Opin Pharmacoter.* 2007; 8: 299-307.
- [4] Tursi A, Elisei W, Brandimarte G, Giorgetti GM, Lecca PG, Di Cesare L, Inchingolo CD, Aiello F (2009) The endoscopic spectrum of segmental colitis associated with diverticulosis. *Colorectal Dis.* PMID: 19558591.
- [5] Mann NS, Hoda KK. Segmental colitis associated with diverticulosis: systematic evaluation of 486 cases with meta-analysis. *Hepatogastroenterology.* 2012; 59: 2119-2121.
- [6] Colcock BP, Stahmann FD. Fistulas complicating diverticular disease of the sigmoid colon. *Ann Surg.* 1972; 175(6): 838-846.
- [7] Pracyk JB, Pollard SG, Calne RY. The development of spontaneous colo-umbilical fistula. *Postgrad Med J.* 1993; 69(815): 750-751.
- [8] T. Fujii, T. Nakabayashi, S. Hashimoto, and H. Kuwano, "A delayed recrudescence case of sigmoidocutaneous fistula due to diverticulitis," *Case Reports in Gastroenterology*, vol. 1, no. 1, pp. 116-122, 2007.
- [9] Mann NS, Hoda KK. Segmental colitis associated with diverticulosis: systematic evaluation of 486 cases with meta-analysis. *Hepato-gastroenterology.* 2012 Oct; 59(119): 2119-2121.
- [10] Evans JP, Cooper J, Roediger WE. Diverticular colitis - therapeutic and aetiological considerations. *Colorectal Dis.* 2002 May; 4(3): 208-212.
- [11] Tursi A, Elisei W, Brandimarte G, Giorgetti GM, Lecca PG, Di Cesare L, Inchingolo CD, Aiello F. The endoscopic spectrum of segmental colitis associated with diverticulosis. *Colorectal Dis.* 2010 May; 12(5): 464-70.
- [12] Cassieri C, Brandimarte G, Elisei W, Lecca GP, Goni E, Penna A, Picchio M, Tursi A. How to Differentiate Segmental Colitis Associated With Diverticulosis and Inflammatory Bowel Diseases. *J Clin Gastroenterol.* 2016 Oct; 50 Suppl 1: S36-8.
- [13] Makapugay LM, Dean PJ. Diverticular disease-associated chronic colitis. *Am J Surg Pathol.* 1996 Jan; 20(1): 94-102.
- [14] Evans JP, Cooper J, Roediger WE. Diverticular colitis - therapeutic and aetiological considerations. *Colorectal Dis.* 2002 May; 4(3): 208-212.
- [15] Freeman H. Natural history and long-term clinical behavior of segmental colitis associated with diverticulosis (SCAD syndrome). *Dig Dis Sci.* 2008; 53: 2452-2457.

