

Thrombotic Microangiopathy in Autopsy-Confirmed Lung Signet Ring Cell Carcinoma

Carlos E. Gonzalez^{1*}, Luis A. Gonzalez¹, Luis A. Cesenas², Olga G. Cantu³

¹Departamento de Medicina Interna, Hospital Universitario “José E. González”, Monterrey, México

²Departamento de Patología, Hospital Universitario “José E. González”, Monterrey, México

³Departamento de Hematología, Hospital Universitario “José E. González”, Monterrey, México

*Corresponding author: carlosegugio_00@hotmail.com

Received November 27, 2021; Revised January 03, 2022; Accepted January 11, 2022

Abstract Thrombotic Microangiopathy (TMA) has been described as a rare paraneoplastic syndrome. We present a patient with Coombs-negative hemolytic anemia and schistocytes in a peripheral blood smear, fulfilling diagnosis criteria for TMA. After patients death, an autopsy report revealed bone infiltrating signet ring cell carcinoma, identifying the lung as the primary tumor origin.

Keywords: *Thrombotic microangiopathy, microangiopathic hemolytic anemia, signet ring cell carcinoma, paraneoplastic syndrome, lung cancer*

Cite This Article: Carlos E. Gonzalez, Luis A. Gonzalez, Luis A. Cesenas, and Olga G. Cantu, “Thrombotic Microangiopathy in Autopsy-Confirmed Lung Signet Ring Cell Carcinoma.” *American Journal of Medical Case Reports*, vol. 10, no. 2 (2022): 22-25. doi: 10.12691/ajmcr-10-2-1.

1. Introduction

Thrombotic microangiopathy (TMA) is a rare and often fatal complication of cancer that is defined by thrombocytopenia (a platelet count <150,000/ml or a platelet count reduction of more than 30% from the baseline value), evidence of microangiopathic hemolytic anemia (MAHA), and end-organ damage [1].

2. Case Presentation

A 40-year-old man was admitted to the emergency department (ED) during the COVID-19 pandemic, complaining of back pain, progressive fatigue, and weakness. His symptoms started a month before with weight loss and interscapular back pain that intensified in the following weeks. The pain soon involved the whole back. Afterward, the pain was continuous and increased with physical activity. The patient also complained of progressive fatigue and muscle weakness, moderate dyspnea on exertion, and palpitations. The day before admission, he experienced extreme fatigue, which confined him to bed, and he was reported as confused and drowsy. This condition prompted the visit to the ED.

On physical examination, his blood pressure was 100/50 mmHg, heart rate was 48 bpm, respiratory rate 33bpm, body temperature 37.6°C, and 99% oxygen saturation on room air; lung examination was normal, but a multifocal holosystolic heart murmur was auscultated. The patient was drowsy but alert when stimulated with

pale-yellowish skin and diffuse petechiae covering the anterior chest and neck (Figure 1). The patient's clinical history included chronic cannabis consumption and sporadic use of crystal meth. Blood tests revealed severe anemia and thrombocytopenia, with hemoglobin level of 2.6 g/dl and a platelet count of 19.49 k/ul. Reticulocytes were elevated (23%), suggesting regenerative anemia. Indirect hyperbilirubinemia was present with elevated lactate dehydrogenase levels of 1851UI/L and a significant elevation of alkaline phosphatase of 1798 UI/L. Creatinine was 0.5 mg/dL. A peripheral blood smear revealed schistocytes. A direct Coombs test was performed and was negative. These lab findings suggested microangiopathic hemolytic anemia. The patient had a PLASMIC score of 7. A central line was placed, and plasma exchange was considered. An ADAMST13 test was not feasible because of the patient's clinical evolution. SARS-CoV-2 RT-PCR from a nasopharyngeal sample was performed and was negative.

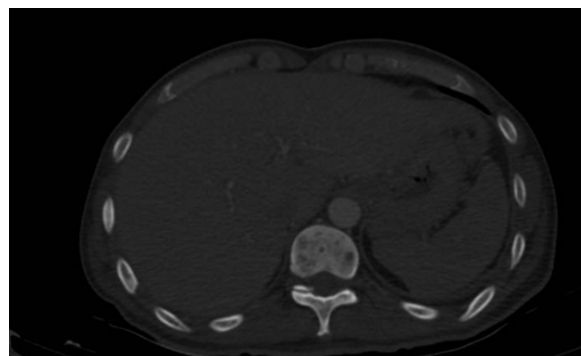


Figure 1. Hepatomegaly and osteolytic bone lesions on CT scan

Malignancy was suspected because of the patient's history of back pain and the marked elevation of ALP levels; therefore, a thoracoabdominal CT scan was ordered. It showed a left pleural effusion of 20%, an enlarged mediastinal node (1.5 cm), and multiple osteolytic lesions on the dorso-lumbar vertebrae and pelvis (Figure 1). No apparent primary tumor was identified.

Steroids were started. Two erythrocyte concentrates and seven platelet concentrates were transfused, and hematology and oncology consultations were requested. Ultrasound-guided thoracocentesis was attempted, but a sample could not be obtained. The patient's condition worsened the next day with altered mental status and hypotension, which was not fluid responsive. The patient deteriorated and died the same day.

An autopsy revealed signet ring cell infiltration in bone marrow (Figure 2), an alveolar space in the lung (Figure 3), and a peribronchial lymph node (Figure 4). A pathological examination of the case revealed a primary lung signet ring cell cancer.

3. Case Discussion

Thrombotic microangiopathy (TMA) can present as a primary condition and secondary to a wide variety of etiologies. Currently there are nine recognized categories of TMA. Common etiologies include acquired ADAMTS 13 deficiency, hemolytic uremic syndrome but it can also be present in the context of autoimmunity and systemic inflammation. The common pathophysiological trait is endothelial inflammation resulting in microvascular ischemia. TM may have a similar clinical presentation, independently from the etiology, representing a challenge regarding diagnosis. TM rarely occurs secondary to cancer.

Incidence of cancer-associated TM has been reported as up to 19% of all secondary TM, 50% secondary to adenocarcinoma, and the rest predominantly to hematologic malignancies [2]. Cancer-associated thrombotic microangiopathy was first described in gastric cancer almost 50 years ago and has subsequently been reported in other types of cancer. Primary signet ring cell carcinoma has a low incidence, reported between 0.14 and 1.9% [3]. Socola et al. reported a peritoneal invading metastatic mesothelioma presenting with TMA [4]. There have also been reports of TMA and pulmonary involvement presenting in other types of cancer, such as hepatocarcinoma, prostate cancer, and more commonly, gastric cancer [5-10]. Cancer-associated TMA has also been reported related to signet cell invading tumors, including the work of Eisa et al. [11], which describes the case of a 31-year-old male presenting with TMA and later discovering a primary gastric tumor with signet ring cells. Malkan et al. [12], reported a similar case of a 35-year-old man presenting with TMA and finally discovering a primary gastric adenocarcinoma with signet ring cell characteristics. Finally, Otrock et al. [13], described a similar case involving bone marrow in an advanced gastric cancer presenting with signet ring cells.

Our patient had a rare occurring presentation of TMA secondary to a lung signet ring cell carcinoma with bone marrow involvement. After assessing the possible causes involved in our case, we concluded that this event had been reported previously and predominantly in advanced gastric cancer. We have pathological evidence of non-gastric involvement, which is relevant because of literature reports and strong evidence of the primary tumor being in the lungs. To our knowledge, this is the first case report involving a TMA finding with a primary lung signet ring cell carcinoma with metastasis.

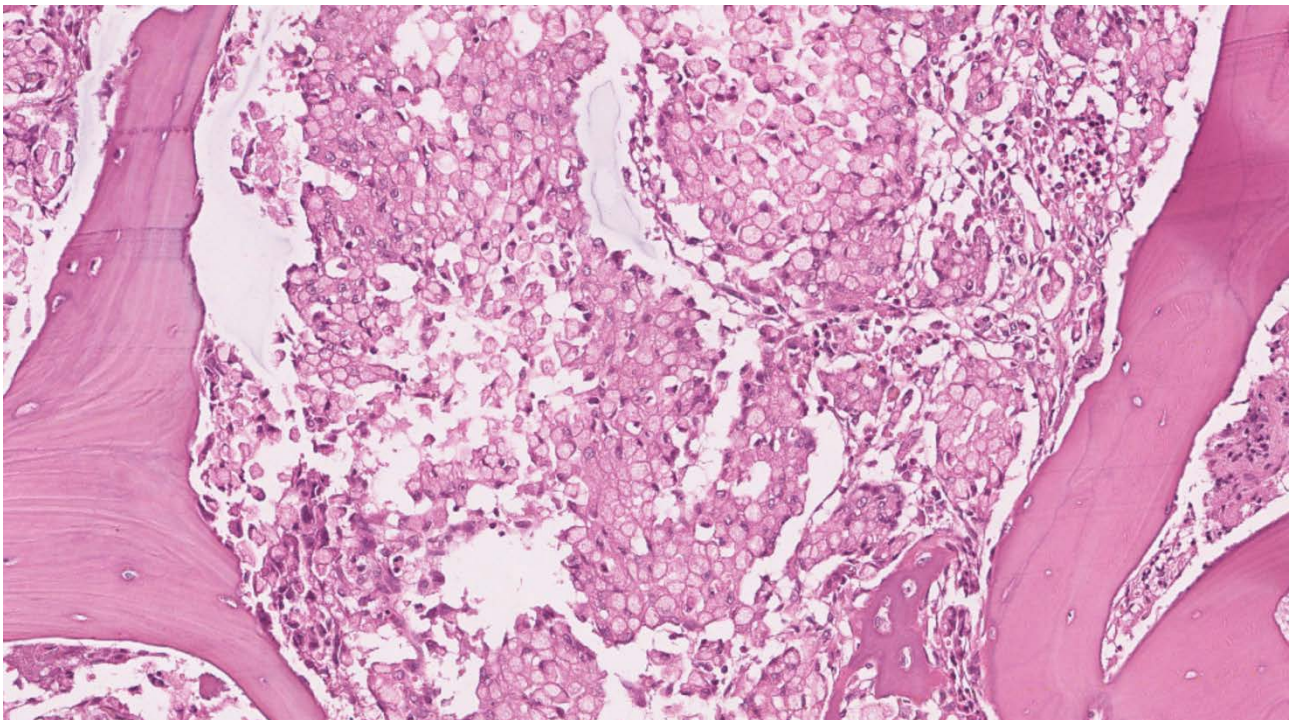


Figure 2. Signet ring cell carcinoma infiltrating bone marrow

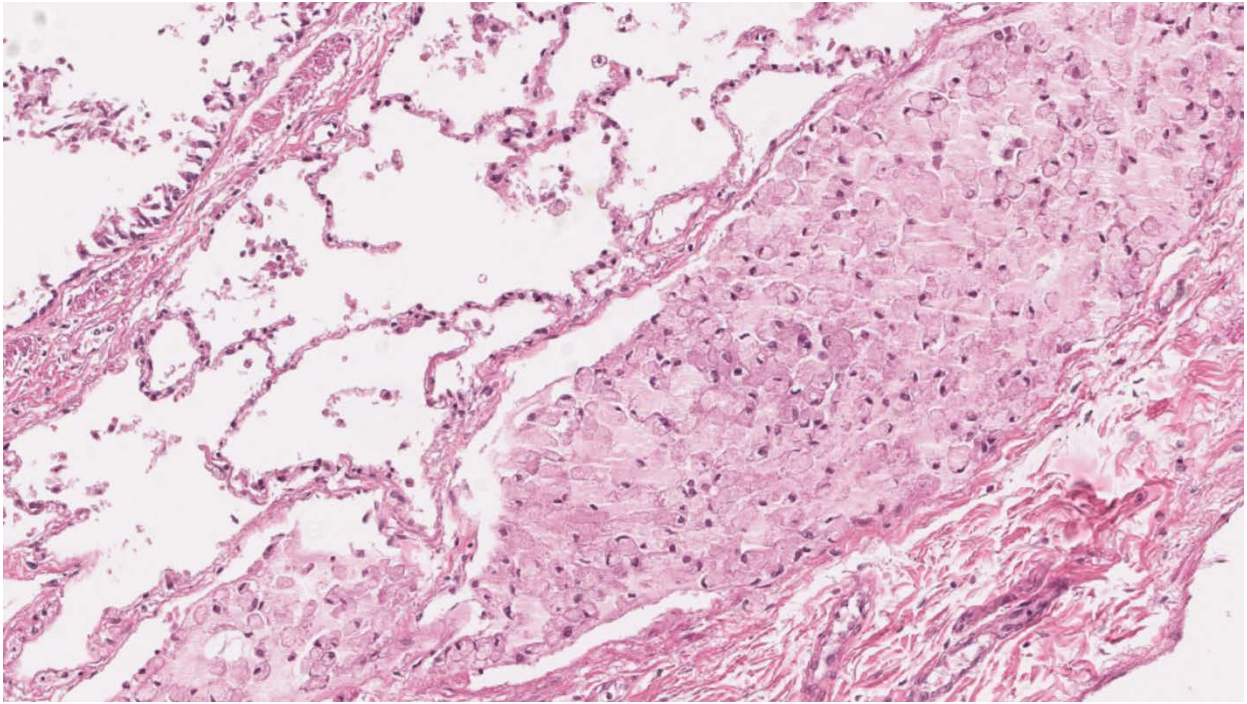


Figure 3. Lung biopsy showing signet cell infiltration in alveolar space

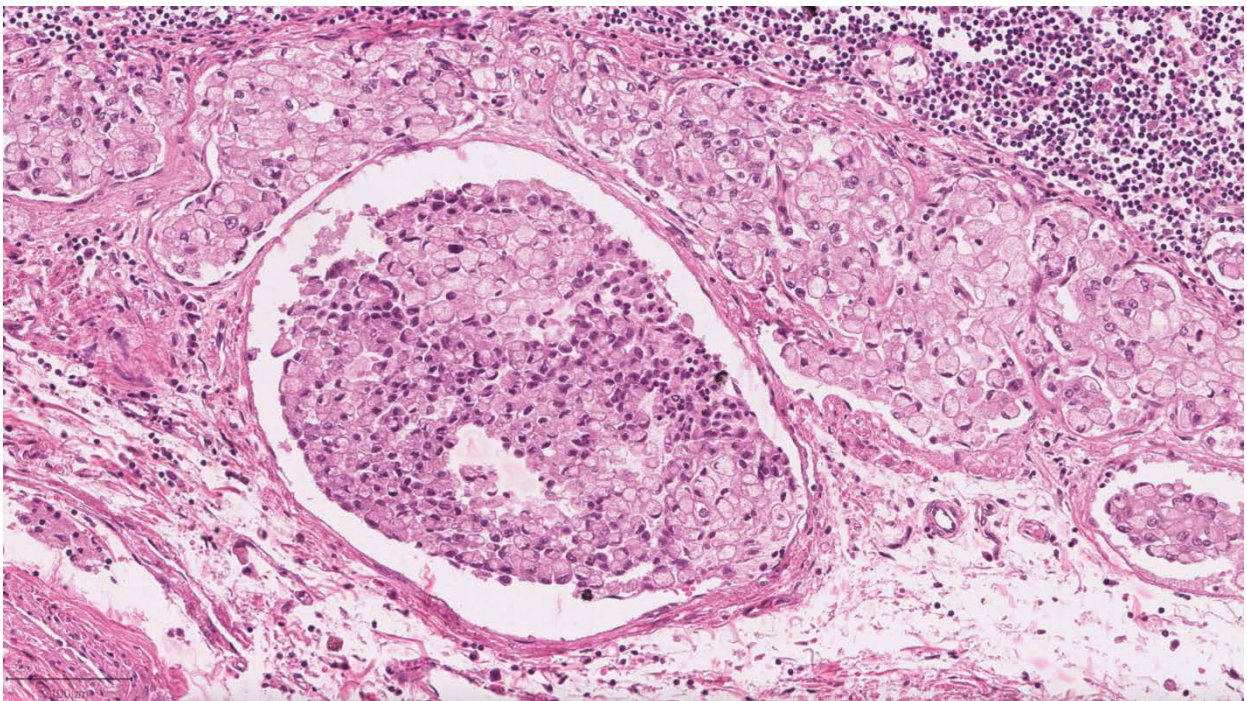


Figure 4. Peri bronchial lymph node showing signet cell carcinoma infiltration

4. Conclusions

TMA is described as one of the rare occurring complications of cancer and can sometimes be the initial presentation of some patients. There are few reports of malignancy associated TMA in signet ring cell cancer, we can conclude that we have encountered a rare finding among the described complications of cancer. An important limitation in the case was not being able to perform an ADAMST13 laboratory test to evaluate its activity and not being able to evaluate the therapeutic response because of the rapid onset of clinical

deterioration.

The findings reported in this case are important when evaluating patients with similar clinical and laboratory findings on admission because these findings could orient clinicians to a precise diagnosis in the context of this challenging clinical entity.

Acknowledgements

We thank the internal medicine department of the Hospital Universitario “José Eleuterio González”.

References

- [1] Weitz IC., "Thrombotic microangiopathy in cancer." *Thromb Res.* 2018; 164(2017):S103-S105.
- [2] Bayer G, Von Tokarski F, Thoreau B, et al. "Etiology and outcomes of thrombotic microangiopathies." *Clin J Am Soc Nephrol.* 2019; 14(4): 557-566.
- [3] Merchant SH, Amin MB, Tamboli P, et al. "Primary signet-ring cell carcinoma of lung: Immunohistochemical study and comparison with non-pulmonary signet-ring cell carcinomas." *Am J Surg Pathol.* 2001; 25(12): 1515-1519.
- [4] Socola F, Loaiza-Bonilla A, Bustinza-Linares E, Correa R, Rosenblatt JD. "Recurrent Thrombotic Thrombocytopenic Purpura-Like Syndrome as a Paraneoplastic Phenomenon in Malignant Peritoneal Mesothelioma: A Case Report and Review of the Literature." *Case Rep Oncol Med.* 2012; 2012: 1-5.
- [5] Gainza E, Fernández S, Martínez D, et al. "Pulmonary tumor thrombotic microangiopathy: Report of 3 cases and review of the literature." *Med (United States).* 2014; 93(24): 359-363.
- [6] Shih HM, Lin CC, Shiao YW. "Pulmonary tumor thrombotic microangiopathy." *Am J Emerg Med.* 2011; 29(2): 241. e3-241.e4.
- [7] Dorothea H, Erxleben C. "Pulmonale tumorthrombotische Mikroangiopathie bei einer Patientin mit metastasierendem Magenkarzinom Pulmonary Tumor Thrombotic Microangiopathy in a Patient with Metastatic Gastric Cancer" Einleitung Therapie und Verlauf Anamnese Befunde und Untersuchungen. *DMW - Dtsch Medizinische Wochenschrift.* Published online 2018.
- [8] Morita S, Kamimura K, Abe H, et al. "Pulmonary tumor thrombotic microangiopathy of hepatocellular carcinoma: A case report and review of literature." *World J Gastroenterol.* 2019; 25(48): 6949-6958.
- [9] Katayama S, Takenaka T, Nakamura A, Sako S, Bessho A, Ohara N. "Pulmonary tumor thrombotic microangiopathy induced by prostate cancer." *Acta Med Okayama.* 2018; 72(3): 309-313.
- [10] Imakura T, Tezuka T, Inayama M, et al. "A long-term survival case of pulmonary tumor thrombotic microangiopathy due to gastric cancer confirmed by the early diagnosis based on a transbronchial lung biopsy." *Intern Med.* 2020; 59(13): 1621-1627.
- [11] Eisa N, Nasef K, Emarah Z, Fattah MMA, Shamaa S. "A Metastatic Signet Ring Cell Carcinoma Presented as Acquired Thrombotic Thrombocytopenic Purpura: A Case Report". *J Hematol.* 2018;7(2): 72-75.
- [12] Malkan UY, Albayrak M, Ozturk HB, Reis Aras M, Saglam B, Dogan K. "A Signet Ring Cell Carcinoma Presented as Refractory Acquired Thrombotic Thrombocytopenic Purpura. *Case Rep Oncol.*" Published online 2020: 1368-1372.
- [13] Otrock ZK, Taher AT, Makarem JA, Kattar MM, Nsouli G, Shamseddine AL. "Thrombotic thrombocytopenic purpura and bone marrow necrosis associated with disseminated gastric cancer." *Dig Dis Sci.* 2007; 52(6): 1589-1591.



© The Author(s) 2022. This article is an open access article distributed under the terms and conditions of the Creative Commons Attribution (CC BY) license (<http://creativecommons.org/licenses/by/4.0/>).