

# Hiatal Hernia Masquerading as a Left Atrial Mass: Case Report of a Multidisciplinary Imaging Findings

Hamlet Monteagudo, Sahar S. Abdelmoneim\*, Manuel Gonzalez Cruz, Abelardo Broceta Martinez,  
Milenis Lopez Leon, Madeleidis Lopez Leon, Sandy Espinosa Hernandez, Odalys Frontela

Division of Internal Medicine, Larkin Palm Spring Community Hospital, 1475 W 49th Pl, Hialeah, FL 33012

\*Corresponding author: [abdelmoneim.ss@gmail.com](mailto:abdelmoneim.ss@gmail.com)

Received September 05, 2022; Revised October 07, 2022; Accepted October 16, 2022

**Abstract** This case highlights the importance of maintaining a high index of suspicion of hiatal hernia (HH) as an uncommon etiology presenting with a wide range of symptomatology as well as a masquerading left atrial mass. Further assessments with multidisciplinary imaging modalities illustrated the gastrointestinal pathology of HH.

**Keywords:** *Hiatal Hernia masquerading as a Left atrial mass, Hiatal Hernia multidisciplinary imaging*

**Cite This Article:** Hamlet Monteagudo, Sahar S. Abdelmoneim, Manuel Gonzalez Cruz, Abelardo Broceta Martinez, Milenis Lopez Leon, Madeleidis Lopez Leon, Sandy Espinosa Hernandez, and Odalys Frontela, "Hiatal Hernia Masquerading as a Left Atrial Mass: Case Report of a Multidisciplinary Imaging Findings." *American Journal of Medical Case Reports*, vol. 10, no. 10 (2022): 256-260. doi: 10.12691/ajmcr-10-10-2.

## 1. Introduction

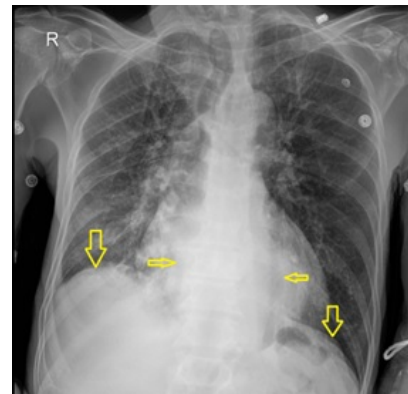
Hiatal hernia (HH) occurs when a displacement of the gastroesophageal junction (GEJ) and part of the stomach enters the mediastinum through the opening in the diaphragm. The most common type of HH is Type I (sliding type), representing more than 95% occurring when the GEJ is displaced upwards towards the hiatus. Other Types of HH includes: paraoesophageal HH (Type II HH) in which part of the stomach migrates into the mediastinum parallel to the esophagus, Type III occurs when both a paraoesophageal hernia and a sliding hernia coexist and Type IV when the stomach, parts of the bowel also herniate into the chest [1]. Symptomatology can range from non-specific symptoms, including heartburn, regurgitation or epigastric pain, intractable vomiting, ulcerating lesions [2,3] that leads to chronic blood loss to more serious conditions such as cardiac compression, arrhythmias and masquerading left atrial mass. Hence, HH should be included in the differential diagnosis of posterior mediastinal mass. HH can be incidentally noted on radiographic studies. On echocardiography, HH can be overlooked or misdiagnosed as a cardiac mass [4]. Computed tomography (CT) is the imaging modality to illustrate the cross-sectional anatomic localization of HH. In patients presenting with gastroesophageal reflux (GERD), an upper endoscopy and or barium swallow will be the choice of imaging [5]. We herein highlight the different multidisciplinary imaging findings of a Type III HH that is also masquerade as a left atrial mass. The patient presented in this case report gave informed consent and is aware that there are no patient-identifying details in the text or images submitted.

## 2. Case Report

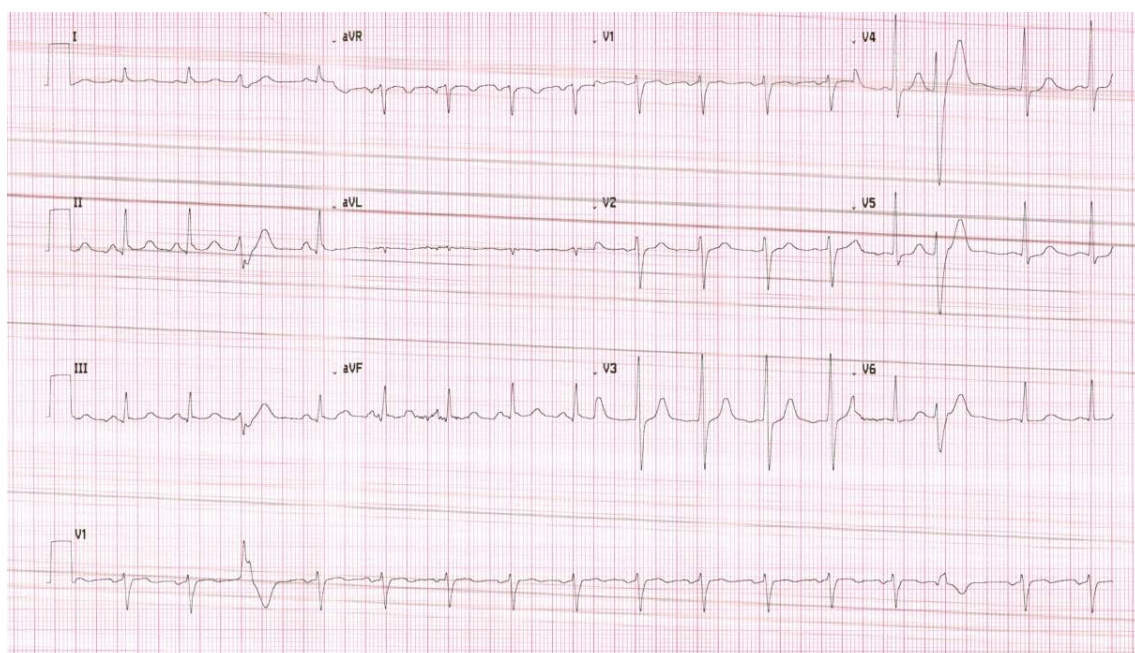
A 63-year-old homeless male, with a past medical history of smoking and substance abuse was found by emergency medical staff and brought to the Emergency Department because of intractable vomiting and abdominal pain. Pain is in the epigastrium, sharp with intensity 8/10 radiating to the back and accompanied with intractable vomiting of ingested food mixed up with dark colored blood, heartburn and shortness of breath. The patient denied any diarrhea, constipation, chest pain, or odynophagia. He could not recall any history of melena, hematochezia, fevers, chills, weight loss, or recent non-steroidal anti-inflammatory (NSAIDs) use. Family history of gastrointestinal malignancy is unknown. On physical examination, BMI was 24.5 Kg/m<sup>2</sup> his blood pressure was 135/90 mmHg, heart rate 80 /minutes regular rhythm, Temp 98 F, O<sub>2</sub> saturations 99% on room air. Patients appeared pale, cachectic, and lethargic. Pulmonary and cardiac examination was unremarkable apart from scarce rales bilaterally over lung bases and bowel sounds that were heard in the thoracic cavity. Abdominal examination revealed upper abdominal tenderness, minimal distention, and normal bowel sounds in all 4 abdominal quadrants without guarding or rebound tenderness. Rectal exam was unremarkable. Chest Xray (Figure 1) revealed normal cardio mediastinal silhouette, However, a retrocardiac opacity was visualized along with small volume right-sided pleural effusion with overlying atelectasis and/or pneumonia. Initial ECG (Figure 2) showed normal sinus rhythm with one premature ventricular ectopic beat. Laboratory workup on admission revealed a white cell count of  $9.5 \times 10^3/uL$ ; hemoglobin 7.3 g/dL; Hematocrit

24.3, MCV 86, platelets  $524 \times 10^3/uL$  (normal range 130-360  $\times 10^3/uL$ ); urea 23 mg/dL (normal range 15-45 mg/dL); creatinine 1.16 mg/dL (normal range 0.6-1.1 mg/dL); BUN/creatinine ratio 23; sodium 143 mmol/L (normal range 135-145 mmol/L); potassium 3.3 mmol/L (normal range 3.5-5.0 mmol/L). Coagulation profile, liver function test, lipase and amylase, cardiac Troponin-I, high sensitivity CRP, lactic acid and procalcitonin were within normal limits. Arterial blood gasses on admission showed pH 7.34, pCO<sub>2</sub> 52, pO<sub>2</sub> 68, and the patient had positive FOBT. Iron profile was significant for low iron levels (16, normal ranges 59-158 ug/dL), low iron saturation (6.2%; normal ranges 11-46%), normal TIBC (259, normal ranges 240-450 ug/dL), normal transferrin (207, normal ranges 163-344 mg/dL), and Ferritin of 33. Vitamin B12 and Folate levels were normal. The patient was admitted to the intensive care unit and was stabilized with intravenous hydration, transfused 2 units of packed red blood cells (PRBC), pantoprazole 40 mg, Ondansetron 4 mg, Potassium 10 mEqL. Patients' mild hypoxia were attributed to aspiration pneumonia secondary to the intractable vomiting. Additionally, the patient was started on Ceftriaxone and metronidazole empirically. Abdominal ultrasound was unremarkable except for intrahepatic biliary duct dilatation. The patient underwent transthoracic echocardiogram (TTE) utilizing all standard and modified apical and parasternal views, revealing an amorphous, echo lucent space-occupying mass on the posterior and inferior aspect of the left atrium (Figure 3). Ventricular size and function were normal and with no signs of structural or functional abnormalities of the left or the right ventricle, with normal left ventricular ejection fraction (LVEF= 57%). No pericardial effusion was present. The patient subsequently underwent a chest and Abdomen computed tomography (CT) scan. On CT images, the heart appeared normal in size and no pericardial effusion was noted. The thoracic aorta and main pulmonary arteries were normal size. A moderate to large HH was visualized

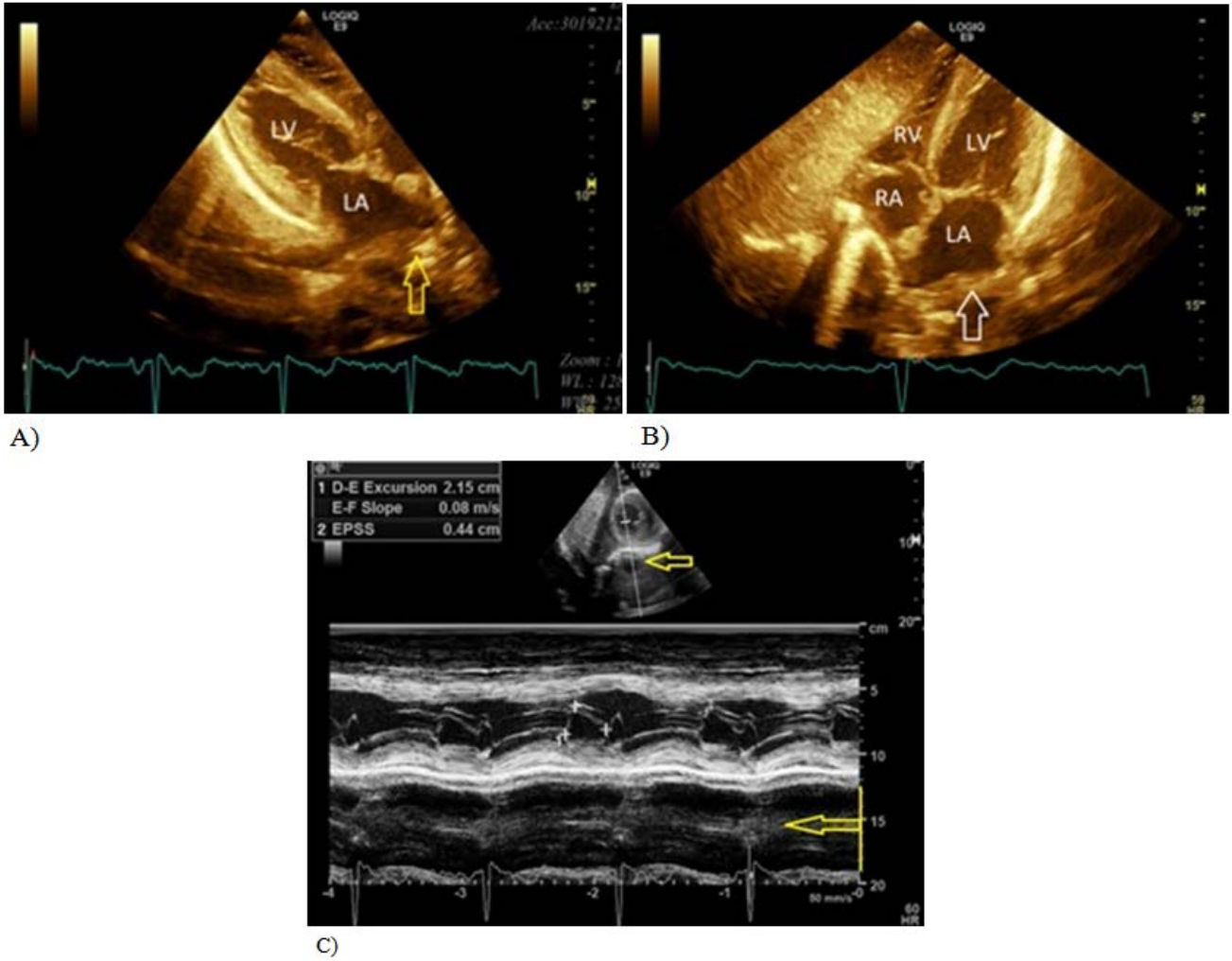
in the posterior mediastinum, compressing the heart, especially on the left atrium (Figure 4). The intrathoracic migration of a large part of the stomach was further confirmed by an upper gastrointestinal barium examination to further assess the extent of the hernia and evaluate esophageal transient time (Figure 5). Additional Gastroenterology workup included Multiplanar and multi sequence Magnetic resonance cholangiopancreatography (MRCP) without the administration of intravenous contrast showing no intrahepatic or extrahepatic biliary ductal dilatation, unremarkable findings except for large mixed type HH (Figure 6). To evaluate the cause of anemia and source of bleeding, the patient underwent Esophagogastroduodenoscopy (EGD). EGD showed severe esophagitis, large HH (~7-8 cm), and Paraesophageal cavity/diverticulum with necrotic ulcer with adherent clot and surrounding area of friability, with histopathological examination of biopsy specimen demonstrating ulcerative tissue. The patient was referred for surgery consult for HH repair; however, he refused surgical intervention. He was discharged on Pantoprazole 40 mg daily and was instructed to follow up in the outpatient clinic every 3 months.



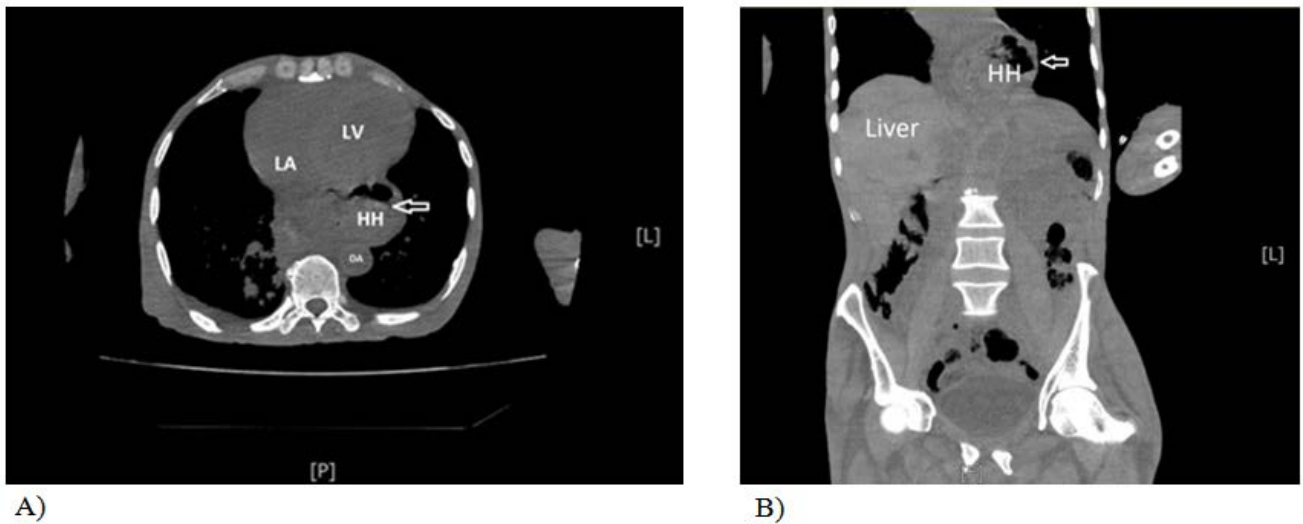
**Figure 1.** Chest X-ray: showing a retrocardiac mass with a limited air-filled level (arrows). Vertical arrows highlight the diaphragm



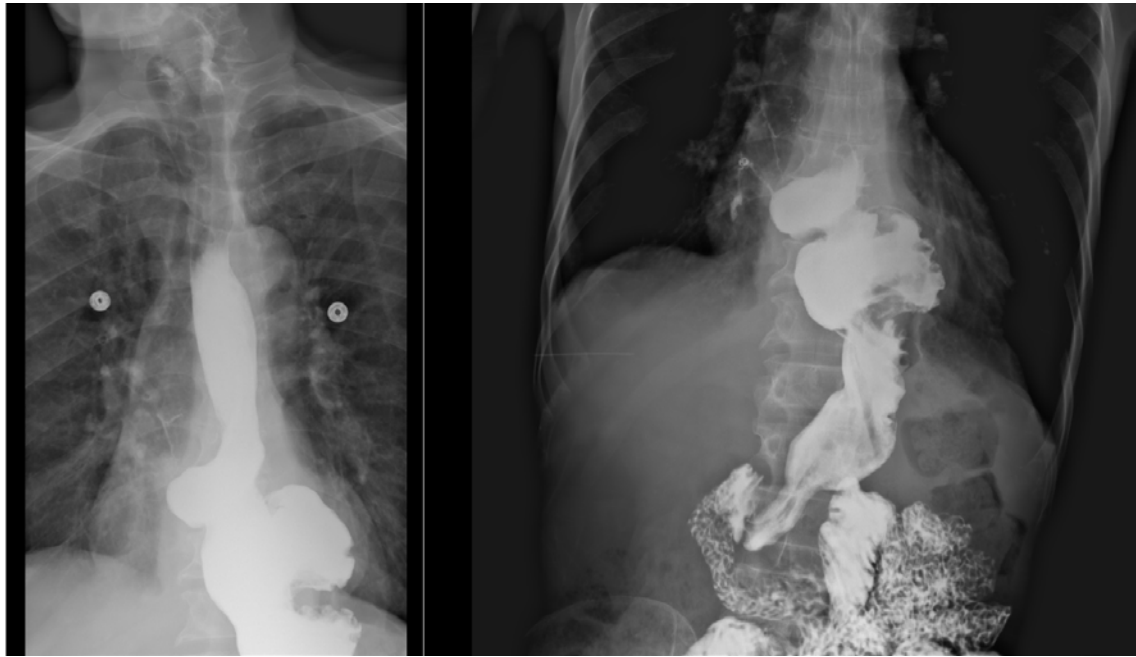**Figure 2.** Electrocardiogram (ECG) showing normal sinus rhythm. Premature ventricular contraction beat is noted.



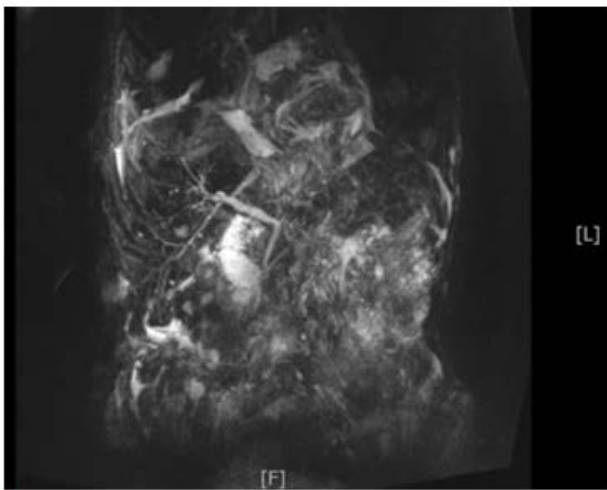
**Figure 3.** Two-dimensional transthoracic echocardiography image. **A)** parasternal long axis view showing left atrial compression by a mass (yellow arrow); **B)** Four-chamber apical view indicative of mass in the left atrium (white arrow); **C)** M mode image at the midventricular level showing the mass in the posterior wall of the LV (yellow arrow).



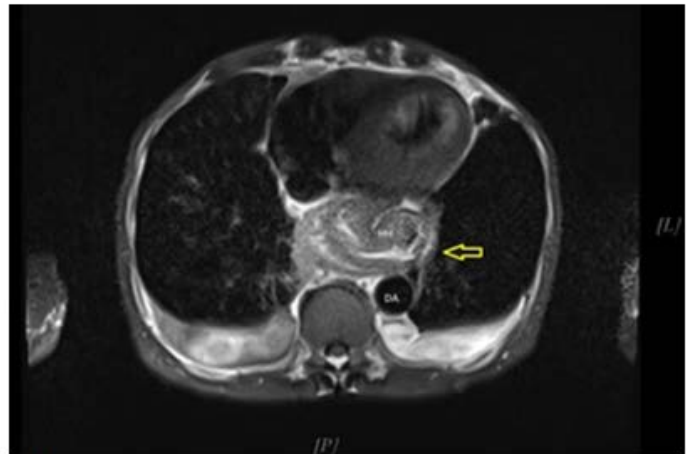
**Figure 4.** Computed tomography (CT) of the chest without contrast **A)** Chest CT showing transverse plane image showing a large hiatal hernia compressing the heart, especially on the left atrium **B)** Coronal CT of chest and abdomen showing the large hiatal hernia located above the diaphragm



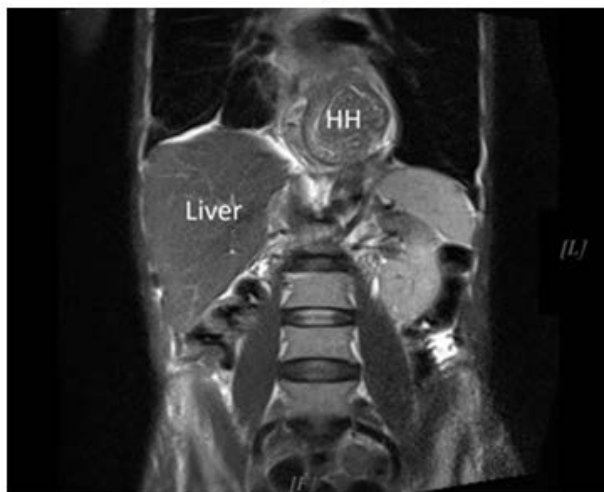
**Figure 5.** Two projections (left and right) of a barium esophagogram illustrating intrathoracic herniation of the gastroesophageal junction with the gastric fundus, consistent with type III or mixed paraesophageal hiatal hernia. Contrast is visualized in the duodenum



A)



B)



C)

**Figure 6.** Magnetic resonance cholangiopancreatography (MRCP) demonstrating A) normal biliary ducts dilated and B) and C) images illustrating intrathoracic herniation of the gastroesophageal junction with the gastric fundus, consistent with type III or mixed paraesophageal hiatal hernia

### 3. Discussion

In this case report we highlighted multidisciplinary imaging modalities for evaluating Hiatal hernia (HH). While the majority of HH are asymptomatic, other types may be presenting as a great mimicker of the range of symptoms that resemble many disorders involving the cardiopulmonary or gastrointestinal systems. Our patient presented with intractable vomiting, abdominal pain, and shortness of breath. Gastroesophageal reflux has been shown to occur frequently with HH as was shown in a recent published Multi-Ethnic Study of Atherosclerosis (MESA) study [5]. On Xray, HH can be discovered incidentally as a retrocardiac gas-filled structure, and is considered one of the differential diagnoses of a posterior mediastinal mass. Such mass can end up compressing the posterior aspects of the heart (mostly left atrium), and on echocardiography it can be presented as a masquerading left atrial mass. Compression symptomatology can include chest discomfort, shortness of breath, arrhythmias, syncope or mimic ischemic heart syndromes [6]. Indeed, a case series of patients with significant left atrial compression by gastric structures presenting with hemodynamic instability and respiratory failure has been reported [6]. In our case, a posterior mediastinal mass encroaching on the left atrium was suspected. However, we were limited by the lack of use of echocardiographic contrast to exclude a communication between the heart chambers and the mass or utilizing an ingestion of a carbonated beverage while imaging to differentiate extracardiac from intracardiac mass [7]. Upper GI barium series is also useful in the investigation of suggested hiatal hernia and its sequelae [1], while CT scans are useful when accurate anatomic depiction and more precise cross-sectional localization is desired. On CT, HH appears as a retrocardiac mass with or without an air-fluid level, which can be traced into the diaphragmatic esophageal hiatus on sequential cuts. The type of HH in our case was diagnosed as Type III (mixed) in which GEJ is displaced into the thorax with a large portion of the stomach, which is a predisposing factor for more complications including volvulus, ischemia, or obstruction. In rare cases, massive hiatal hernia of the pancreatic body and tail and the presentation of acute pancreatitis and bile duct dilatation have been reported [8]. In our case, abdominal ultrasound revealed biliary dilatation, however on further MRCP workup, this was not demonstrated. Our patient presented with intractable vomiting and anemia due to chronic blood loss. On EGD, a HH ulcer was found. HH ulcers account for 10% of all benign gastric ulcers. It is also reported that

Acute hemorrhage from HH was reported to occur with NSAID use. Treatment guidelines are directed toward treating the symptoms of GERD; however, surgical management [9] is indicated if complications develop as seen in the patient. Unfortunately, the patient refused the surgical option adopted for the use of medical treatment and regular follow up.

### Acknowledgements

We would like to express our gratitude for the Department of Research and Academic Affairs and Dr Rishabh Dua in Larkin Health System for their assistance with this research work.

### References

- [1] Abdelmoaty W, Dunst C, Fletcher R, Doan H, Tugulan C, Walters J, Davila-Bradley D, Reavis K, Swanson L, DeMeester S. The Development and Natural History of Hiatal Hernias: A Study Using Sequential Barium Upper Gastrointestinal Series. *Ann Surg.* 2022 Mar 1; 275(3): 534-538.
- [2] Boyd EJ, Penston JG, Russell RI, and Wormsley KG. Hiatal hernia ulcers: clinical features and follow-up. *Postgrad Med J.* 1991 Oct; 67(792): 900-903.
- [3] Gupta P, Madhu Suryadevara M, Das A, and Falterman J. Cameron Ulcer Causing Severe Anemia in a Patient with Diaphragmatic Hernia. *Am J Case Rep.* 2015; 16: 733-736. Published online 2015 Oct 15.
- [4] Kim SH, Kim MG, Kim SJ, et al. Unusual Diaphragmatic Hernias Mimicking Cardiac Masses. *J Cardiovasc Ultrasound.* 2015; 23(2): 107-112.
- [5] Kim J, Hiura GT, Oelsner EC, Yin X, Barr RG, Smith BM, Prince MR. Hiatal hernia prevalence and natural history on non-contrast CT in the Multi-Ethnic Study of Atherosclerosis (MESA). *BMJ Open Gastroenterol.* 2021; 8(1): e000565. Published online 2021 Mar 17.
- [6] Raza ST, Mukherjee SK, Danias PG, Abraham J, Johnson KM, Sands MJ Jr, Werner MS, Silverman DI: Hemodynamically significant extrinsic left atrial compression by gastric structures in the mediastinum. *Ann Intern Med* 1995; 123: 114-116.
- [7] Smelley M, Lang RM, et al. Diagnostic Value of a new cocktail, Chicago, Illinois, Section of Cardiology, Department of Internal Medicine, University of Chicago Hospitals, Chicago, Illinois. *American Society of Echocardiography*, 2007; 20: 1414.e5-1414.e7.
- [8] Tomida H, Hayashi M, and Hashimoto S. Massive hiatal hernia involving prolapse of the entire stomach and pancreas resulting in pancreatitis and bile duct dilatation: a case report. *Surg Case Rep.* 2020 Dec; 6: 11. Published online 2020 Jan 9.
- [9] DeMeester SR. Laparoscopic Hiatal Hernia Repair and Fundoplication for Gastroesophageal Reflux Disease. *Gastrointest Endosc Clin N Am.* 2020 Apr; 30(2): 309-324.

