

Rapidly Enlarging Diffuse Large B-Cell Lymphoma Presenting 20 Years after Hodgkin's Lymphoma: A Case Report

Madison Drallmeier^{1,*}, Katherine King¹, Richard C. Spinale²

¹Michigan State University College of Osteopathic Medicine, East Lansing, MI, USA

²Department of General Surgery, Garden City Hospital, Garden City MI, USA

*Corresponding author: drallmei@msu.edu

Received September 05, 2022; Revised October 07, 2022; Accepted October 16, 2022

Abstract Diffuse large B-cell lymphoma (DLBCL) is the most common non-Hodgkin lymphoma diagnosed in the United States. DLBCL often presents with constitutional symptoms, lymphadenopathy, and mass. Here we report a case of asymptomatic DLBCL with a rapidly enlarging mass as the presenting symptom. Given the patient's history of Hodgkin lymphoma, his DLBCL is likely a secondary malignancy resulting from previous chemotherapy and radiation.

Keywords: Hodgkin lymphoma, diffuse large B-cell lymphoma, secondary malignancy

Cite This Article: Madison Drallmeier, Katherine King, and Richard C. Spinale, "Rapidly Enlarging Diffuse Large B-Cell Lymphoma Presenting 20 Years after Hodgkin's Lymphoma: A Case Report." *American Journal of Medical Case Reports*, vol. 10, no. 10 (2022): 253-255. doi: 10.12691/ajmcr-10-10-1.

1. Introduction

Diffuse large B-cell lymphoma (DLBCL) is the most diagnosed non-Hodgkin lymphoma (NHL) in the United States, affecting 5.6 per 100,000 individuals each year [1]. As an aggressive form of cancer, patients often present with constitutional symptoms (fever, weight loss, night sweats) and a mass in nodal or extra-nodal sites. DLBCL is a heterogeneous disease with diverse cell morphology, molecular backgrounds, clinical response to therapy, and overall patient outcome. Despite advances in research and treatment, approximately 40% of patients will experience relapsed or refractory disease and poor survival.

2. Case Report

A 57-year-old African American male with a past medical history of Hodgkin lymphoma (HL) and diabetes mellitus presented to the general surgeon with complaints of a growing abdominal mass. The abdominal mass was incidentally found by his primary physician on a routine chest computed tomography (CT), which revealed a partially visible large mass within the right middle to lower abdomen, possibly originating in the cecum. Repeat CT scan of the abdomen and pelvis demonstrated an expansive tumor encompassing the right colon and cecum without obstruction of the small bowel, as well as right sided hydronephrosis from compression on the ureter (e.g. Figure 1).

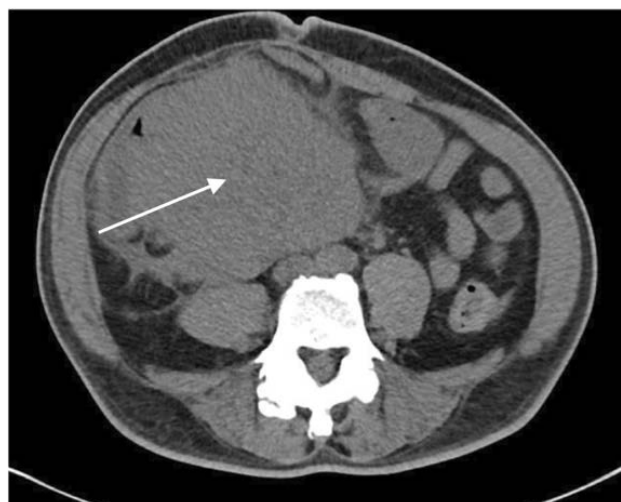

Figure 1. Large mass extending throughout the lower abdomen and pelvis measuring 19cmx17cm. Engulfing the right colon and cecum without evidence of small bowel obstruction

The patient stated that he became aware of the mass approximately 3 weeks prior to presenting to the hospital. He also admitted to a 15-pound weight loss, which he attributed to a change in diet, as well as mild discomfort in the abdomen. The patient denied experiencing any B-symptoms, including fever, fatigue, lymphadenopathy, or night sweats. He also denied nausea, vomiting, constipation, or diarrhea. Physical exam revealed a large, fixed mass approximately 15 cm in diameter in the right lower abdomen. The mass was firm to palpation and caused slight protrusion of the abdominal wall, resulting

in mild asymmetry. The differential diagnosis included sarcoma, carcinoma, recurrence of HL, and NHL.

The patient subsequently underwent colonoscopy to locate and biopsy the mass. However, the colonoscope was unable to be advanced past the sigmoid colon due to extrinsic compression of the colon by the tumor. The patient was then sent for CT-guided biopsy of the mass. Pathology demonstrated nests of atypical lymphoid-like cells within dense stroma with occasional clusters of apoptotic degeneration of tumor cells (e.g. [Figure 2](#)). Immunohistochemistry (IHC) revealed positivity for cluster of differentiation (CD) 45, CD20, CD79a, CD10, PAX-5, BCL-6, BCL-2 (weak). Proliferative marker Ki-67 was present in approximately 90% of lymphocytes, indicating rapid replication. Fluorescence in-situ hybridization (FISH) of the mass biopsy was negative for *MYC* gene rearrangements. Bone marrow biopsy showed normocellular marrow without evidence of neoplastic infiltration. FISH and flow cytometry of the bone marrow showed no chromosomal or immunophenotypic abnormalities. Together, these results ultimately confirmed a diagnosis of diffuse large B cell lymphoma (DLBCL) with a germinal center subtype.

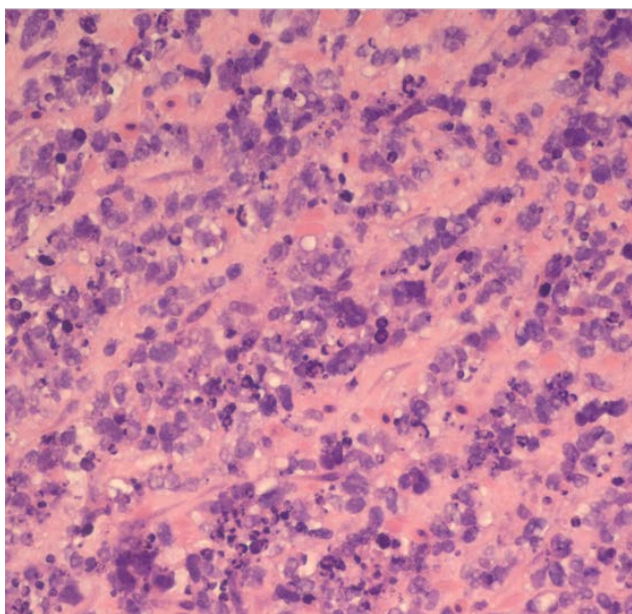


Figure 2. Low-power image showing diffuse infiltration of B-cells within soft tissue (hematoxylin-eosin)

3. Discussion

In 2008, the World Health Organization (WHO) designated 3 main subtypes of DLBCL according to the cell of origin: germinal center B-cell-like (GCB), activated B-cell-like (ABC), and unclassifiable [2]. These subtypes differ primarily in their gene expression profiles, signaling pathways, and response to treatment. Determination of DLBCL subtype may have prognostic value, as shown in one study in which patients with the GCB subtype had a higher 5-year progression-free survival and overall survival after therapy as compared to the ABC and unspecified subtypes [3]. In 2016, the WHO updated its guidelines recommending that the cell of origin classification should be included in the pathology report

[2,4]. While DNA microarrays and sequencing methods are used to obtain the genetic profile of a patient sample, these technologies are expensive and not readily available in the hospital setting. Therefore, algorithms utilizing IHC results were developed to predict cell of origin while maintaining prognostic significance. One of the most used algorithms in clinical practice, the Hans Classification, utilizes the expression pattern of CD10, BCL-6, and MUM1 to accurately designate the subtype [5,6]. When applying the Hans algorithm to our case, the presence of CD10 positivity despite the presence or absence of either BCL-6 or MUM1 indicates a GCB subtype (e.g. [Figure 3](#)).

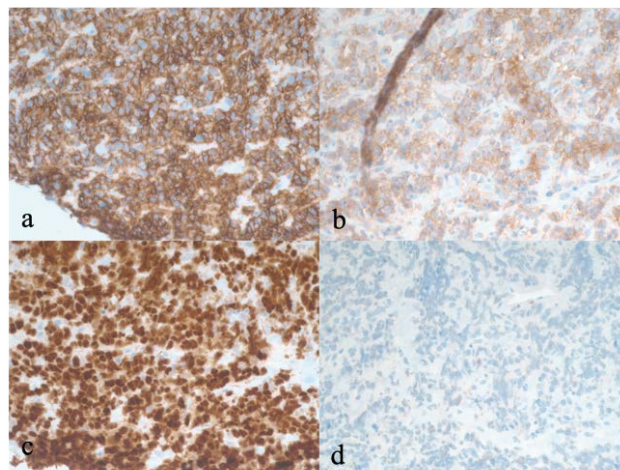


Figure 3. Immunohistochemical staining of the patient's biopsy indicating a germinal center B-cell-like subtype. a) CD20 positive, indicates B-cell lineage. b) CD10 positive c) bcl-6 positive d) negative MUM1

Molecular studies are also important in the workup of DLBCL as there are several associated chromosomal aberrations. Specifically, alterations of the proto-oncogene *MYC* are present in 5-15% cases patients with DLBCL and are associated with poor clinical outcomes [2,4]. In some cases, *MYC* may be rearranged with *BCL2*, *BCL6*, or all three may occur. This is termed as “double-hit” or “triple-hit” disease, respectively [6]. Per the 2016 WHO guidelines, these rearrangements have been categorized as “high-grade B-cell lymphomas [2].” Fortunately for our patient, FISH studies of both tumor biopsy and bone marrow biopsy demonstrated no chromosomal rearrangements.

Standard treatment for DLBCL consists of a combination of five drugs, which include rituximab, cyclophosphamide, doxorubicin, vincristine, and prednisone (R-CHOP). While this treatment can be curative for many patients, some patients with more advanced staged disease or those with specific genetic predisposition (i.e., *MYC* gene rearrangements) will fail treatment. Development of new drug strategies are underway to target those who do not respond to traditional R-CHOP therapy. One novel strategy that utilizes dose-adjusted etoposide, prednisone, vincristine, cyclophosphamide, doxorubicin, and rituximab (DA-EPOCH-R) has shown promising results in phase II trials, irrespective of the cell of origin [7,8]. However, phase III trials demonstrated no improvement in progression-free survival, overall survival, or response rate of DA-EPOCH-R over standard R-CHOP [9]. Additionally, DA-EPOCH-R was associated with increased toxicity and resulted in severe side effects. Several other treatment strategies are

currently under investigation for non-GCB subtypes and double-hit DLBCL, which have generally shown poor response to R-CHOP [7]. In the setting of our patient, R-CHOP therapy was initiated given his more favorable GCB subtype and lack of clinically significant genetic rearrangements.

4. Conclusion

In this case, we found the size of the solitary tumor, which spread from mid abdomen through the lower pelvis, to be quite remarkable given the patient had no presenting complaints besides mild weight loss. Imaging revealed that the tumor encompassed the cecum and right colon without resulting in bowel obstruction. It also compressed the right ureter, leading to right-sided hydronephrosis. Case reports of NHL arising in the abdomen described more severe obstructive symptoms, such as abdominal pain and vomiting from bowel obstruction or post-prandial bilious vomiting due to duodenal compression [10,11]. In addition to the unique presentation, we believe this case illustrates the importance of long-term surveillance in HL survivors. The patient admitted to a history of HL approximately 20 years ago, for which he received both chemotherapy and radiation to the chest. It is well established that the risk of developing NHL after achieving HL remission is elevated [12]. However, new cohort studies have quantified this risk. Swerdlow et al. demonstrated that HL survivors previously treated with chemotherapy and radiation have a standardized incidence ratio (SIR) of 17.1 and absolute excess risk per 10,000 person-years (AER) of 13.9 of developing NHL later in life compared to the general population [13]. Another study by Schaapveld et al. had similar findings, with a SIR of 13.4 and AER of 16.0, as well as a 30-year post-therapy cumulative incidence of NHL to be 3.7 times more likely than the general population [14]. Both studies show that risk of secondary cancer development, such as NHL, is increased in HL survivors and can remain elevated for up to 20 years following treatment, as is the case for our patient.

References

[1] SEER Cancer Stat Facts: Diffuse Large B-Cell Lymphoma. National Cancer Institute. Bethesda, MD, <https://seer.cancer.gov/statfacts/html/dlbcl.html>.

[2] Swerdlow SH, Campo E, Pileri SA, Harris NL, Stein H, Siebert R, Swerdlow S.H., Campo E., Pileri S.A., Harris N.L., Stein H., Siebert R., Advani R., Ghielmini M., Salles G.A., Zelenetz A.D., Jaffe E.S., "The 2016 revision of the World Health Organization classification of lymphoid neoplasms," *Blood*, 127 (20). 2375-90. May 2016.

[3] Scott D.W., Mottok A., Ennishi D., Wright G.W., Farinha P., Ben-Neriah S., Kridel R., Barry G.S., Hother C., Abrisqueta P., Boyle M., Meissner B., Telenius A., Savage K.J., Sehn L.H., Slack G.W., Steidl C., Staudt L.M., Connors J.M., Rimsza L.M., Gascoyne R.D., "Prognostic Significance of Diffuse Large B-Cell Lymphoma Cell of Origin Determined by Digital Gene Expression in Formalin-Fixed Paraffin-Embedded Tissue Biopsies," *J Clin Oncol*, 33 (26), 2848-56. Sep 2015

[4] Li S., Young K.H., Medeiros L.J., "Diffuse large B-cell lymphoma," *Pathology*, 50 (1), 74-87. Jan 2018.

[5] Hans C.P., Weisenburger D.D., Greiner T.C., Gascoyne R.D., Delabie J., Ott G., Müller-Hermelink H.K., Campo E., Braziel R.M., Jaffe E.S., Pan Z., Farinha P., Smith L.M., Falini B., Banham A.H., Rosenwald A., Staudt L.M., Connors J.M., Armitage J.O., Chan W.C., "Confirmation of the molecular classification of diffuse large B-cell lymphoma by immunohistochemistry using a tissue microarray," *Blood*, 103 (1), 275-82. Jan 2004.

[6] Nguyen L., Papenhausen P., Shao H., "The Role of c-MYC in B-Cell Lymphomas: Diagnostic and Molecular Aspects.," *Genes (Basel)*, 8 (4), 116. Apr 2017.

[7] Mondello P., Mian M., "Frontline treatment of diffuse large B-cell lymphoma: Beyond R-CHOP," *Hematol Oncol*, 37 (4), 333-344. Oct 2019.

[8] Wilson W.H., Dunleavy K., Pittaluga S., Hegde U., Grant N., Steinberg S.M., Raffeld M., Gutierrez M., Chabner B.A., Staudt L., Jaffe E.S., Janik J.E., "Phase II study of dose-adjusted EPOCH and rituximab in untreated diffuse large B-cell lymphoma with analysis of germinal center and post-germinal center biomarkers," *J Clin Oncol*, 26 (16), 2717-24. Jun 2008.

[9] Bartlett N.L., Wilson W.H., Jung S.H., Hsi E.D., Maurer M.J., Pederson L.D., Polley M.C., Pitcher B.N., Cheson B.D., Kahl B.S., Friedberg J.W., Staudt L.M., Wagner-Johnston N.D., Blum K.A., Abramson J.S., Reddy N.M., Winter J.N., Chang J.E., Gopal A.K., Chadburn A., Mathew S., Fisher R.I., Richards K.L., Schöder H., Zelenetz A.D., Leonard J.P., "Dose-Adjusted EPOCH-R Compared With R-CHOP as Frontline Therapy for Diffuse Large B-Cell Lymphoma: Clinical Outcomes of the Phase III Intergroup Trial Alliance/CALGB 5030," *J Clin Oncol*, 37 (21), 1790-1799. Jul 2019.

[10] Negrea V., Graur F., Moiş E., Al-Hajjar N., "Ileocecal Obstruction Due to B-cell Non-Hodgkin Lymphoma," *Chirurgia*, 111 (1), 71-3. 1990.

[11] Ravindran B., Prakash C., Govindharaj S., Bahnou N.M.S., Pavithra B., "An Aggressive Primary Retroperitoneal Diffuse Large B-Cell Lymphoma Mimicking a Pancreatic Neoplasm, Presenting as Duodenal Stenosis," *J Clin Diagn Res*, 11 (9), 9-11. Sep 2017.

[12] Krikorian J.G., Burke J.S., Rosenberg S.A., Kaplan H.S., "Occurrence of non-Hodgkin's lymphoma after therapy for Hodgkin's disease," *N Engl J Med*, 300 (9), 452-8. Mar 1979.

[13] Swerdlow A.J., Higgins C.D., Smith P., Cunningham D., Hancock B.W., Horwich A., Hoskin P.J., Lister T.A., Radford J.A., Rohatiner A.Z., Linch D.C., "Second cancer risk after chemotherapy for Hodgkin's lymphoma: a collaborative British cohort study," *J Clin Oncol*, 29 (31), 4096-104. Nov 2011.

[14] Schaapveld M., Aleman B.M., van Eggermond A.M., Janus C.P., Krol A.D., van der Maazen R.W., Roesink J., Raemaekers J.M., de Boer J.P., Zijlstra J.M., van Imhoff G.W., Petersen E.J., Poortmans PM, Beijert M, Lybeert ML, Mulder I, Visser O, Louwman MW, Krul IM, Lugtenburg P.J., van Leeuwen F.E., "Second Cancer Risk Up to 40 Years after Treatment for Hodgkin's Lymphoma," *N Engl J Med*, 373 (26), 2499-511. Dec 2015.

